

**DATE PRESENTING CLINICAL SIGNS**

10/6/22 Chronically elevated liver values but pet needs surgery. Pet had IMT and is off of Prednisone as of 8/15/22. Liver values have been elevated since 2019. ALP>ALT.

PATIENT

Smokey Toth Current Medications: Gabapentin 100mg 2 BID for pain.
Lab Results: 5/19 ALT 163, ALP 261. 4/20 ALT 128, ALP 396. 6/21 ALT 150, ALP 532. 3/22 ALT 241, ALP 1029. 4/22 ALT 320, ALP 877. 6/22 ALT 307, ALP 872.

SPECIES

Canine Date of Previous IntraPet Ultrasound: No previous.
Sedation: Not required to complete full diagnostic ultrasound.
Stat Report: Not requested.

BREED

Pug

SEX

Neutered Male

AGE

8/28/12

WEIGHT

30 kg

INTERPRETED BY

Kathleen Sennello DVM,
MS, Diplomate ACVIM
(Small Animal Internal
Medicine)

IMAGING PERFORMED BY

Stephanie Warga
RDMS, RVT

HOSPITAL NAME

Banfield Columbia

REFERRING VET

Dr. Landon

INVOICE

41871

ULTRASONOGRAPHIC EXAMINATION OF THE ABDOMEN**Urinary System**

The urinary bladder is moderately distended with anechoic urine. The Bladder wall, trigone, ureteral papillae and visible urethra (to a depth of 2cm) appear normal with no evidence of wall thickening, mucosal irregularities, masses or cystic calculi.

The prostate is normal in size (1.5 cm) and shape for this neutered male dog. The parenchyma is homogenous and the external margins are smooth. The prostatic urethra appears normal with no evidence of irregularity, invasion, mass effect or calculi.

The left kidney has a normal shape and size (7.25 cm). Overall echogenicity is normal with adequate corticomedullary distinction and a typical 1:3 cortex:medulla ratio. There is no evidence of focal perinephric inflammation or effusion. There is no evidence of pyelectasia, nephroliths, infarcts or hydroureter. Renal vasculature is normal.

The right kidney has a normal shape and size (7.03 cm). Overall echogenicity is normal with adequate corticomedullary distinction and a typical 1:3 cortex:medulla ratio. There is no evidence of focal perinephric inflammation or effusion. There is no evidence of pyelectasia, nephroliths, infarcts or hydroureter. Renal vasculature is normal.

Adrenal Glands

The left adrenal gland is normal in size measuring 0.73 cm at the caudal pole. It is observed in its normal position cranial to the left renal artery. It is normal in appearance (uniformly hypoechoic) and shape with no evidence of a mass effect.

The right adrenal gland is normal in size measuring 0.62 cm at the caudal pole. It is observed in its normal position between the cranial aspect of the right kidney and the caudal vena cava. It is normal in appearance (uniformly hypoechoic) and shape with no evidence of a mass effect.

Spleen

The spleen is subjectively normal in size. The spleen echotexture is heterogenous and mottled, the splenic capsule is smooth with no irregularities. The blood flow through the hilus and splenic parenchyma appears normal. There is a hypoechoic mass effect in the cranial abdomen measuring 2.49 cm x 3.91 cm. Suspect splenic origin, but this is not definitive (see under other).

Liver

The liver is large in size, and normal in echogenicity with smooth peripheral margins. The parenchyma is heterogenous in echotexture with subtle, indistinct focal mottling. The visible portions of the vasculature and biliary tract appear normal. There is a cystic structure visualized within the parenchyma measuring 1.53 cm x 1.36 cm.

The gall bladder lumen is moderately distended. The wall of the gall bladder is not thickened and has a smooth mucosal surface. There is a moderate amount of non-organized echogenic debris. The cystic and common bile ducts are normal/not visible.

Gastrointestinal

The stomach contains minimal luminal contents. It measures at a normal thickness of <0.7cm with some variability due to the presence of rugal folds. The distinction of the gastric wall layers is adequate and there is no impression of reduced peristaltic activity. No masses or focal lesions were observed.

The visualized areas of duodenum, jejunum and ileum have a relatively uniform diameter with minimal fluid distension. Wall thickness is normal. Bowel loops follow a curvilinear path with distinct wall layering maintaining the typical 1:3 muscularis:mucosa layer ratio. Jejunum wall measures 0.36 cm. Visualized peristalsis appears appropriate. There were no focal lesions consistent with obstruction or a mass effect observed.

The ileocecal junction was visualized and exhibited normal intact wall layering and is subjectively of normal thickness. Sections of colon are visualized with formed fecal material and gas shadowing distally. There is no observed focal or generalized colon wall thickening or loss of layering.

Pancreas

The pancreas is prominent and mottled compared to the surrounding isoechoic mesentery. There is no evidence of nodules or cystic lesions. There is no evidence of regional mesenteric inflammation or fluid.

Free Abdomen

Evaluation of the peritoneal cavity did not reveal any evidence of effusion. There is a prominent iliac lymph node visualized measuring 0.73 cm. The omentum is of normal echogenicity.

Other

There is a hypoechoic solid mass effect visualized caudal to the liver and ventral to the stomach, measuring 3.49 cm x 3.91 cm. This appears to be of splenic origin, although a hepatic mass, lymph node, etc. cannot be completely excluded as a possibility.

ULTRASONOGRAPHIC FINDINGS

- Hypoechoic solid mass effect caudal to the liver in the cranial abdomen – This is most consistent with a hypoechoic splenic mass. Consider such differentials as neoplasia (hemangiosarcoma, hemangioma), hematoma, abscess, other. Alternately, this mass lesion could be of hepatic origin, an effaced lymph node, etc.
- Mottled spleen – The diffuse splenic changes are non-specific and could be consistent with lymphoid hyperplasia, extramedullary hematopoiesis, infiltrative neoplasia, inflammation, other. Cytology or histopathology would be necessary to get a definitive diagnosis.
- Large, heterogeneous liver with a cystic lesion – The diffuse hepatic changes are non-specific and could be consistent with vacuolar hepatopathy, nodular hyperplasia, inflammatory/immune-mediated disease, fibrosis, extramedullary hematopoiesis, toxic hepatopathy (e.g., copper), infiltrative neoplasia (less likely) or other hepatopathy. The cystic lesion is most consistent with a benign hepatic cyst.
- Moderate gallbladder debris – The significance of the aggregated gallbladder debris is unclear. This could represent an early mucocele, cholestasis, or may be secondary to fasting but seems unlikely to be causing a current issue. Recommend continued monitoring.

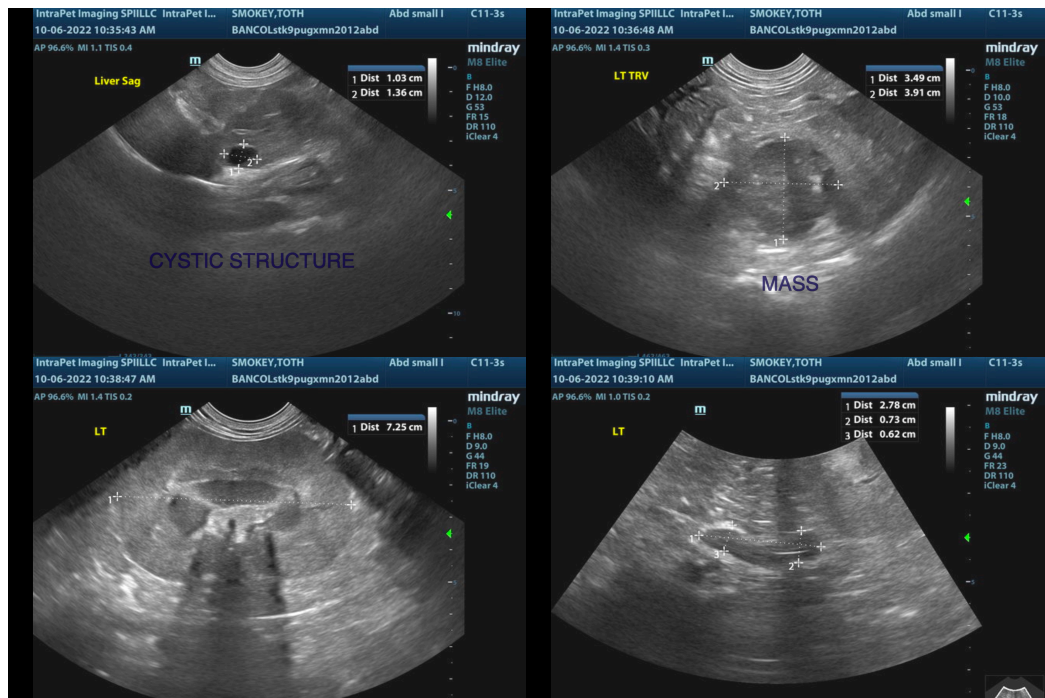
- Prominent iliac lymph node – The prominent abdominal lymph nodes are most consistent with reactive lymphadenitis or lymphoid hyperplasia. Neoplastic infiltration is considered less likely.

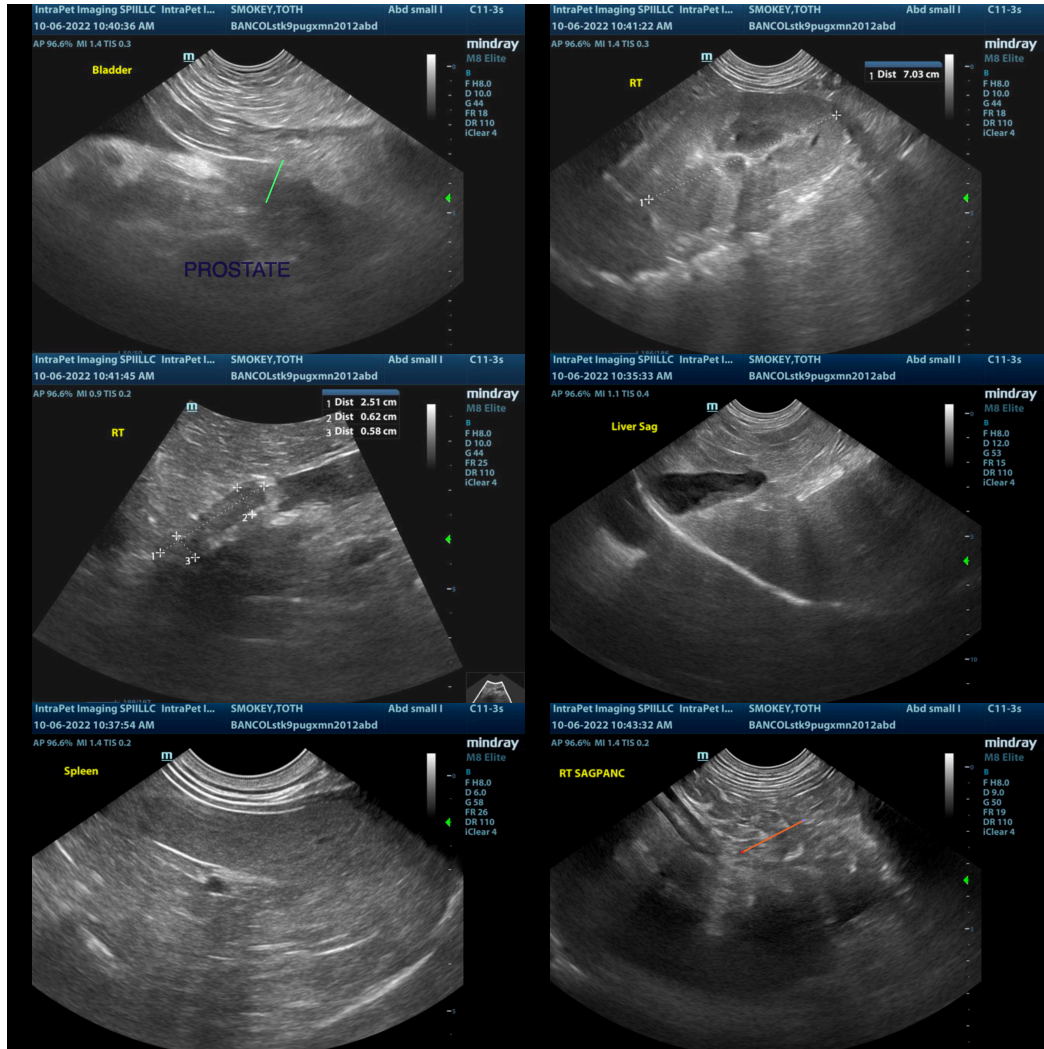
INTERPRETATION OF THE FINDINGS & FURTHER RECOMMENDATIONS

There is a mass effect caudal to the liver and ventral to the stomach. In some views, particularly the left cranial intercostal views, this appears to be splenic in origin, although a definitive attachment is not clearly seen. Less likely this could be of hepatic origin, an effaced lymph node, etc. Options include a possible fine needle aspirate or surgical explore with the intention for splenectomy, but the possibility from removal from another site. Additionally, you could consider a fine needle aspirate of the body of the spleen, as it does appear mottled.

Recommend three view thoracic radiographs to evaluate for possible concurrent thoracic disease/involvement.

The liver is large and heterogeneous. This is a non-specific finding, possibly consistent with a vacuolar hepatopathy/steroid hepatopathy, which can take several months to improve post discontinuation of chronic Prednisone therapy. If there is concern regarding anesthesia due to liver enzyme elevations, recommend a liver function test, and you could consider a fine needle aspirate of the liver. If surgery is pursued to evaluate the mass effect, then consider a biopsy of the liver at the same time.





The information and recommendations provided are based on the images presented by the referring veterinarian/sonographer. No evaluation can be communicated regarding pathology that was not visible in the image/video clips provided.

Thank you for this referral. If the clinical or image interpretation does not parallel your findings or if I can be of any further assistance please contact me.

Kathleen Sennello DVM,MS, Diplomate ACVIM (Small animal Internal Medicine)
 kathleen.sennello@sonopath.com