



PATIENT PRESENTING CLINICAL SIGNS

Hazel Kaczmarek

On Friday noticed urine out of litter box, then kitty was hiding which is very unusual for her. Has been going in and out of litterbox and only produces small drips of urine with blood in it. No vocalizing or vomiting but is straining and tail flagging in box. Normal BMs. Leaked a normal volume of urine on the couch while sleeping overnight. No history of trauma. Has been on Clavamox, Buprenorphine, Metacam and Prazosin. Very uncomfortable while scanning over caudal SQ mass and bladder. SQ mass has been there since shortly after her spay about 6.5 years ago. Owner did not think the size of the mass had changed until we shaved her long hair for the scan. Mass was xrayed and FNA done about 1 year ago and was diagnosed as a Lipoma. When poked today, the mass has urine in it.

SPECIES

Feline

BREED

DLH

Abnormal PE/Chem/CBC/UA Results: Xray sent out for comment and was suggested that there was no bladder on the xrays but that it may have prolapsed or twisted which is why ultrasound was recommended today.

SEX

Spayed Female

ULTRASONOGRAPHIC EXAMINATION OF THE ABDOMEN

Urinary System

AGE

8 Years

The urinary bladder is significantly dilated with anechoic urine. The urinary bladder appears to be located subcutaneously, where a large fluid-filled subcutaneous mass is located. The urethra can be visualized passing through the body wall, and there is omentum or fat in the subcutaneous space along with the urinary bladder. There are no stones or masses visualized. An obvious obstruction is not noted, but the bladder is significantly distended. There is no free fluid within the abdomen. Findings are most consistent with herniation of the bladder through the body wall. An image is submitted of aspiration of the fluid within the subcutaneous lesion, and it was grossly consistent with urine.

WEIGHT

5 kg

The left kidney has a normal shape and size (3.08 cm). Overall echogenicity is normal with adequate corticomedullary distinction and a typical 1:3 cortex:medulla ratio. There is no evidence of focal perinephric inflammation or effusion. There is no evidence of pyelectasia, nephroliths, infarcts or hydronephrosis. Renal vasculature is normal.

INTERPRETED BY

Kathleen Sennello DVM,
MS, Diplomate ACVIM
(Small Animal Internal
Medicine)

The right kidney has a normal shape and size (3.15 cm). Overall echogenicity is normal with adequate corticomedullary distinction and a typical 1:3 cortex:medulla ratio. There is no evidence of focal perinephric inflammation or effusion. There is no evidence of pyelectasia, nephroliths, infarcts or hydronephrosis. Renal vasculature is normal.

IMAGING PERFORMED BY

Crystal Hill

Adrenal Glands

HOSPITAL NAME

Ancaster AH

The left adrenal gland is normal in size measuring 0.25 cm at the caudal pole. It is observed in its normal position cranial to the left renal artery. It is normal in appearance (uniformly hypoechoic) and shape with no evidence of a mass effect.

REFERRING VET

Dr. Mathews

The right adrenal gland is normal in size measuring 0.38 cm at the caudal pole. It is observed in its normal position between the cranial aspect of the right kidney and the caudal vena cava. It is normal in appearance (uniformly hypoechoic) and shape with no evidence of a mass effect.

INVOICE

41853

Spleen

The spleen is subjectively normal in size, echotexture is homogenous, and the splenic capsule is smooth with no irregularities. The blood flow through the hilus and splenic parenchyma appears normal. No focal parenchymal abnormalities are visualized.

DATE

10/6/22



PATIENT *Liver*

Hazel Kaczmarek The liver is subjectively normal in size, and echogenicity with smooth peripheral margins. The parenchyma is homogenous echotexture. The visible portions of the vasculature and biliary tract appear normal. No focal nodules or cystic lesions are observed.

SPECIES

Feline

The gallbladder lumen is moderately distended. The wall of the gall bladder is not thickened and has a smooth mucosal surface. Luminal contents are mild and primarily anechoic. The cystic and common bile ducts are normal/not visible.

BREED

Gastrointestinal

DLH

The stomach contains minimal luminal contents. It measures at a normal thickness of <0.36cm with some variability due to the presence of rugal folds. The distinction of the gastric wall layers is adequate and there is no impression of reduced peristaltic activity. No masses or focal lesions were observed.

SEX

Spayed Female

The visualized areas of duodenum, jejunum and ileum have a relatively uniform diameter with minimal fluid distension. Wall thickness is normal. Bowel loops follow a curvilinear path with distinct wall layering maintaining the typical 1:3 muscularis:mucosa layer ratio. The duodenum measured as normal (between 0.13-0.38cm in wall thickness) and the jejunum measured as normal (between 0.15-0.36cm.) Visualized peristalsis appears appropriate. There were no focal lesions consistent with obstruction or a mass effect observed.

AGE

8 Years

WEIGHT

5 kg

The ileocecal junction was visualized and exhibited normal intact wall layering and is subjectively of normal thickness. Sections of colon are visualized with formed fecal material and gas shadowing distally. There is no observed focal or generalized colon wall thickening or loss of layering.

Pancreas

The pancreas is normal and isoechoic to surrounding mesentery. There is no evidence of nodules or cystic lesions. There is no evidence of regional mesenteric inflammation or fluid.

INTERPRETED BY

Kathleen Sennello DVM,
MS, Diplomate ACVIM
(Small Animal Internal
Medicine)

Free Abdomen

Evaluation of the peritoneal cavity did not reveal any evidence of effusion, or subjective lymphadenomegaly. The Medial iliac nodes appear normal and there was no evidence of a caudal aortic thrombus at the bifurcation. The omentum is of normal uniform echogenicity.

IMAGING PERFORMED BY

Crystal Hill

ULTRASONOGRAPHIC FINDINGS

HOSPITAL NAME

Ancaster AH

- Urinary bladder visualized external to the body wall in the subcutaneous space – most consistent with herniation of the urinary bladder, possibly through an inguinal hernia, umbilical hernia, other.

INTERPRETATION OF THE FINDINGS & FURTHER RECOMMENDATIONS

REFERRING VET

Dr. Mathews

The urinary bladder is large and visualized external to the body wall. Based on the history provided, there does not appear to be a complete obstruction, but the ability to urinate is likely impaired based on the size of the structure. Surgical reduction and repair of the hernia is recommended. A contrast study can be used to confirm the location, but sampling of urine in the subcutaneous mass lesion is highly suggestive. Confirm patency of the urethra at the time of surgery. There is a chance that delaying surgery could compromise blood flow to the urinary bladder.

INVOICE

41853

DATE

10/6/22



PATIENT

Hazel Kaczmarek

SPECIES

Feline

BREED

DLH

SEX

Spayed Female

AGE

8 Years

WEIGHT

5 kg

INTERPRETED BY

Kathleen Sennello DVM,
MS, Diplomate ACVIM
(Small Animal Internal
Medicine)

**IMAGING
PERFORMED BY**

Crystal Hill

HOSPITAL NAME

Ancaster AH

REFERRING VET

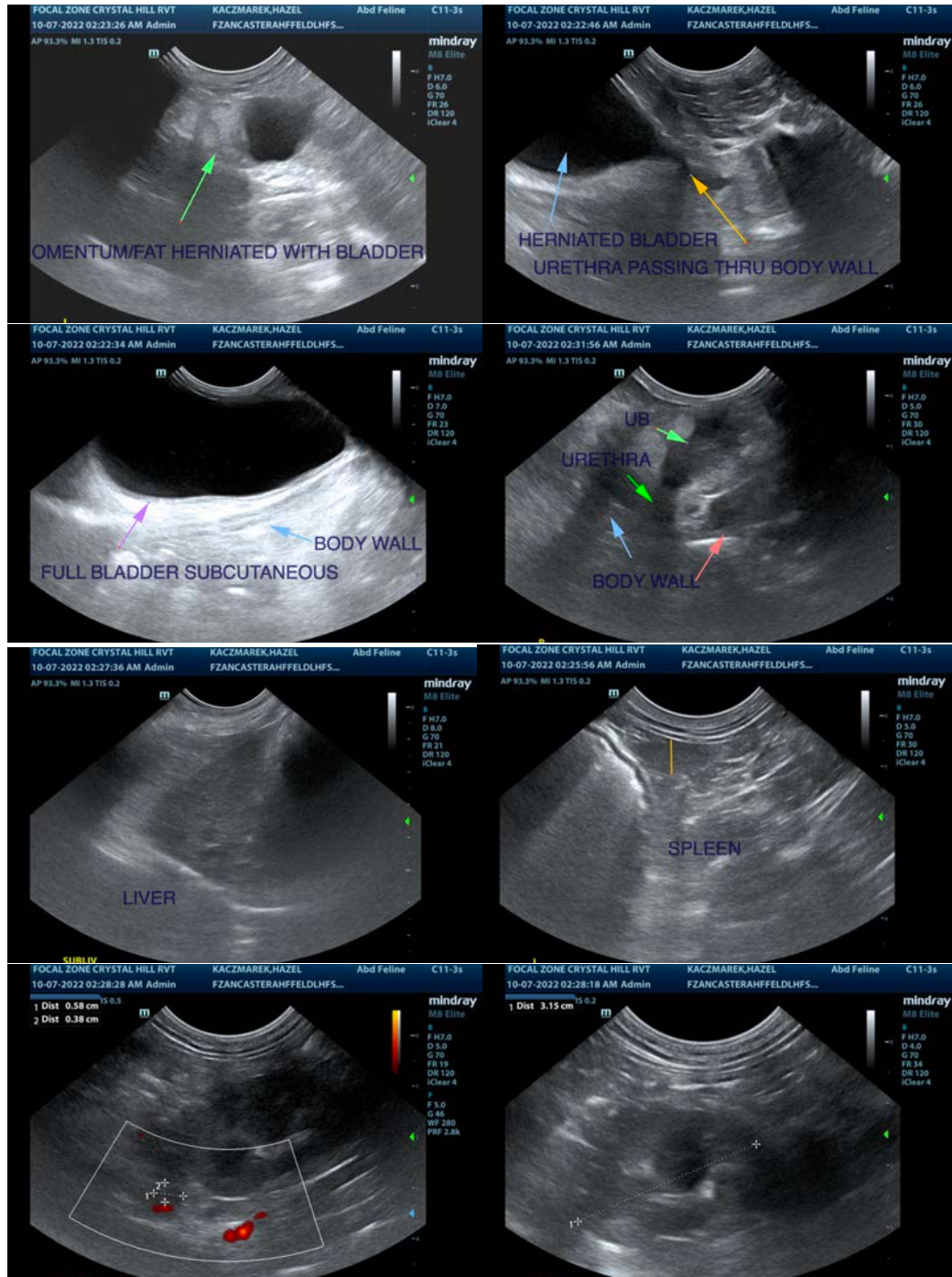
Dr. Mathews

INVOICE

41853

DATE

10/6/22





PATIENT

Hazel Kaczmarek

SPECIES

Feline

BREED

DLH

SEX

Spayed Female

AGE

8 Years

WEIGHT

5 kg

INTERPRETED BY

Kathleen Sennello DVM,
MS, Diplomate ACVIM
(Small Animal Internal
Medicine)

**IMAGING
PERFORMED BY**

Crystal Hill

HOSPITAL NAME

Ancaster AH

REFERRING VET

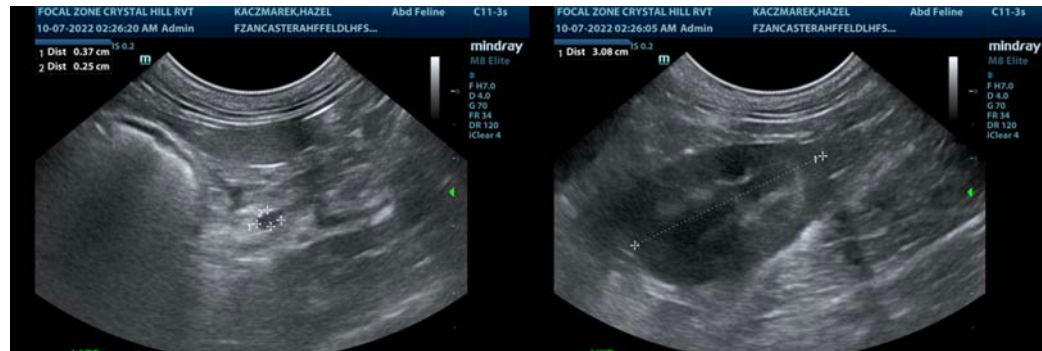
Dr. Mathews

INVOICE

41853

DATE

10/6/22



The information and recommendations provided are based on the images presented by the referring veterinarian/sonographer. No evaluation can be communicated regarding pathology that was not visible in the image/video clips provided.

Thank you for this referral. If the clinical or image interpretation does not parallel your findings or if I can be of any further assistance please contact me.

Kathleen Sennello DVM,MS, Diplomate ACVIM (Small animal Internal Medicine)

kathleen.sennello@sonopath.com