



PATIENT

Eskarina Towsley

SPECIES

Feline

BREED

DSH

SEX

Spayed Female

AGE

6 Years

WEIGHT

6.8 Pounds

INTERPRETED BY

Kathleen Sennello DVM,
MS, Diplomate ACVIM
(Small Animal Internal
Medicine)

**IMAGING
PERFORMED BY**

Dr. Jessica Bailes

HOSPITAL NAME

All Creatures
Great & Small

REFERRING VET

Dr. Jessica Bailes

INVOICE

41877

DATE

10/6/22

PRESENTING CLINICAL SIGNS

hx of progressive weight loss; no other symptoms noted @ home. Prior hx of mild hypercalcemia (11.4), otherwise previous bloodwork unremarkable.

Abnormal PE/Chem/CBC/UA Results: thin BCS; normal MCS. Dental disease, otherwise NSF on PE Bloodwork done 9/22; HEM: mildly increased ALB (3.9), mild hypercalcemia (11.8); creat = 1.4 CBC: thrombocytopenia (97k) w/ adequate estimate TT4: WNL @ 2.0 Thoracic rads: NSF ionized calcium/pTH pending.

ULTRASONOGRAPHIC EXAMINATION OF THE ABDOMEN

Urinary System

The urinary bladder is moderately distended with anechoic urine. The Bladder wall, trigone, ureteral papillae and visible urethra (to a depth of 2cm) appear normal with no evidence of wall thickening, mucosal irregularities, masses or cystic calculi.

The left kidney has a normal shape and size (3.89 cm). Overall echogenicity is normal with adequate corticomedullary distinction and a typical 1:3 cortex:medulla ratio. There is no evidence of focal perinephric inflammation or effusion. There is no evidence of pyelectasia, nephroliths, infarcts or hydroureter. Renal vasculature is normal.

The right kidney has a normal shape and size (3.47 cm). Overall echogenicity is normal with adequate corticomedullary distinction and a typical 1:3 cortex:medulla ratio. There is no evidence of focal perinephric inflammation or effusion. There is no evidence of pyelectasia, nephroliths, infarcts or hydroureter. Renal vasculature is normal.

Adrenal Glands

The left adrenal gland is normal in size measuring 0.25 cm at the caudal pole. It is observed in its normal position cranial to the left renal artery. It is normal in appearance (uniformly hypoechoic) and shape with no evidence of a mass effect.

The right adrenal gland is normal in size measuring 0.26 cm at the caudal pole. It is observed in its normal position between the cranial aspect of the right kidney and the caudal vena cava. It is normal in appearance (uniformly hypoechoic) and shape with no evidence of a mass effect.

Spleen

The spleen is subjectively normal in size, echotexture is homogenous, and the splenic capsule is smooth with no irregularities. The blood flow through the hilus and splenic parenchyma appears normal. No focal parenchymal abnormalities are visualized.

Liver

The liver is subjectively normal in size, and echogenicity with smooth peripheral margins. The parenchyma is homogenous echotexture. The visible portions of the vasculature and biliary tract appear normal. No focal nodules or cystic lesions are observed.

The gallbladder lumen is moderately distended. The wall of the gall bladder is not thickened and has a smooth mucosal surface. Luminal contents are mild and primarily anechoic. The cystic and common bile ducts are normal/not visible.



PATIENT

Gastrointestinal

Eskarina Towsley

The stomach contains minimal luminal contents. It measures at a normal thickness of <0.36cm with some variability due to the presence of rugal folds. The distinction of the gastric wall layers is adequate and there is no impression of reduced peristaltic activity. No masses or focal lesions were observed.

SPECIES

Feline

The visualized areas of duodenum, jejunum and ileum have a relatively uniform diameter with minimal fluid distension. Wall thickness is normal. Bowel loops follow a curvilinear path with distinct wall layering maintaining the typical 1:3 muscularis:mucosa layer ratio. Jejunum wall measures 0.19 cm.

BREED

DSH

Visualized peristalsis appears appropriate. There were no focal lesions consistent with obstruction or a mass effect observed.

SEX

Spayed Female

The ileocecal junction was visualized and exhibited normal intact wall layering and is subjectively of normal thickness. Sections of colon are visualized with formed fecal material and gas shadowing distally. There is no observed focal or generalized colon wall thickening or loss of layering.

AGE

6 Years

Pancreas

The pancreas is normal and isoechoic to surrounding mesentery. There is no evidence of nodules or cystic lesions. There is no evidence of regional mesenteric inflammation or fluid.

WEIGHT

6.8 Pounds

Free Abdomen

Evaluation of the peritoneal cavity did not reveal any evidence of effusion, or subjective lymphadenomegaly. The Medial iliac nodes appear normal and there was no evidence of a caudal aortic thrombus at the bifurcation. The omentum is of normal uniform echogenicity.

ULTRASONOGRAPHIC FINDINGS

- No significant lesions observed on today's scan

INTERPRETED BY

Kathleen Sennello DVM,
MS, Diplomate ACVIM
(Small Animal Internal
Medicine)

INTERPRETATION OF THE FINDINGS & FURTHER RECOMMENDATIONS

An obvious source of the weight loss reported is not identified. Recommend further investigation to the hypercalcemia. Recommend an ionized calcium, PTH/PTHrP level to determine if this is a significant hypercalcemia, and if you can identify the cause. Recommend 3-view thoracic radiographs. If a CBC is normal, and imaging is normal, as well as a rectal exam to evaluate for anal gland abnormalities and a good oral exam, and PTH levels are low (if ionized calcium is high), then consider the possibility of idiopathic hypercalcemia and possible treatment.

IMAGING PERFORMED BY

Dr. Jessica Bailes

Additionally, there is the possibility of underlying gastrointestinal disease with no significant lesions. You could consider a novel protein/hydrolyzed protein prescription diet, probiotic therapy, and a GI panel to Texas A&M for a qualitative fPLI, TLI, cobalamin and folate to look for evidence of underlying pancreatic or small intestinal disease.

HOSPITAL NAME

All Creatures
Great & Small

REFERRING VET

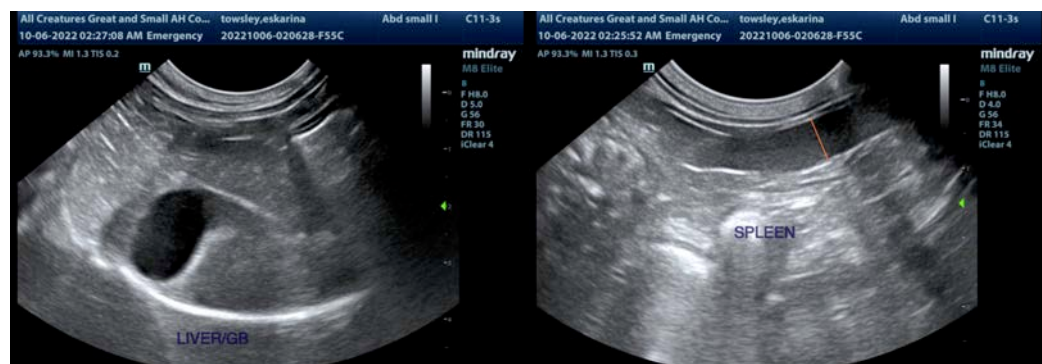
Dr. Jessica Bailes

INVOICE

41877

DATE

10/6/22





PATIENT

Eskarina Towsley

SPECIES

Feline

BREED

DSH

SEX

Spayed Female

AGE

6 Years

WEIGHT

6.8 Pounds

INTERPRETED BY

Kathleen Sennello DVM,
MS, Diplomate ACVIM
(Small Animal Internal
Medicine)

**IMAGING
PERFORMED BY**

Dr. Jessica Bailes

HOSPITAL NAME

All Creatures
Great & Small

REFERRING VET

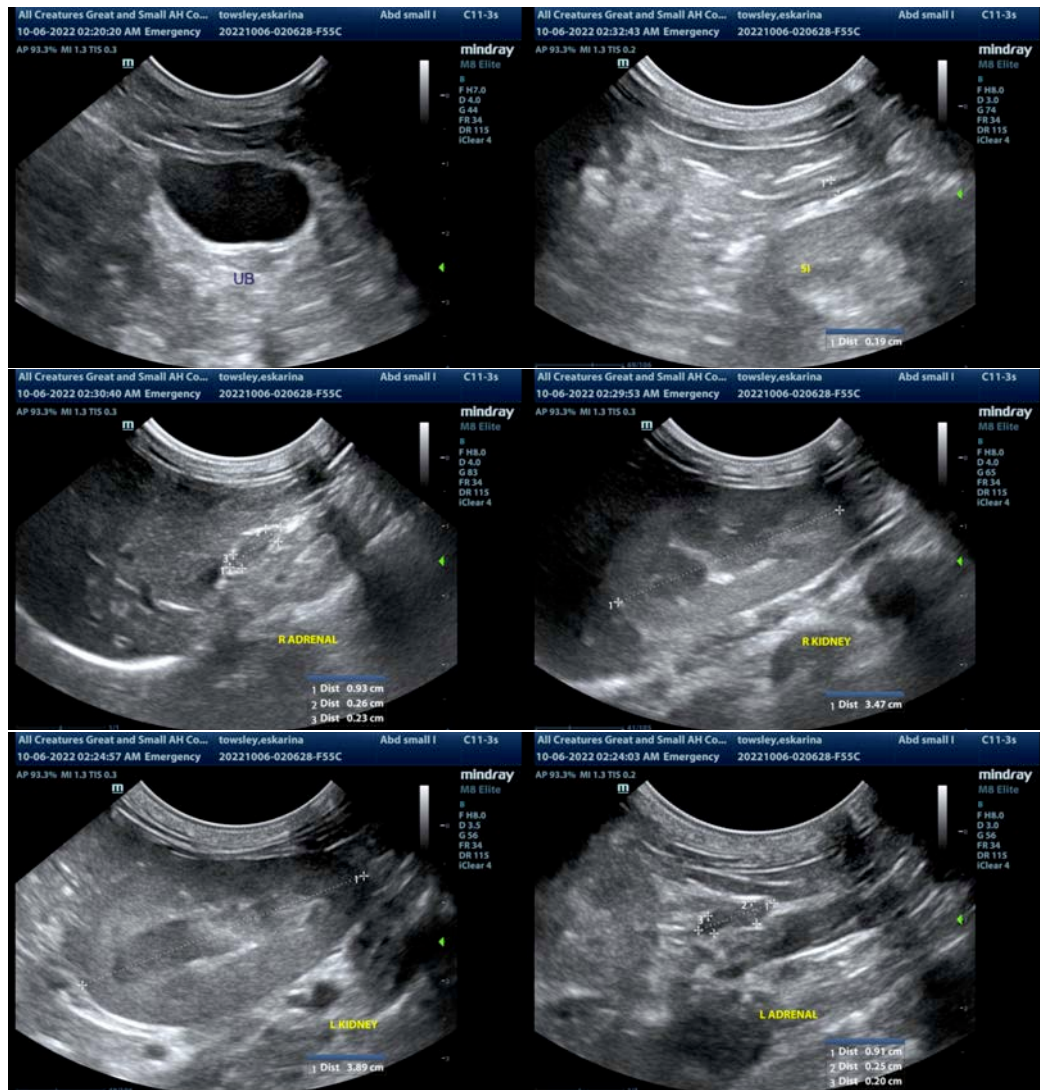
Dr. Jessica Bailes

INVOICE

41877

DATE

10/6/22



The information and recommendations provided are based on the images presented by the referring veterinarian/sonographer. No evaluation can be communicated regarding pathology that was not visible in the image/video clips provided.

Thank you for this referral. If the clinical or image interpretation does not parallel your findings or if I can be of any further assistance please contact me.

Kathleen Sennello DVM,MS, Diplomate ACVIM (Small animal Internal Medicine)

kathleen.sennello@sonopath.com