

**PATIENT**

Sailor Stewart

**PRESENTING CLINICAL SIGNS**

suspicion of liver disease  
Abnormal PE/Chem/CBC/UA Results: elevated ALT, ALP, AST, amyl, platelets

**SPECIES**

Feline

**ULTRASONOGRAPHIC EXAMINATION OF THE ABDOMEN**

**Urinary System**

**BREED**

DLH

The urinary bladder is moderately distended with anechoic urine. The Bladder wall, trigone, ureteral papillae and visible urethra (to a depth of 2cm) appear normal with no evidence of wall thickening, mucosal irregularities, masses or cystic calculi.

**SEX**

Neutered Male

The left kidney has a normal shape and size (3.89 cm). Overall echogenicity is normal with adequate corticomedullary distinction and a typical 1:3 cortex:medulla ratio. There is no evidence of perinephric inflammation or effusion. There is no evidence of pyelectasia, nephroliths, infarcts or hydroureter. Renal vasculature is normal.

**AGE**

15 Years

The right kidney has a normal shape and size (3.81 cm). Overall echogenicity is normal with adequate corticomedullary distinction and a typical 1:3 cortex:medulla ratio. There is no evidence of perinephric inflammation or effusion. There is no evidence of pyelectasia, nephroliths, infarcts or hydroureter. Renal vasculature is normal.

**WEIGHT**

9.5 Pounds

**Adrenal Glands**

The left adrenal gland is normal in size measuring 0.38 cm at the caudal pole. It is observed in its normal position cranial to the left renal artery. It is normal in appearance (uniformly hypoechoic) and shape with no evidence of a mass effect.

**INTERPRETED BY**

Kathleen Sennello  
DVM, MS, Diplomate  
ACVIM (Small Animal  
Internal Medicine)

The right adrenal gland is normal in size measuring 0.35 cm at the caudal pole. It is observed in its normal position between the cranial aspect of the right kidney and the caudal vena cava. It is normal in appearance (uniformly hypoechoic) and shape with no evidence of a mass effect.

**IMAGING PERFORMED BY**

Kelly Reschny

**Spleen**

The spleen is subjectively normal in size. The spleen echotexture is heterogenous and mottled, the splenic capsule is smooth with no irregularities. The blood flow through the hilus and splenic parenchyma appears normal. There is an approximately 1.1 cm cavitated/cystic hyperechoic lesion visualized towards the edge of the spleen, which deviates the splenic capsule. Medial to the spleen is a large, mixed echogenic, somewhat cystic mass effect. No direct communication with the spleen is observed, but it could be of splenic or pancreatic origin, or could be an isolated mass effect.

**HOSPITAL NAME**

Tillsonburg VC

**Liver**

The liver is subjectively normal in size, and echogenicity with smooth peripheral margins. The parenchyma is heterogenous in echotexture with subtle, indistinct focal mottling. The visible portions of the vasculature and biliary tract appear normal. No focal nodules or cystic lesions are observed.

**REFERRING VET**

Dr. McDowell

The gallbladder lumen is moderately distended. The wall of the gall bladder is not thickened and has a smooth mucosal surface. Luminal contents are primarily anechoic. The cystic and common bile ducts are normal/not visible.

**INVOICE**

26116

**DATE**

10/6/21



**PATIENT**

Sailor Stewart

**SPECIES**

Feline

**BREED**

DLH

**SEX**

Neutered Male

**AGE**

15 Years

**WEIGHT**

9.5 Pounds

**INTERPRETED BY**

Kathleen Sennello  
DVM, MS, Diplomate  
ACVIM (Small Animal  
Internal Medicine)

**IMAGING  
PERFORMED BY**

Kelly Reschny

**HOSPITAL NAME**

Tillsonburg VC

**REFERRING VET**

Dr. McDowell

**INVOICE**

26116

**DATE**

10/6/21

**Gastrointestinal**

The stomach contains minimal luminal contents. It measures at a normal thickness of <0.36cm with some variability due to the presence of rugal folds. The distinction of the gastric wall layers is adequate and there is no impression of reduced peristaltic activity. No masses or focal lesions were observed.

The visualized areas of duodenum, jejunum and ileum have a relatively uniform diameter with minimal fluid distension. Wall thickness is normal. Bowel loops follow a curvilinear path with distinct wall layering maintaining the typical 1:3 muscularis:mucosa layer ratio. The duodenum measured as normal (between 0.13-0.38cm in wall thickness) and the jejunum measured as normal (between 0.15-0.36cm.) Visualized peristalsis appears appropriate. There were no focal lesions consistent with obstruction or a mass effect observed.

The ileocecal junction was visualized and exhibited normal intact wall layering and is subjectively of normal thickness. Sections of colon are visualized with formed fecal material and gas shadowing distally. There is no observed focal or generalized colon wall thickening or loss of layering.

**Pancreas**

There is a large mixed echogenic, mottled, mildly cystic mass effect in the region of the pancreas, measuring 5.39 cm x 5.20 cm. In some images, this appears associated with the pancreas, which is slightly hypoechoic and prominent. Alternately, it could just be in the same location and in contact with this tissue.

**Free Abdomen**

There is a pocket of echogenic free fluid visible. There is no significant lymphadenopathy visualized. The omentum is generally of increased echogenicity.

**Other**

There is a large mid abdominal mixed echogenic mass that has irregular borders and some cystic/cavitated areas. This mass measures 5.39 cm x 5.2 cm with a 1.6 cm hyperechoic nodule in the center. This mass lesion is in the region of the pancreas, but is also in contact with the spleen and parts of the liver. Origin is uncertain.

**ULTRASONOGRAPHIC FINDINGS**

- Large, irregular, somewhat cystic mid abdominal mass of uncertain origin. This is in the region of the pancreas and contacts the pancreas, so it could be of pancreatic origin. I cannot exclude spleen either, as it is in contact with this region, or an isolated mass effect. Concern is high for a neoplastic process.
- Splenic nodule – This is nodule is concerning for a possible metastatic lesion, but could also be a benign or cancerous lesion unrelated to the large mass effect.
- Heterogeneous liver – The diffuse hepatic changes are non-specific and could be consistent with vacuolar hepatopathy, nodular hyperplasia, inflammatory/immune-mediated disease, fibrosis, extramedullary hematopoiesis, toxic hepatopathy (e.g., copper), infiltrative neoplasia (less likely) or other hepatopathy.

**INTERPRETATION OF THE FINDINGS & FURTHER RECOMMENDATIONS**

There is a very large abdominal mass that is partially cystic and irregular. this mass is large and touches the spleen, pancreas, and possibly parts of the liver. I would suspect pancreatic origin, as the pancreas appears abnormal, but this could just be due to localized inflammation. Recommend fine needle aspirate



**PATIENT**

Sailor Stewart

of the mass effect, advanced imaging (CT scan) and/or referral to a veterinary surgeon for exploratory surgery, biopsy and resection if possible. Recommend 3-view thoracic radiographs. Prognosis is guarded.

**SPECIES**

Feline

**BREED**

DLH

**SEX**

Neutered Male

**AGE**

15 Years

**WEIGHT**

9.5 Pounds

**INTERPRETED BY**

Kathleen Sennello  
DVM, MS, Diplomate  
ACVIM (Small Animal  
Internal Medicine)

**IMAGING PERFORMED BY**

Kelly Reschny

**HOSPITAL NAME**

Tillsonburg VC

**REFERRING VET**

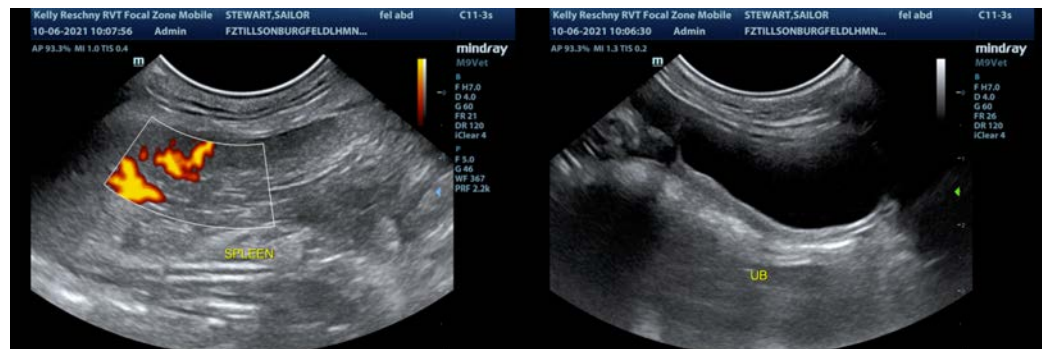
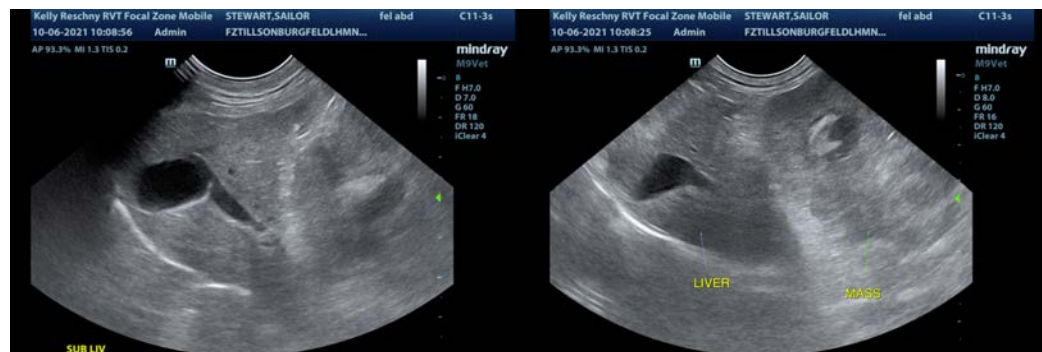
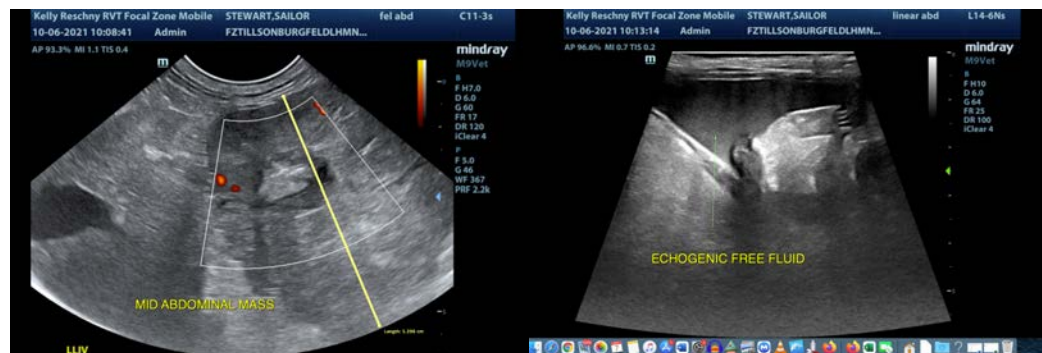
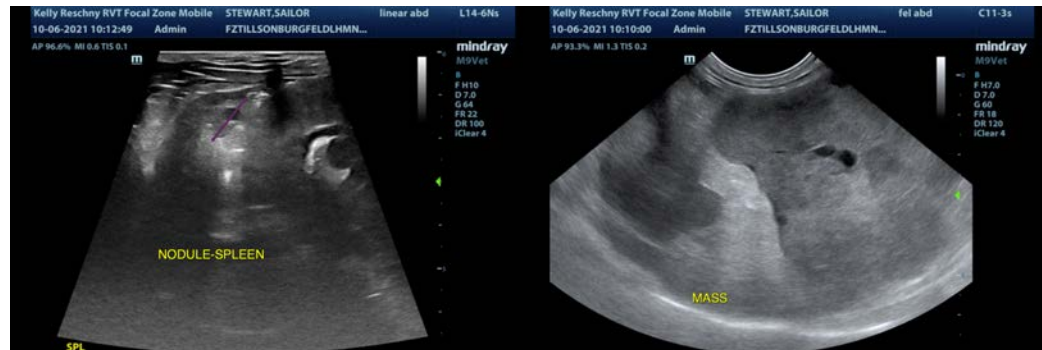Dr. McDowell

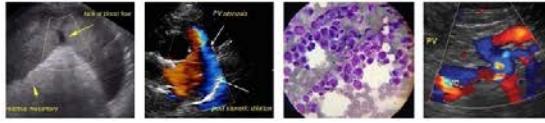
**INVOICE**

26116

**DATE**

10/6/21





**PATIENT**

Sailor Stewart

**SPECIES**

Feline

**BREED**

DLH

**SEX**

Neutered Male

**AGE**

15 Years

**WEIGHT**

9.5 Pounds

**INTERPRETED BY**

Kathleen Sennello  
DVM, MS, Diplomate  
ACVIM (Small Animal  
Internal Medicine)

**IMAGING  
PERFORMED BY**

Kelly Reschny

**HOSPITAL NAME**

Tillsonburg VC

**REFERRING VET**

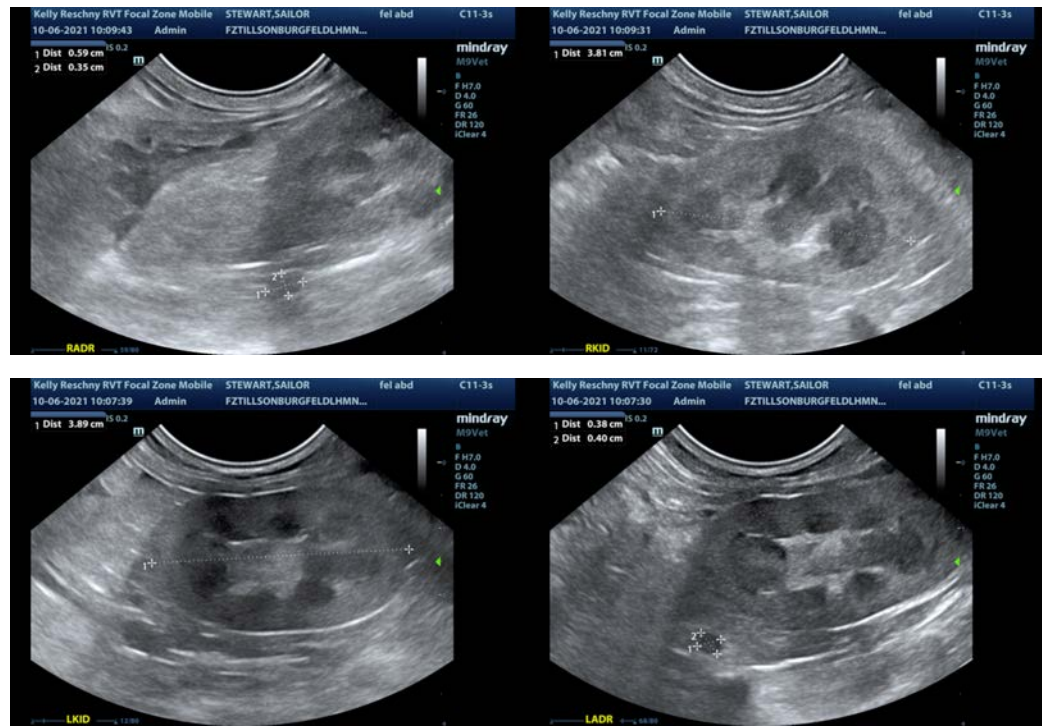
Dr. McDowell

**INVOICE**

26116

**DATE**

10/6/21



The information and recommendations provided are based on the images presented by the referring veterinarian. No evaluation can be communicated regarding pathology that was not visible in the image/video clips provided.

Thank you for this referral. If the clinical or image interpretation does not parallel your findings or if I can be of any further assistance please contact me.

Kathleen Sennello DVM,MS, Diplomate ACVIM (Small animal Internal Medicine)

kathleen.sennello@sonopath.com