

**DATE**

10/6/21

PRESENTING CLINICAL SIGNS

Recent diagnosis of cushings disease via low dose dex test.
Owner elected to have abdominal ultrasound performed prior to starting on trilostane therapy to mainly look at adrenal glands.

PATIENT

Maximus Durham

Current Medications: None

Lab Results: elevated (ALKP unreadable recent and 6500 at end of august) and mildly elevated ALT 138.
normal SDMA 11.

Radiographs: abdomen and chest unremarkable

Date of Previous IntraPet Ultrasound: No previous

SPECIES

Canine

Sedation: unable – not fasted, sedation likely required for further imaging

Stat Report: not requested

BREED

Pit Bull

ULTRASONOGRAPHIC EXAMINATION OF THE ABDOMEN**Urinary System**

The urinary bladder is moderately distended with anechoic urine. The bladder wall, trigone, ureteral papillae and visible urethra (to a depth of 2cm) appear normal with no evidence of wall thickening, mucosal irregularities or masse. There is a line of dependent mineralized shadowing and sandy debris in the urinary bladder. This extends down into the proximal urethra.

SEX

Neutered male

AGE

2012

The prostate is normal in size (1.37 cm) and shape for this neutered male dog. The parenchyma is homogenous and the external margins are smooth. The prostatic urethra appears normal with no evidence of irregularity, invasion, mass effect or calculi.

WEIGHT

60 lbs

The left kidney has a normal shape and size (8.75 cm). Overall echogenicity is slightly hyperechoic with poor corticomedullary distinction and a typical 1:3 cortex:medulla ratio. There is no evidence of perinephric inflammation or effusion. There is a mineralized foci within the renal pelvis and dilated calicies. The cortex is hyperechoic and somewhat speckled. There is no evidence of pyelectasia, infarcts or hydroureter. Renal vasculature is normal.

INTERPRETED BY

Kathleen Sennello
DVM, MS, Diplomate
ACVIM (Small Animal
Internal Medicine)

The right kidney has a normal shape and size (7.55 cm). Overall echogenicity is slightly hyperechoic with poor corticomedullary distinction and a typical 1:3 cortex:medulla ratio. There is no evidence of perinephric inflammation or effusion. Non-obstructive nephroliths were noted. There is no evidence of pyelectasia, infarcts or hydroureter. Renal vasculature is normal.

HOSPITAL NAME

Banfield Pet Hospital
Westminster

Adrenal Glands

The left adrenal gland is large measuring 2.47 cm at the cranial pole, 2.84 cm at the caudal pole and the length is 4.62 cm. It appears to be in its relatively normal position and is fairly normal in appearance as the echotexture is homogenous. The shape is relatively normal and ovoid, but it is very large. This is most consistent with a left adrenal gland mass.

REFERRING VET

Dr. Jantz Stepbis

The right adrenal gland is normal/small in size measuring 0.54 cm at the caudal pole. It is observed in its normal position between the cranial aspect of the right kidney and the caudal vena cava. It is normal in appearance (uniformly hypoechoic) and shape with no evidence of a mass effect.

INVOICE

92203

Spleen

The spleen is subjectively normal in size The spleen echotexture is heterogenous and mottled, the splenic capsule is smooth with no irregularities. The blood flow through the hilus and splenic parenchyma appears normal. There is a 2.66 x 2.34 mixed echogenic mass that is deviating the splenic capsule towards the tail of the spleen.

Liver

The liver is subjectively normal in size, and echogenicity with smooth peripheral margins. The parenchyma is heterogenous in echotexture with subtle, indistinct focal mottling. The visible portions of the vasculature and biliary tract appear normal. No focal nodules or cystic lesions are observed. The gallbladder lumen is moderately distended. The wall of the gallbladder is not thickened and has a smooth mucosal surface. There is a large amount of primarily, non-organized echogenic debris, but there is early organization evident. This is most consistent with an early forming mucocele. There is no evidence of bile duct dilation.

Gastrointestinal

The stomach contains minimal luminal contents. It measures at a normal thickness of <0.7cm with some variability due to the presence of rugal folds. The distinction of the gastric wall layers is adequate and there is no impression of reduced peristaltic activity. No masses or focal lesions were observed.

The visualized areas of duodenum, jejunum and ileum have a relatively uniform diameter with minimal fluid distension. Wall thickness is normal. Bowel loops follow a curvilinear path with distinct wall layering maintaining the typical 1:3 muscularis:mucosa layer ratio. The duodenum measured as normal (between 0.3-0.5cm in wall thickness) and the jejunum measured as normal (between 0.2-0.47cm.) Visualized peristalsis appears appropriate. There were no focal lesions consistent with obstruction or a mass effect observed.

The ileocecal junction was visualized and exhibited normal intact wall layering and is subjectively of normal thickness. Sections of colon are visualized with formed fecal material and gas shadowing distally. There is no observed focal or generalized colon wall thickening or loss of layering.

Pancreas

The pancreas is normal and isoechoic to surrounding mesentery. There is no evidence of nodules or cystic lesions. There is no evidence of regional mesenteric inflammation or fluid.

Free Abdomen

Evaluation of the peritoneal cavity did not reveal any evidence of effusion, or subjective lymphadenomegaly. The Medial iliac nodes appear normal and there was no evidence of a caudal aortic thrombus at the bifurcation. The omentum is of normal uniform echogenicity.

ULTRASONOGRAPHIC FINDINGS

PRIMARY FINDINGS:

- Left sided adrenal mass with right sided adrenal atrophy. Left adrenomegaly could be consistent with neoplasia (e.g., adenoma, carcinoma, pheochromocytoma), hyperplasia, inflammation, other.
- Dependent sandy debris in the urinary bladder and proximal urethra. I recommend urinalysis and culture and correlate with abdominal radiographs.
- Decreased corticomedullary distinction in both kidneys with left-sided cortical mineralization and possible early/partial obstruction. The hyperechoic mineralized foci observed at the corticomedullary junction of the left/right kidney are consistent with small, non-obstructive nephroliths.
- Mixed echogenic splenic mass. The mass distorts the splenic capsule. Differentials for the mass include neoplasia (hemangiosarcoma), hemangioma, hematoma, abscess, other. A neoplastic process is suspected.

- Large heterogenous liver. The diffuse hepatic changes are non-specific and could be consistent with vacuolar hepatopathy, nodular hyperplasia, inflammatory/immune-mediated disease, fibrosis, extramedullary hematopoiesis, toxic hepatopathy (e.g., copper), infiltrative neoplasia (less likely) or other hepatopathy.
- Early gallbladder mucocele. The findings are consistent with an early mucocele. There is no surrounding inflammation or wall thickening noted.

SECONDARY FINDINGS:

- Gastric dilation with a large amount of ingesta. Per history this patient was recently fed. This shadowing can inhibit full evaluation of the cranial abdomen.

INTERPRETATION OF THE FINDINGS & FURTHER RECOMMENDATIONS

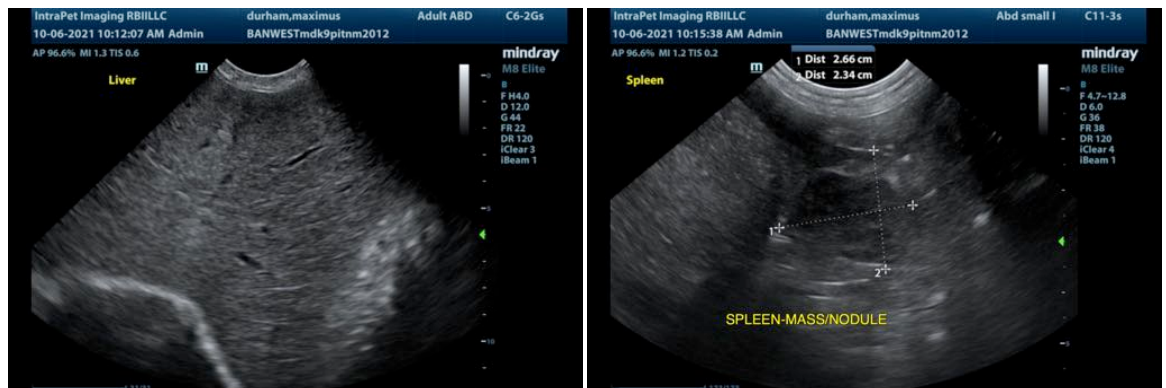
The findings are most consistent with a left-sided adrenal mass and adrenal dependent hyperadrenocorticism. If surgical therapy is not an option then medical therapy can still be tried, but surgical therapy would be the treatment of choice. If this is an option I recommend three view thoracic radiographs and referral to a veterinary surgeon with likely preoperative advanced imaging (CT scan). I recommend blood pressure evaluation.

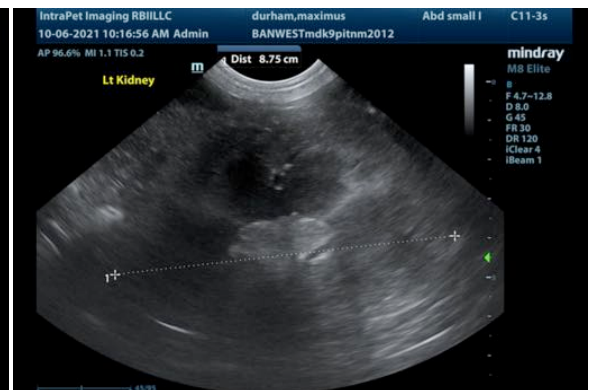
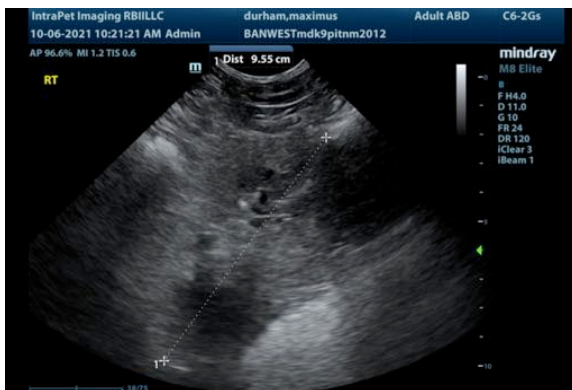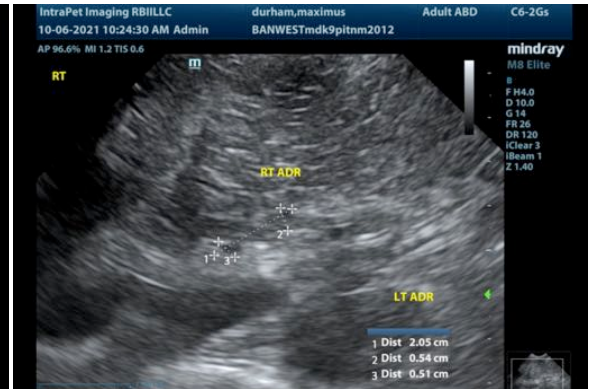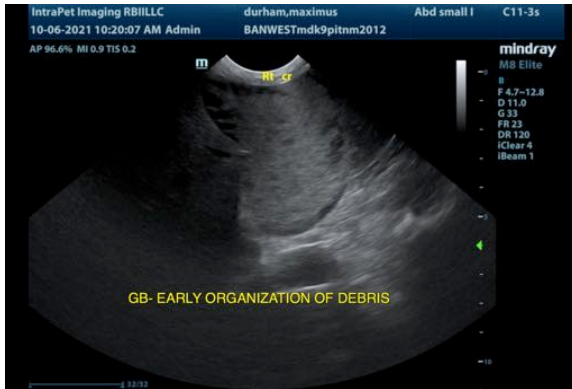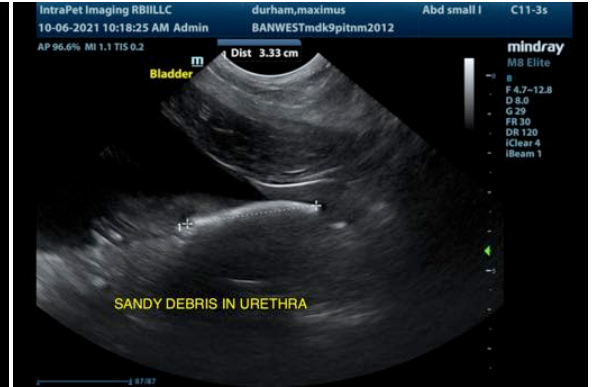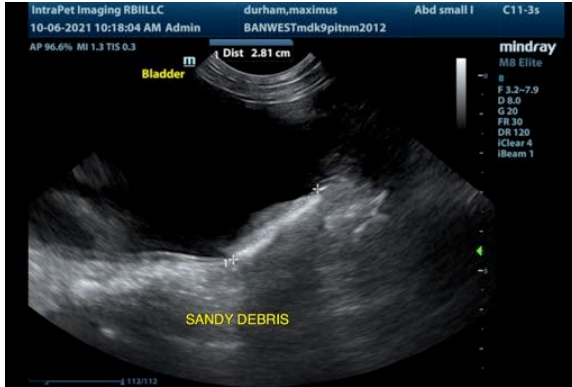I recommend urinalysis and culture as well as monitoring of urine output of possible event of urethral obstruction.

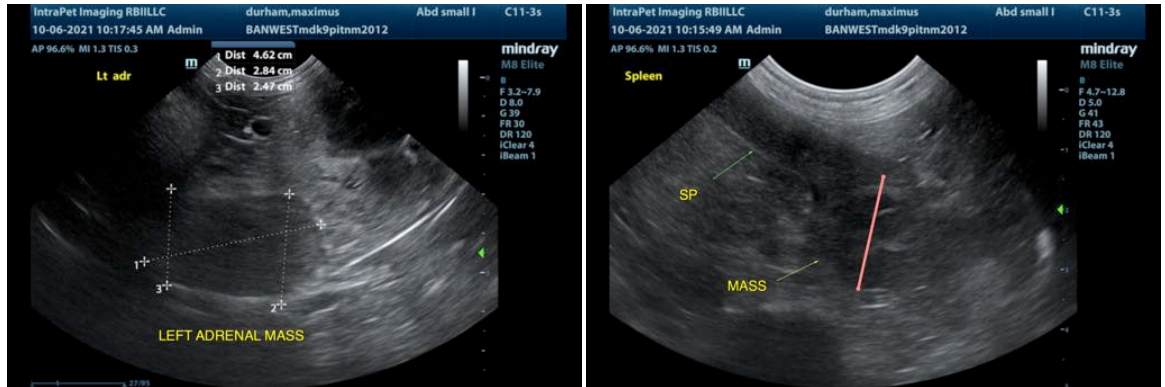
Additionally there is a splenic mass. You can consider a FNA, but the ideal scenario would be splenectomy at the time of adrenalectomy.

The liver is large and heterogenous. This is likely a vacuolar hepatopathy secondary to Cushing's disease that was diagnosed. Additionally there is an early mucocele present. Consider starting Ursodiol and monitoring for progression.

There is bilateral renal mineralization and age related change in the kidneys. I recommend to continue monitoring the renal function.







The information and recommendations provided are based on the images presented by the referring veterinarian. No evaluation can be communicated regarding pathology that was not visible in the image/video clips provided.

Thank you for this referral. If the clinical or image interpretation does not parallel your findings or if I can be of any further assistance please contact me.

Kathleen Sennello DVM,MS, Diplomate ACVIM (Small animal Internal Medicine)
kathleen.sennello@sonopath.com