

**DATE**

10/6/21

**PRESENTING CLINICAL SIGNS**

Long-term Cushing's suspect, owner has elected not to pursue further diagnostics previously but now we are seeing some additional liver value elevations on bloodwork that raise concern for other possible issues. Current Medications: Occasional Carprofen. Consider more routine Carprofen use but concerned for hepatic health.

**PATIENT**

Jack Nash

Lab Results: elevated liver values. ALP has always been elevated, now ALT and GGT are also elevated, moderate

~8.2K lymphocytosis - slowly creeping up for a year or two

Date of Previous IntraPet Ultrasound: No previous

**SPECIES**

Canine

Sedation: not needed

Stat Report: not requested

**BREED**

Shih Tzu

**ULTRASONOGRAPHIC EXAMINATION OF THE ABDOMEN****Urinary System**

The urinary bladder is moderately distended with anechoic urine. The Bladder wall, trigone, ureteral papillae and visible urethra (to a depth of 2cm) appear normal with no evidence of wall thickening, mucosal irregularities, masses or cystic calculi.

**SEX**

Neutered male

The prostate is normal in size (0.97 cm) and shape for this neutered male dog. The parenchyma is homogenous and the external margins are smooth. The prostatic urethra appears normal with no evidence of irregularity, invasion, mass effect or calculi.

**AGE**

2010

The left kidney has a normal shape and size (4.74 cm). Overall echogenicity is normal with adequate corticomedullary distinction and a typical 1:3 cortex:medulla ratio. There is no evidence of perinephric inflammation or effusion. Non-obstructive nephroliths were noted. The largest measures 0.34 cm. There is no evidence of pyelectasia, infarcts or hydroureter. Renal vasculature is normal.

**WEIGHT**

17.2 lbs

The right kidney has a normal shape and size (4.14 cm). Overall echogenicity is normal with adequate corticomedullary distinction and a typical 1:3 cortex:medulla ratio. There is no evidence of perinephric inflammation or effusion. Non-obstructive nephroliths were noted. The largest measures 0.28 cm. There is no evidence of pyelectasia, infarcts or hydroureter. Renal vasculature is normal.

**INTERPRETED BY**

Kathleen Sennello  
DVM, MS, Diplomate  
ACVIM (Small Animal  
Internal Medicine)

**Adrenal Glands**

The left adrenal gland is large in size measuring 0.93 cm at the caudal pole It is observed in its normal position cranial to the left renal artery. It is normal in appearance (uniformly hypoechoic) and shape with no evidence of a mass effect.

**HOSPITAL NAME**

Airpark AH

The right adrenal gland is normal/borderline large in size measuring 0.69 cm at the caudal pole It is observed in its normal position between the cranial aspect of the right kidney and the caudal vena cava. It is normal in appearance (uniformly hypoechoic) and shape with no evidence of a mass effect.

**REFERRING VET**

Dr. Kable

**Spleen**

The spleen is subjectively normal in size The spleen echotexture is heterogenous and mottled, the splenic capsule is smooth with no irregularities. The blood flow through the hilus and splenic parenchyma appears normal. There is a hypoechoic, discrete mass effect that measured 1.95 x 1.24 cm towards the tail end of the spleen.

**INVOICE**

92205

### **Liver**

The liver is subjectively large in size, and echogenicity with smooth peripheral margins. The parenchyma is heterogenous in echotexture with subtle, indistinct focal mottling. The visible portions of the vasculature and biliary tract appear normal. No focal nodules or cystic lesions are observed. The gallbladder lumen is moderately distended. The wall of the gallbladder is not thickened and has a relatively smooth mucosal surface. There is a moderate amount of hypoechoic debris within the gallbladder, which is starting to organize and create striations. The cystic and common bile ducts are normal/not visible. The findings are consistent with an emerging gallbladder mucocele.

### **Gastrointestinal**

The stomach contains minimal luminal contents. It measures at a normal thickness of <0.7cm with some variability due to the presence of rugal folds. The distinction of the gastric wall layers is adequate and there is no impression of reduced peristaltic activity. No masses or focal lesions were observed.

The visualized areas of duodenum, jejunum and ileum have a relatively uniform diameter with minimal fluid distension. Wall thickness is normal. Bowel loops follow a curvilinear path with distinct wall layering maintaining the typical 1:3 muscularis:mucosa layer ratio. The duodenum measured as normal and the jejunum measured as normal (0.29 cm). Visualized peristalsis appears appropriate. There were no focal lesions consistent with obstruction or a mass effect observed.

The ileocecal junction was visualized and exhibited normal intact wall layering and is subjectively of normal thickness. Sections of colon are visualized with formed fecal material and gas shadowing distally. There is no observed focal or generalized colon wall thickening or loss of layering.

### **Pancreas**

The pancreas is prominent and mottled compared to the surrounding isoechoic mesentery. There is no evidence of nodules or cystic lesions. There is no evidence of regional mesenteric inflammation or fluid.

### **Free Abdomen**

Evaluation of the peritoneal cavity did not reveal any evidence of effusion, or subjective lymphadenomegaly. The Medial iliac nodes appear normal and there was no evidence of a caudal aortic thrombus at the bifurcation. The omentum is of normal uniform echogenicity.

## **ULTRASONOGRAPHIC FINDINGS**

### **PRIMARY FINDINGS:**

- Hypoechoic splenic mass. The mass distorts the splenic capsule. Differentials for the mass include neoplasia (hemangiosarcoma, hemangioma), hematoma, abscess, other.
- Large heterogenous liver. The liver is subjectively normal in size, and echogenicity with smooth peripheral margins. The parenchyma is heterogenous in echotexture with subtle, indistinct focal mottling. The visible portions of the vasculature and biliary tract appear normal. No focal nodules or cystic lesions are observed.
- Gallbladder debris with early organization. This is consistent with emerging mucocele.
- Borderline bilateral adrenomegaly. The bilateral adrenomegaly could be consistent with bilateral hyperplasia (e.g., secondary to pituitary-dependent hyperadrenocorticism), bilateral infiltrative neoplasia, inflammatory adrenal disease, other. Correlation with clinical findings is recommended.

## SECONDARY FINDINGS:

- Prominent, mottled pancreas. The pancreatic changes are most consistent with age-related parenchymal remodeling, potentially secondary to a prior inflammatory episode, early fibrosis or chronic pancreatitis.
- Non-obstructive nephroliths visualized in both kidneys. The hyperechoic mineralized foci observed at the corticomedullary junction of the left/right kidney are consistent with small, non-obstructive nephroliths.

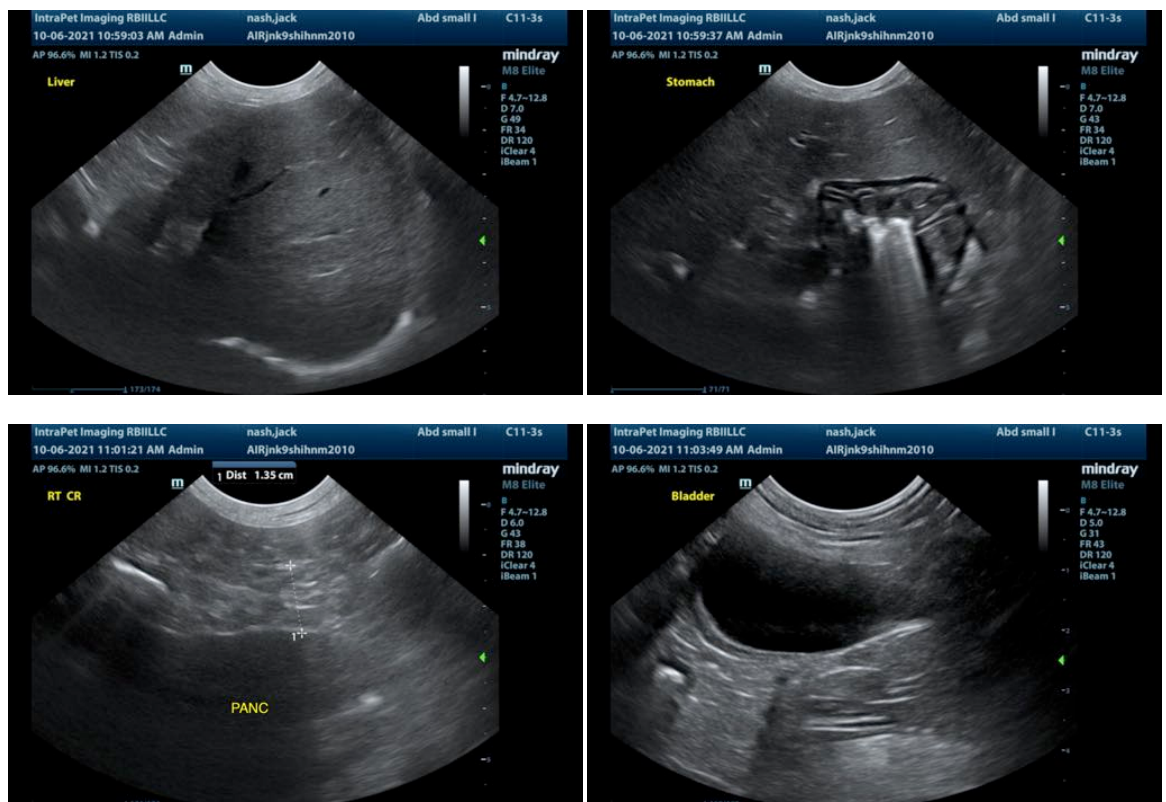
## INTERPRETATION OF THE FINDINGS & FURTHER RECOMMENDATIONS

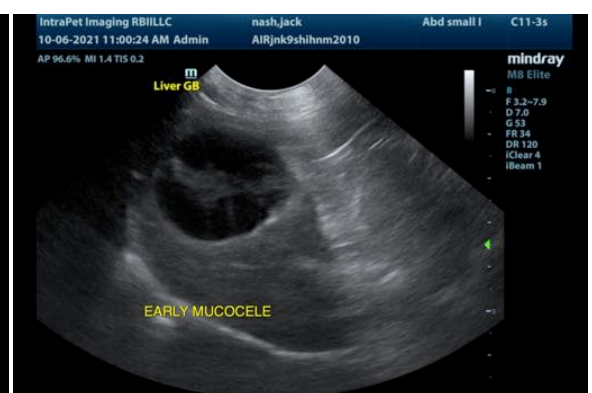
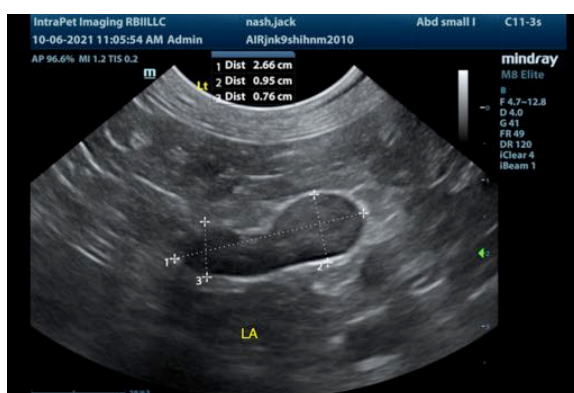
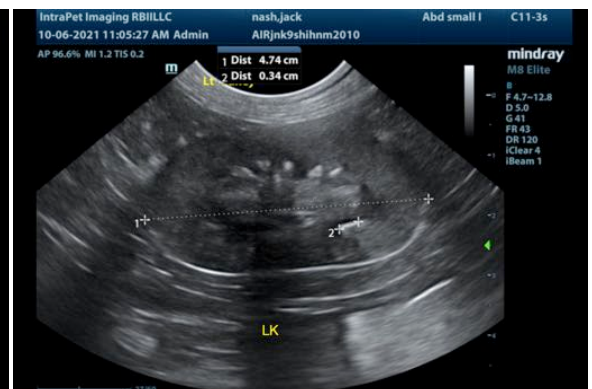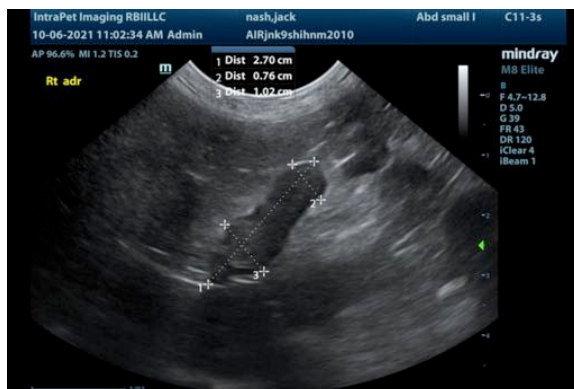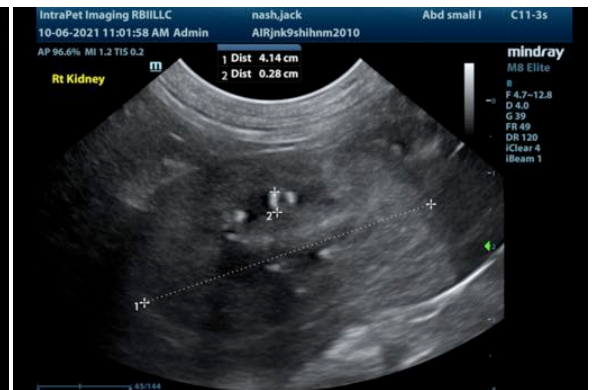
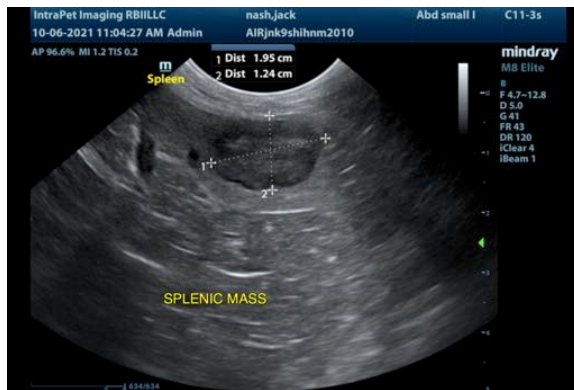Many of the findings on today's scan may be consistent with a diagnosis of pituitary dependent Cushing's disease including bilateral adrenomegaly and a large, heterogenous liver. I recommend a liver function test, adrenal function testing if clinical signs are appropriate +/- a FNA of the liver.

Additionally, there is a mass in the spleen. Ideally, I would recommend a splenectomy for both therapeutic and diagnostic purposes. Alternatively, you can consider a FNA. I recommend three view thoracic radiographs.

The gallbladder appears relatively healthy, but does have organized debris with the early appearance of mucocele. Consider starting Ursodiol and close monitoring of the gallbladder as this may have something to do with the liver enzyme elevation as well.

I recommend pathologist review of the CBC to evaluate the lymphocytosis reported. If splenectomy is pursued then consider liver biopsy at the same time.





The information and recommendations provided are based on the images presented by the referring veterinarian. No evaluation can be communicated regarding pathology that was not visible in the image/video clips provided.

Thank you for this referral. If the clinical or image interpretation does not parallel your findings or if I can be of any further assistance please contact me.

Kathleen Sennello DVM,MS, Diplomate ACVIM (Small animal Internal Medicine)  
 kathleen.sennello@sonopath.com