



PATIENT

Max Wexler

SPECIES

Canine

BREED

Havanese

SEX

Neutered male

AGE

12/9/19

WEIGHT

10.6 lbs

INTERPRETED BY

Kathleen Sennello
DVM, MS, Diplomate
ACVIM (Small Animal
Internal Medicine)

IMAGING PERFORMED BY

Anthony Smatt

HOSPITAL NAME

The Pets I Love

REFERRING VET

Dr. Szpicek

INVOICE

92165

DATE

10/5/21

PRESENTING CLINICAL SIGNS

History: patient has history of occasional vomiting, bloating and inappetence. patient is BAR on visits. r/o IBD, Dietary, Other patient is now on hydrolyzed diet.
Abnormal PE/Chem/CBC/UA Results: cPLI - normal elevated eosinophils and monocytes is the only bw abnormality

ULTRASONOGRAPHIC EXAMINATION OF THE ABDOMEN

Urinary System

The urinary bladder is moderately distended with anechoic urine. The Bladder wall, trigone, ureteral papillae and visible urethra (to a depth of 2cm) appear normal with no evidence of wall thickening, mucosal irregularities, masses or cystic calculi.

The prostate is normal in size (0.98 cm) and shape for this neutered male dog. The parenchyma is homogenous and the external margins are smooth. The prostatic urethra appears normal with no evidence of irregularity, invasion, mass effect or calculi.

The left kidney has a normal shape and size (3.99 cm). Overall echogenicity is normal with adequate corticomedullary distinction and a typical 1:3 cortex:medulla ratio. There is no evidence of perinephric inflammation or effusion. There is no evidence of pyelectasia, nephroliths, infarcts or hydroureter. Renal vasculature is normal.

The right kidney has a normal shape and size (3.7 cm). Overall echogenicity is normal with adequate corticomedullary distinction and a typical 1:3 cortex:medulla ratio. There is no evidence of perinephric inflammation or effusion. There is no evidence of pyelectasia, nephroliths, infarcts or hydroureter. Renal vasculature is normal.

Adrenal Glands

The left adrenal gland is normal in size measuring 0.3 cm at the caudal pole It is observed in its normal position cranial to the left renal artery. It is normal in appearance (uniformly hypoechoic) and shape with no evidence of a mass effect.

The right adrenal gland is normal in size measuring 0.45 cm at the caudal pole It is observed in its normal position between the cranial aspect of the right kidney and the caudal vena cava. It is normal in appearance (uniformly hypoechoic) and shape with no evidence of a mass effect.

Spleen

The spleen is subjectively normal in size, echotexture is homogenous, and the splenic capsule is smooth with no irregularities. The blood flow through the hilus and splenic parenchyma appears normal. No focal parenchymal abnormalities are visualized.

Liver

The liver is subjectively normal in size, and echogenicity with smooth peripheral margins. The parenchyma is homogenous echotexture. The visible portions of the vasculature and biliary tract appear



PATIENT

Max Wexler

normal. No focal nodules or cystic lesions are observed. The gallbladder lumen is moderately distended. The wall of the gall bladder is not thickened and has a smooth mucosal surface. Luminal contents are primarily anechoic. The cystic and common bile ducts are normal/not visible.

SPECIES

Canine

Gastrointestinal

The stomach contains minimal luminal contents. It measures at a normal thickness of <0.7cm with some variability due to the presence of rugal folds. The distinction of the gastric wall layers is adequate and there is no impression of reduced peristaltic activity. No masses or focal lesions were observed.

BREED

Havenese

The visualized areas of duodenum, jejunum and ileum have a uniform diameter with minimal fluid distension. Wall appears subjectively, mildly increased. The duodenum measured 0.37 cm and the jejunum measured 0.26 cm. Bowel loops follow a typical curvilinear path with distinct wall layering. Additionally an area of bowel was visualized with some mild, mucosal speckling. Visualized peristalsis appears appropriate. There were no focal lesions consistent with obstruction or a mass effect observed

SEX

Neutered male

The ileocecal junction was visualized and exhibited normal intact wall layering and is subjectively of normal thickness. Sections of colon are visualized with formed fecal material and gas shadowing distally. There is no observed focal or generalized colon wall thickening or loss of layering.

AGE

12/9/19

WEIGHT

10.6 lbs

Pancreas

The pancreas is normal and isoechoic to surrounding mesentery. There is no evidence of nodules or cystic lesions. There is no evidence of regional mesenteric inflammation or fluid.

INTERPRETED BY

Kathleen Sennello
DVM, MS, Diplomate
ACVIM (Small Animal
Internal Medicine)

Free Abdomen

Evaluation of the peritoneal cavity did not reveal any evidence of effusion, or subjective lymphadenomegaly. The Medial iliac nodes appear normal and there was no evidence of a caudal aortic thrombus at the bifurcation. The omentum is of normal uniform echogenicity.

IMAGING PERFORMED BY

Anthony Smatt

ULTRASONOGRAPHIC FINDINGS

HOSPITAL NAME

The Pets I Love

PRIMARY FINDINGS:

- Subjective, small intestinal thickening with mild mucosal speckling. Bright mucosal speckling has been proposed to represent dilated lacteals or focal accumulation of mucus, cellular debris etc. in the mucosal crypts of the small intestine.

REFERRING VET

Dr. Szpicek

SECONDARY FINDINGS:

INVOICE

92165

INTERPRETATION OF THE FINDINGS & FURTHER RECOMMENDATIONS

The ultrasonographic changes observed in the bowel were relatively mild. Unfortunately many causes for vomiting and inappetence cannot be definitively diagnosed by ultrasound alone. No focal bowel lesions are observed.

DATE

10/5/21



PATIENT

Max Wexler

- Consider metabolic causes based on bloodwork, ACTH stim results (especially because of the eosinophilia reported), liver function testing, Gi panel (TLI/PLI, folate, cobalamin.)
- Consider primary GI causes: GI parasitism, dietary indiscretion, mild pancreatitis, bacterial dysbiosis, food allergy, IBD and less likely intestinal neoplasia.

SPECIES

Canine

This is a young dog so differentials such as intestinal neoplasia and IBD are less likely. Provided metabolic causes are ruled out consider GI parasitism, dietary hypersensitivity, periodic dietary indiscretion and congenital issues such as congenital lymphangectasia, etc. I recommend diet trial with novel protein/hydrolyzed protein diet (this has already been started).

BREED

Havenese

- I recommend a GI panel (PLI, TLI, cobalamin and folate) to look for evidence of dysbiosis, pancreatitis, B12 deficiency, etc.

SEX

Neutered male

- I recommend starting a probiotic.
- If symptoms persist despite reasonable efforts to rule out systemic disease consider GI biopsies.

AGE

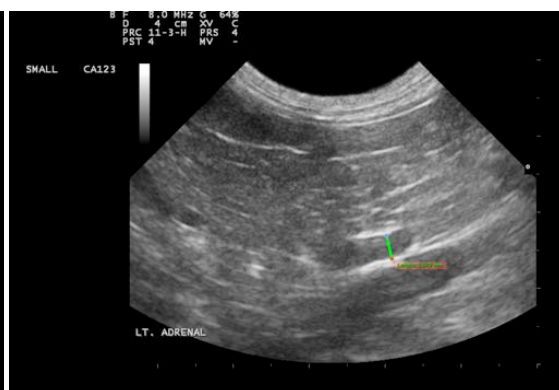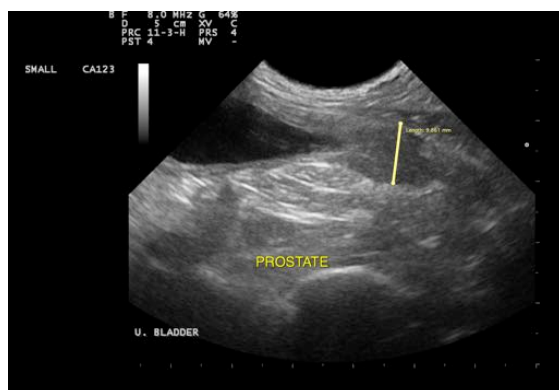
12/9/19

WEIGHT

10.6 lbs

INTERPRETED BY

Kathleen Sennello
DVM, MS, Diplomate
ACVIM (Small Animal
Internal Medicine)

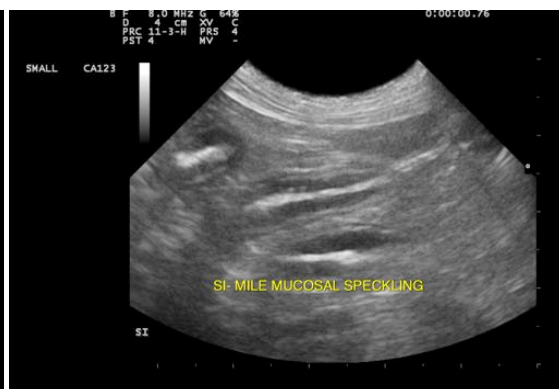
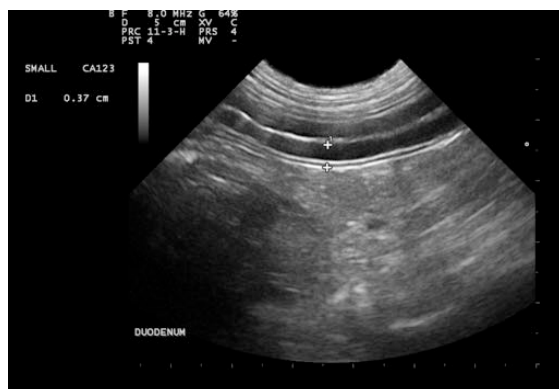
IMAGING PERFORMED BY

Anthony Smatt

HOSPITAL NAME

The Pets I Love



REFERRING VET

Dr. Szpicek

INVOICE

92165

DATE

10/5/21



PATIENT

Max Wexler

SPECIES

Canine

BREED

Havnese

SEX

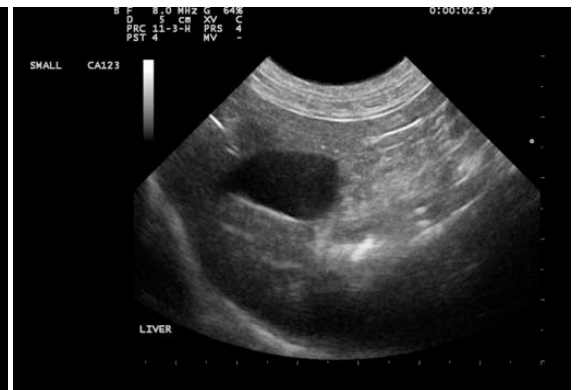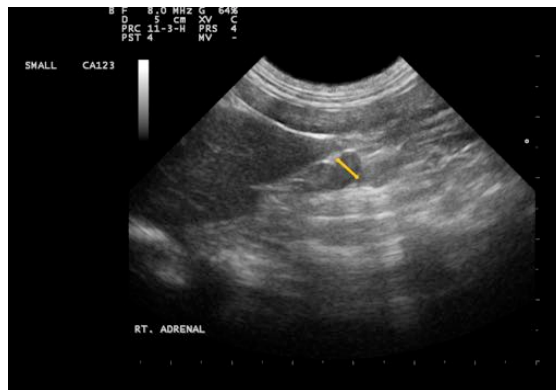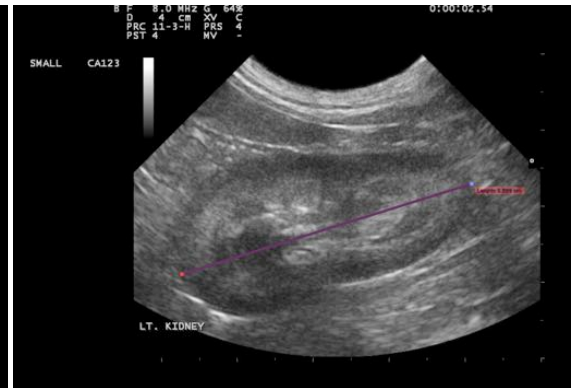
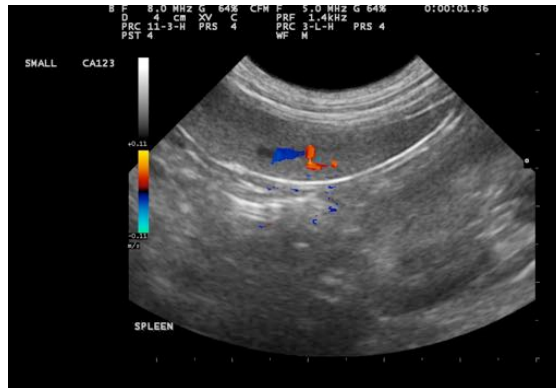
Neutered male

AGE

12/9/19

WEIGHT

10.6 lbs



INTERPRETED BY

Kathleen Sennello
DVM, MS, Diplomate
ACVIM (Small Animal
Internal Medicine)

IMAGING PERFORMED BY

Anthony Smatt

HOSPITAL NAME

The Pets I Love

REFERRING VET

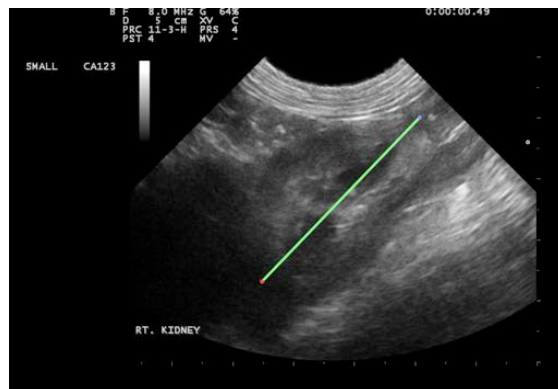
Dr. Szpicek

INVOICE

92165

DATE

10/5/21



The information and recommendations provided are based on the images presented by the referring veterinarian. No evaluation can be communicated regarding pathology that was not visible in the image/video clips provided.

Thank you for this referral. If the clinical or image interpretation does not parallel your findings or if I can be of any further assistance please contact me.

Kathleen Sennello DVM,MS, Diplomate ACVIM (Small animal Internal Medicine)
kathleen.sennello@sonopath.com