



PATIENT

Dungy Williams

SPECIES

Canine

BREED

Terrier Mix

SEX

Neutered male

AGE

14 years

WEIGHT

52.5 lbs

INTERPRETED BY

Kathleen Sennello
DVM, MS, Diplomate
ACVIM (Small Animal
Internal Medicine)

**IMAGING
PERFORMED BY**

Dr. Harris

HOSPITAL NAME

TotalBond VH-Bethel

REFERRING VET

Dr. Werfal

INVOICE

92173

DATE

10/5/21

PRESENTING CLINICAL SIGNS

History: 14yo MN Terrier mix that presented for annual exam in August 2021 and wellness labwork evaluated. Pt was found to have a high ALT- 173 and ALP- 377 (results attached). Also found low T4, which is historical and evaluated years prior with FT4 which was normal. Patient was then on Apoquel and Galliprant for OA as needed. Apoquel was discontinued and ALT re-evaluated on 9/10/2021. ALT was 234. Patient was then placed on Amoxicillin, Metronidazole, and Denamarin for 2 weeks. ALT was re-evaluated on 10/1 and was 241. Patient has history of heart murmur, so was only given Butorphanol for ultrasound.

ULTRASONOGRAPHIC EXAMINATION OF THE ABDOMEN

Urinary System

The urinary bladder is moderately distended with anechoic urine. The Bladder wall, trigone, ureteral papillae and visible urethra (to a depth of 2cm) appear normal with no evidence of wall thickening, mucosal irregularities, masses or cystic calculi.

The visualized areas of prostate and surrounding tissue appear normal. Unfortunately, the prostate is not fully visualized likely due to its intrapelvic location. Correlate with rectal exam findings.

The left kidney has a normal shape and size (6.49 cm). Overall echogenicity is normal with adequate corticomedullary distinction and a typical 1:3 cortex:medulla ratio. There is no evidence of perinephric inflammation or effusion. There is no evidence of pyelectasia, nephroliths, infarcts or hydronephrosis. Renal vasculature is normal.

The right kidney has a normal shape and size (7.48 cm). Overall echogenicity is normal with adequate corticomedullary distinction and a typical 1:3 cortex:medulla ratio. There is no evidence of perinephric inflammation or effusion. There is no evidence of pyelectasia, nephroliths, infarcts or hydronephrosis. Renal vasculature is normal.

Adrenal Glands

The left adrenal gland is normal in size measuring 1.65 cm at the caudal pole. It is observed in its normal position cranial to the left renal artery. It is normal in appearance (uniformly hypoechoic) and shape with no evidence of a mass effect.

The region of the right adrenal (between right cranial kidney and vena cava) is unremarkable, but the adrenal is not distinctly visualized. No evidence of a mass effect.

Spleen

The spleen is subjectively normal in size. The spleen echotexture is heterogenous and mottled, the splenic capsule is smooth with no irregularities. The blood flow through the hilus and splenic parenchyma appears normal. There is a heterogenous 2.38 cm solid nodule visualized which deviates the splenic capsule.



PATIENT

Liver

Dungy Williams

The liver is subjectively normal in size, and echogenicity with smooth peripheral margins. The parenchyma is heterogenous in echotexture with subtle, indistinct focal mottling. The visible portions of the vasculature and biliary tract appear normal. There is a 1.0 cm hyperechoic nodule visualized in the parenchyma. The gallbladder lumen is moderately distended. The wall of the gallbladder is not thickened and has a smooth mucosal surface. Luminal contents are primarily anechoic. The cystic and common bile ducts are normal/not visible.

SPECIES

Canine

BREED

Terrier Mix

Gastrointestinal

The stomach contains minimal luminal contents. It measures at a normal thickness of <0.7cm with some variability due to the presence of rugal folds. The distinction of the gastric wall layers is adequate and there is no impression of reduced peristaltic activity. No masses or focal lesions were observed.

SEX

Neutered male

The visualized areas of duodenum, jejunum and ileum have a relatively uniform diameter with minimal fluid distension. Wall thickness is normal. Bowel loops follow a curvilinear path with distinct wall layering maintaining the typical 1:3 muscularis:mucosa layer ratio. The duodenum measured as normal (0.5 cm) and the jejunum measured as normal (0.28 cm). Visualized peristalsis appears appropriate. There were no focal lesions consistent with obstruction or a mass effect observed.

AGE

14 years

The ileocecal junction was visualized and exhibited normal intact wall layering and is subjectively of normal thickness. Sections of colon are visualized with formed fecal material and gas shadowing distally. There is no observed focal or generalized colon wall thickening or loss of layering.

WEIGHT

52.5 lbs

INTERPRETED BY

Pancreas

Kathleen Sennello
DVM, MS, Diplomate
ACVIM (Small Animal
Internal Medicine)

The pancreas is normal and isoechoic to surrounding mesentery. There is no evidence of nodules or cystic lesions. There is no evidence of regional mesenteric inflammation or fluid.

IMAGING PERFORMED BY

Free Abdomen

Dr. Harris

Evaluation of the peritoneal cavity did not reveal any evidence of effusion, or subjective lymphadenomegaly. The Medial iliac nodes appear normal and there was no evidence of a caudal aortic thrombus at the bifurcation. The omentum is of normal uniform echogenicity.

HOSPITAL NAME

TotalBond VH-Bethel

ULTRASONOGRAPHIC FINDINGS

PRIMARY FINDINGS:

REFERRING VET

Dr. Werfal

- Mildly mottled spleen with mixed echogenicity nodule. There is a non-cavitated, hypoechoic splenic nodule visualized. Differentials include lymphoid hyperplasia, extramedullary hematopoiesis, infiltrative neoplasia, inflammation, other. Cytology or histopathology would be necessary to get a definitive diagnosis

INVOICE

92173

- Heterogenous liver with hyperechoic nodule. The diffuse hepatic changes are non-specific and could be consistent with vacuolar hepatopathy, nodular hyperplasia, inflammatory/immune-mediated disease, fibrosis, extramedullary hematopoiesis, toxic hepatopathy (e.g., copper), infiltrative neoplasia (less likely) or other hepatopathy.

DATE

10/5/21



PATIENT

Dungy Williams

SPECIES

Canine

BREED

Terrier Mix

SEX

Neutered male

AGE

14 years

WEIGHT

52.5 lbs

INTERPRETED BY

Kathleen Sennello
DVM, MS, Diplomate
ACVIM (Small Animal
Internal Medicine)

IMAGING PERFORMED BY

Dr. Harris

HOSPITAL NAME

TotalBond VH-Bethel

REFERRING VET

Dr. Werfal

INVOICE

92173

DATE

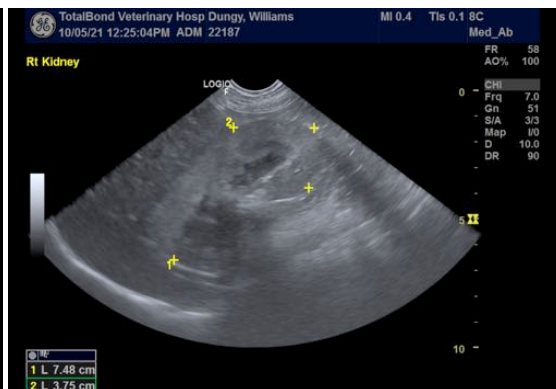
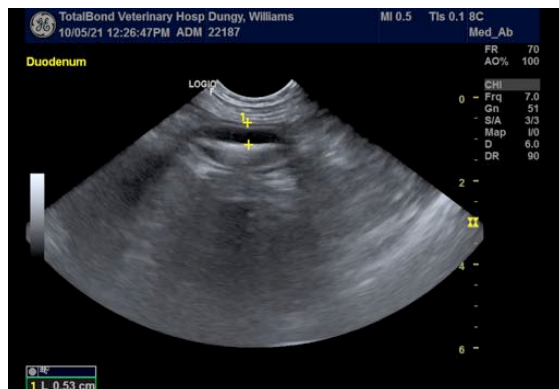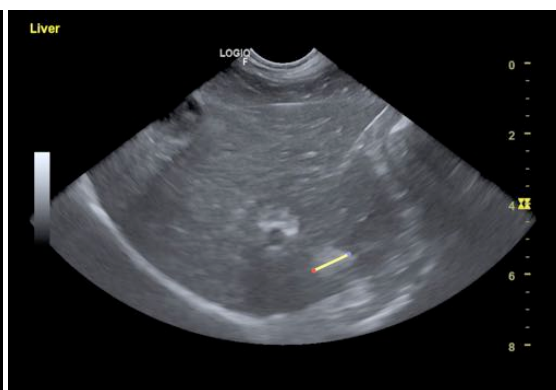
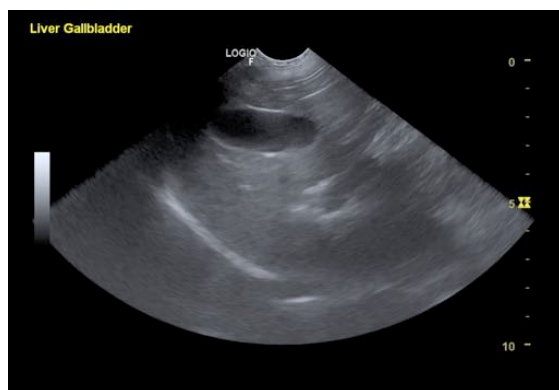10/5/21

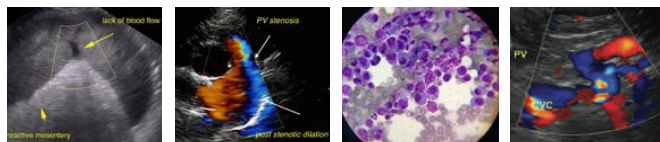
INTERPRETATION OF THE FINDINGS & FURTHER RECOMMENDATIONS

The ultrasonographic changes in the liver were relatively mild. Unfortunately, the sonographic changes do not always reflect the severity or cause of the hepatopathy. The scan today supports a primary hepatopathy as no severe biliary changes were observed.

- Consider close evaluation of history for possible toxic changes examine medications, diet, dietary indiscretion etc...
- Consider PCR on urine/serum for leptospirosis (if not on antibiotics)/serology if recent antibiotic history
- If not already done, consider pre and post prandial bile acids to evaluate liver function
- If the ALP is significantly elevated relative to the ALT and symptoms consistent with Cushing's are present, consider adrenal function testing (ACTH stim)
- Consider Fine needle aspirate if round cell neoplasia is on your differentialia list (25 g needle, normal coags)
- If no response to supportive medications (Denamarin, antibiotics,+/- Ursodiol etc...) Consider liver biopsy with samples obtained for histopathology, culture, and copper levels.

Additionally there is a splenic nodule present. This could be a benign or cancerous lesion. Consider FNA and continue close monitoring as this is on the edge of the spleen and regardless of the type of lesion is still a risk for rupture at some point. If surgical liver biopsies are ever considered then I recommend splenectomy. I recommend three view thoracic radiographs.





PATIENT

Dungy Williams

SPECIES

Canine

BREED

Terrier Mix

SEX

Neutered male

AGE

14 years

WEIGHT

52.5 lbs

INTERPRETED BY

Kathleen Sennello
DVM, MS, Diplomate
ACVIM (Small Animal
Internal Medicine)

IMAGING PERFORMED BY

Dr. Harris

HOSPITAL NAME

TotalBond VH-Bethel

REFERRING VET

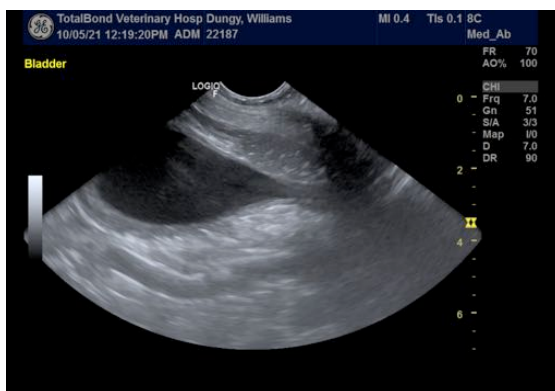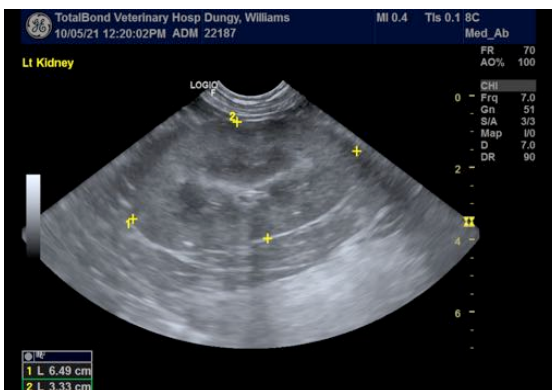
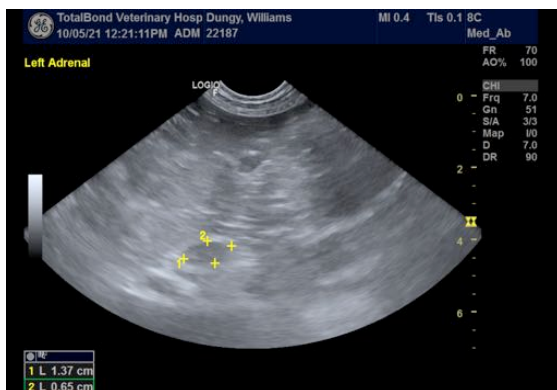
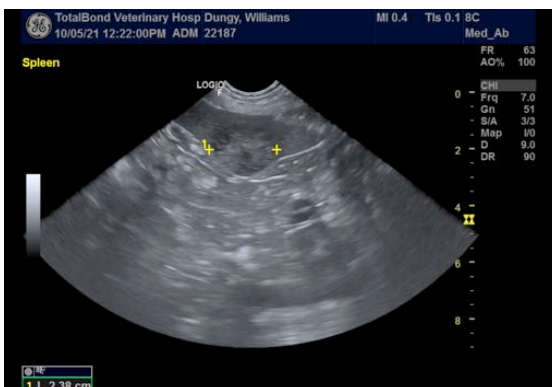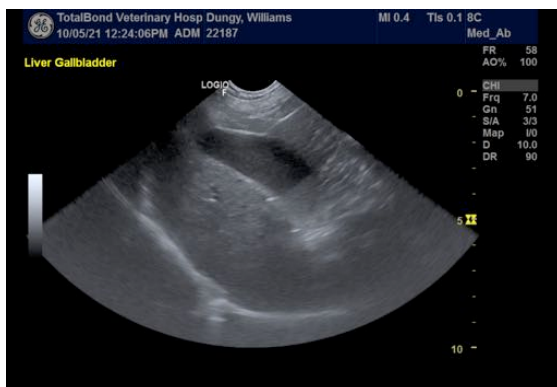
Dr. Werfal

INVOICE

92173

DATE

10/5/21



The information and recommendations provided are based on the images presented by the referring veterinarian. No evaluation can be communicated regarding pathology that was not visible in the image/video clips provided.

Thank you for this referral. If the clinical or image interpretation does not parallel your findings or if I can be of any further assistance please contact me.

Kathleen Sennello DVM,MS, Diplomate ACVIM (Small animal Internal Medicine)
kathleen.sennello@sonopath.com