

IMAGING PERFORMED BY

IntraPet.com



**SonoPath**

Clinical Sonography & Telectology

EDUCATIONAL TELECONSULTATION SERVICES™

1-800-838-4268 info@sonopath.com SonoPath.com

**DATE PRESENTING CLINICAL SIGNS**

10/4/22 Episodic vomiting, anorexia since a puppy. Episodes happen several times per year and often result in hospitalization for supportive care. Chronic tenesmus that is currently better on metoclopramide. History of severe skin allergies.

**PATIENT**

Coco Christman Current Medications: Atopica 50mg once daily, Metoclopramide 1/4 tab BID, Welactin, Incurin, Visbiome, Dasuquin, Cytopoint

**SPECIES**

Canine

Lab Results: Most recent labs 9/15 during a GI episode had cholesterol of 80 and low normal albumin of 2.9 (may be transient, recheck labs pending).

Date of Previous IntraPet Ultrasound: No previous.

Sedation: Not required to complete full diagnostic ultrasound.

Stat Report: Not requested.

**BREED**

French Bulldog

**ULTRASONOGRAPHIC EXAMINATION OF THE ABDOMEN**

**SEX**

Spayed Female

**Urinary System**

The urinary bladder is moderately distended with anechoic urine. The Bladder wall, trigone, ureteral papillae and visible urethra (to a depth of 2cm) appear normal with no evidence of wall thickening, mucosal irregularities, masses or cystic calculi.

**AGE**

2/25/17

The left kidney has a normal shape and size (4.54 cm). Overall echogenicity is normal with adequate corticomedullary distinction and a typical 1:3 cortex:medulla ratio. There is no evidence of focal perinephric inflammation or effusion. There is no evidence of pyelectasia, nephroliths, infarcts or hydroureter. Renal vasculature is normal.

**WEIGHT**

10.4 kg

The right kidney has a normal shape and size (4.38 cm). Overall echogenicity is normal with adequate corticomedullary distinction and a typical 1:3 cortex:medulla ratio. There is no evidence of focal perinephric inflammation or effusion. There is no evidence of pyelectasia, nephroliths, infarcts or hydroureter. Renal vasculature is normal.

**INTERPRETED BY**

Kathleen Sennello DVM, MS, Diplomate ACVIM (Small Animal Internal Medicine)

**Adrenal Glands**

The left adrenal gland is normal in size measuring 0.57 cm at the caudal pole. It is observed in its normal position cranial to the left renal artery. It is normal in appearance (uniformly hypoechoic) and shape with no evidence of a mass effect.

**IMAGING PERFORMED BY**

Andi Parkinson RDMS

The right adrenal gland is normal in size measuring 0.61 cm at the caudal pole. It is observed in its normal position between the cranial aspect of the right kidney and the caudal vena cava. It is normal in appearance (uniformly hypoechoic) and shape with no evidence of a mass effect.

**HOSPITAL NAME**

Nexus Vet Specialists

**Spleen**

The spleen is subjectively normal in size, echotexture is homogenous, and the splenic capsule is smooth with no irregularities. The blood flow through the hilus and splenic parenchyma appears normal. No focal parenchymal abnormalities are visualized.

**REFERRING VET**

Dr. Steele

**Liver**

The liver is subjectively normal in size, and echogenicity with smooth peripheral margins. The parenchyma is homogenous echotexture. The visible portions of the vasculature and biliary tract appear normal. No focal nodules or cystic lesions are observed.

**INVOICE**

40930

The gallbladder lumen is moderately distended. The wall of the gall bladder is not thickened and has a smooth mucosal surface. Luminal contents are mild and primarily anechoic. The cystic and common bile ducts are normal/not visible.

### ***Gastrointestinal***

The stomach contains minimal luminal contents. It measures at a normal thickness of <0.7cm with some variability due to the presence of rugal folds. The distinction of the gastric wall layers is adequate and there is no impression of reduced peristaltic activity. No masses or focal lesions were observed.

The visualized areas of duodenum, jejunum and ileum have a relatively uniform diameter with minimal fluid distension. Wall thickness is normal. Bowel loops follow a curvilinear path with distinct wall layering maintaining the typical 1:3 muscularis:mucosa layer ratio. Jejunum wall measures 0.42 cm. Visualized peristalsis appears appropriate. There were no focal lesions consistent with obstruction or a mass effect observed.

The ileocecal junction was visualized and exhibited normal intact wall layering and is subjectively of normal thickness. Sections of colon are visualized with formed fecal material and gas shadowing distally. There is no observed focal or generalized colon wall thickening or loss of layering.

### ***Pancreas***

The pancreas is normal and isoechoic to surrounding mesentery. There is no evidence of nodules or cystic lesions. There is no evidence of regional mesenteric inflammation or fluid.

### ***Free Abdomen***

Evaluation of the peritoneal cavity did not reveal any evidence of effusion, or subjective lymphadenomegaly. The Medial iliac nodes appear normal and there was no evidence of a caudal aortic thrombus at the bifurcation. The omentum is of normal uniform echogenicity.

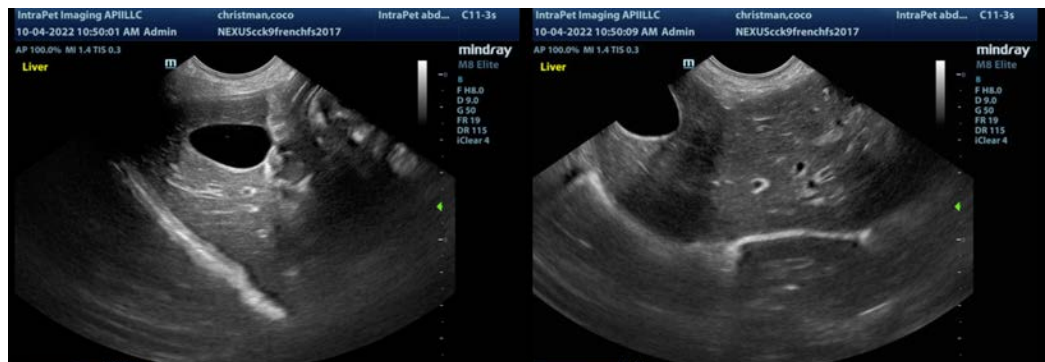
## **ULTRASONOGRAPHIC FINDINGS**

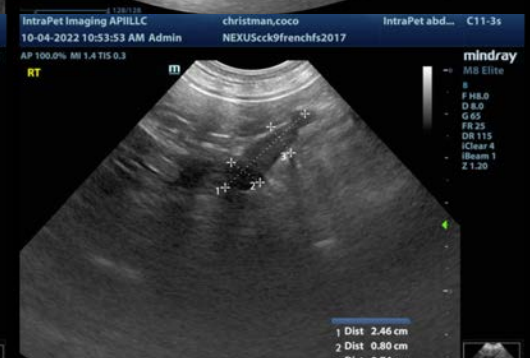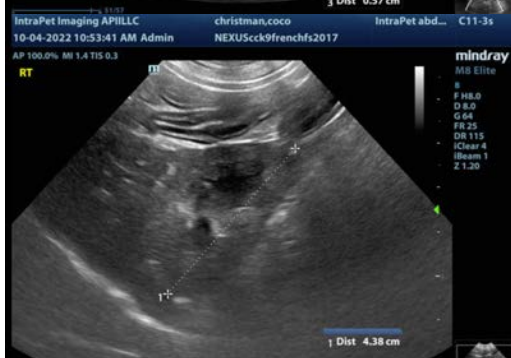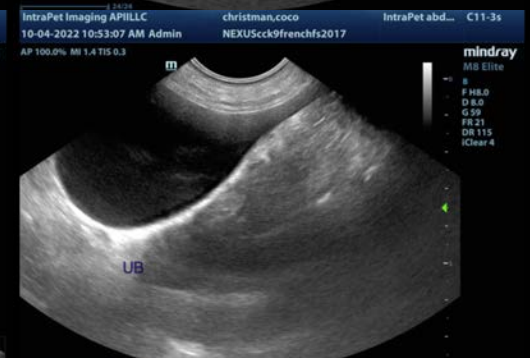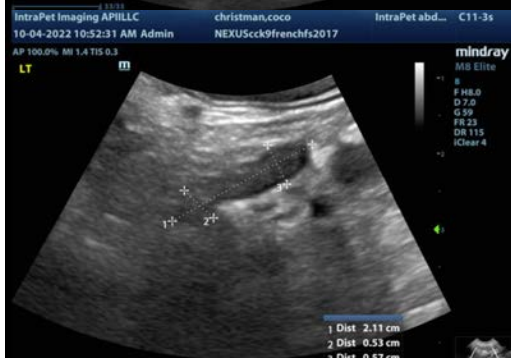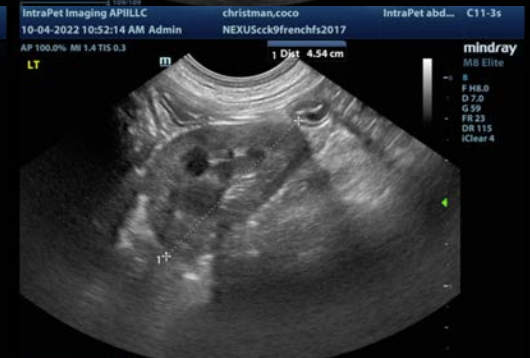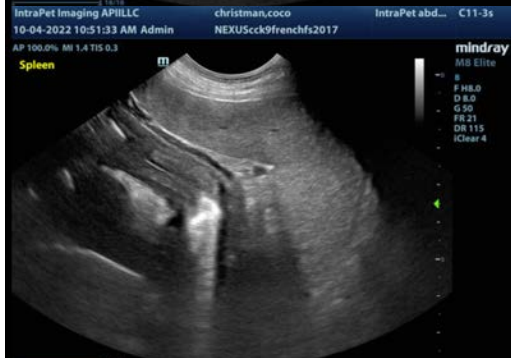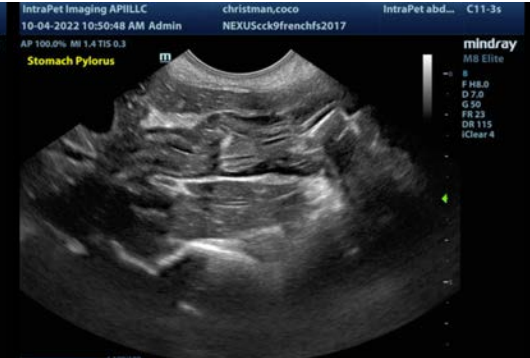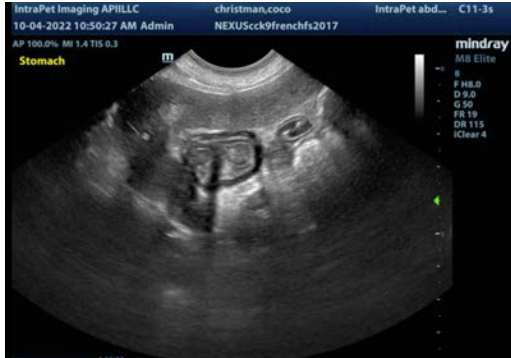- No significant ultrasonographic findings visualized

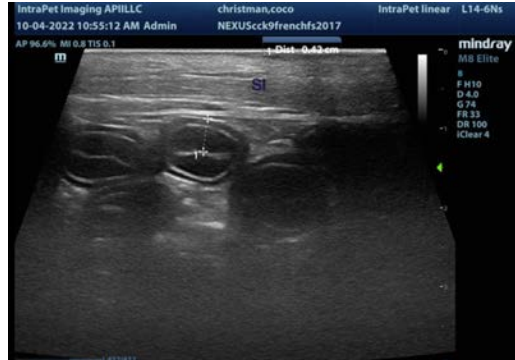## **INTERPRETATION OF THE FINDINGS & FURTHER RECOMMENDATIONS**

No focal lesions visualized associated with the gastrointestinal tract.

Further diagnostic and therapeutic recommendations regarding this exam to be made by Dr. Cara Steele.







**The information and recommendations provided are based on the images presented by the referring veterinarian/sonographer. No evaluation can be communicated regarding pathology that was not visible in the image/video clips provided.**

Thank you for this referral. If the clinical or image interpretation does not parallel your findings or if I can be of any further assistance please contact me.

Kathleen Sennello DVM,MS, Diplomate ACVIM (Small animal Internal Medicine)  
kathleen.sennello@sonopath.com