

**DATE PRESENTING CLINICAL SIGNS**

10/28/22 Having "episodes" - possible seizure activity. Will just scream out of nowhere. Happens when asleep. Or maybe awake but she will go to sleep afterwards. Obese, distended abdomen.

**PATIENT**

Pixie Cantler

Current Medications: None.

Lab Results: Mild elevated Ca<sup>++</sup> ionized not performed. Elevated AP.

Date of Previous IntraPet Ultrasound: No previous.

Sedation: Not required to complete full diagnostic ultrasound.

Stat Report: Not requested.

**SPECIES**

Canine

**ULTRASONOGRAPHIC EXAMINATION OF THE ABDOMEN****BREED**

Shih Tzu

**Urinary System**

The urinary bladder is mildly distended with anechoic urine. The Bladder wall is diffusely mildly thickened (0.35 cm), and the mucosa is mildly irregular. The trigone, ureteral papillae, and visible urethra (to a depth of 2cm) appear normal with no evidence of severe mucosal irregularities, or masses. There is a small amount of hyperechoic shadowing material in the dependent portion of the urinary bladder, most consistent with a small amount of sandy mineralized debris. Findings are most consistent with bacterial cystitis or lack of urine distension. Recommend urinalysis and culture.

**AGE**

7/18/14

The left kidney has a normal shape and size (3.81 cm). Overall echogenicity is slightly hyperechoic with poor corticomedullary distinction and a typical 1:3 cortex:medulla ratio. There is no evidence of focal perinephric inflammation or effusion. There is no evidence of pyelectasia, nephroliths, infarcts or hydroureter. Renal vasculature is normal.

**WEIGHT**

13.1 Pounds

The right kidney has a normal shape and size (4.11 cm). Overall echogenicity is slightly hyperechoic with poor corticomedullary distinction and a typical 1:3 cortex:medulla ratio. There is no evidence of focal perinephric inflammation or effusion. There is no evidence of pyelectasia, nephroliths, infarcts or hydroureter. Renal vasculature is normal.

**INTERPRETED BY**

Kathleen Sennello DVM,  
MS, Diplomate ACVIM  
(Small Animal Internal  
Medicine)

**Adrenal Glands**

The left adrenal gland is normal in size measuring 0.75 cm at the caudal pole. It is observed in its normal position cranial to the left renal artery. It is normal in appearance (uniformly hypoechoic) and shape with no evidence of a mass effect.

**IMAGING PERFORMED BY**

Stephanie Warga  
RDMS, RVT

The right adrenal gland is normal in size measuring 0.59 cm at the caudal pole. It is observed in its normal position between the cranial aspect of the right kidney and the caudal vena cava. It is normal in appearance (uniformly hypoechoic) and shape with no evidence of a mass effect.

**HOSPITAL NAME**

Festival Vet Clinic

**Spleen**

The spleen is subjectively normal in size, echotexture is homogenous, and the splenic capsule is smooth with no irregularities. The blood flow through the hilus and splenic parenchyma appears normal. No focal parenchymal abnormalities are visualized.

**REFERRING VET**

Dr. Cianelli

**Liver**

The liver is large in size, and normal in echogenicity with smooth peripheral margins. The parenchyma is heterogenous in echotexture with subtle, indistinct focal mottling. The visible portions of the vasculature and biliary tract appear normal. No focal nodules or cystic lesions are observed.

**INVOICE**

42470

The gall bladder lumen is significantly distended. Some areas of the wall appear mildly thickened with adherent debris and some areas have early mucosal stranding and organization of the debris into an early

mucocele. There is a large amount of primarily non-organized echogenic debris present as well. There is no evidence of bile duct dilation.

### ***Gastrointestinal***

The stomach contains minimal luminal contents. It measures at a normal thickness of <0.7cm with some variability due to the presence of rugal folds. The distinction of the gastric wall layers is adequate and there is no impression of reduced peristaltic activity. No masses or focal lesions were observed.

The visualized areas of duodenum, jejunum and ileum have a relatively uniform diameter with minimal fluid distension. Wall thickness is normal. Bowel loops follow a curvilinear path with distinct wall layering maintaining the typical 1:3 muscularis:mucosa layer ratio. Jejunum wall measures 0.29 cm. Duodenum wall measures 0.33 cm. Visualized peristalsis appears appropriate. There were no focal lesions consistent with obstruction or a mass effect observed.

The ileocecal junction was visualized and exhibited normal intact wall layering and is subjectively of normal thickness. Sections of colon are visualized with formed fecal material and gas shadowing distally. There is no observed focal or generalized colon wall thickening or loss of layering.

### ***Pancreas***

The pancreas is normal and isoechoic to surrounding mesentery. There is no evidence of nodules or cystic lesions. There is no evidence of regional mesenteric inflammation or fluid.

### ***Free Abdomen***

Evaluation of the peritoneal cavity did not reveal any evidence of effusion, or subjective lymphadenomegaly. The Medial iliac nodes appear normal and there was no evidence of a caudal aortic thrombus at the bifurcation. The omentum is of normal uniform echogenicity.

## **ULTRASONOGRAPHIC FINDINGS**

- Mildly thickened urinary bladder wall with small amount of dependent sandy debris – The bladder mucosal changes could be consistent with cystitis or artifactual due to lack of adequate luminal distension. Bladder neoplasia cannot be ruled out but is considered unlikely in this patient.
- Decreased corticomedullary distinction in both kidneys – Mild loss of corticomedullary distinction in both kidneys could be consistent with chronic degenerative disease or interstitial nephrosis.
- Large, heterogeneous liver – The diffuse hepatic changes are non-specific and could be consistent with vacuolar hepatopathy, nodular hyperplasia, inflammatory/immune-mediated disease, fibrosis, extramedullary hematopoiesis, toxic hepatopathy (e.g., copper), infiltrative neoplasia (less likely) or other hepatopathy.
- Large amount of debris within the gallbladder with early mucosal stranding and organization of contents – A large amount of debris is evident in the gall bladder with no evidence of a mucocele or associated inflammation at this time. This could represent an early mucocele or cholestasis, with minimal evidence of associated inflammation at this time. Continued monitoring of labwork and ultrasound are warranted for progression of this lesion. Ursodiol therapy could be considered.

## INTERPRETATION OF THE FINDINGS & FURTHER RECOMMENDATIONS

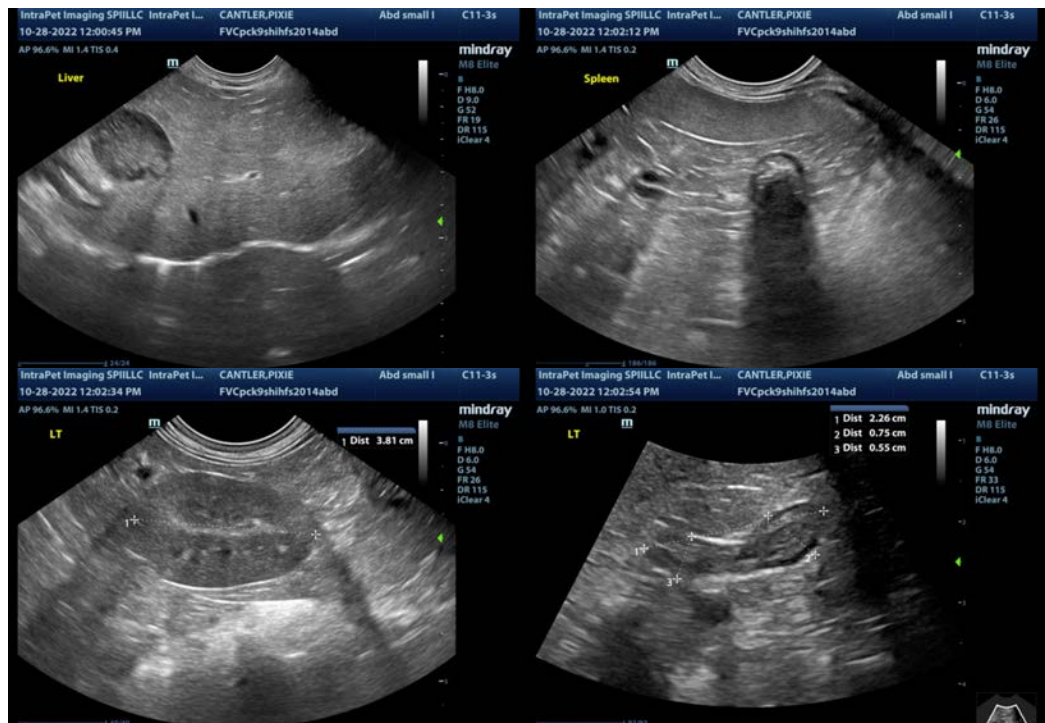
No obvious cause is identified to explain the “episodes” described. There is a small amount of sandy debris in the urinary bladder. This should be able to be passed relatively easy. Recommend a urinalysis and culture.

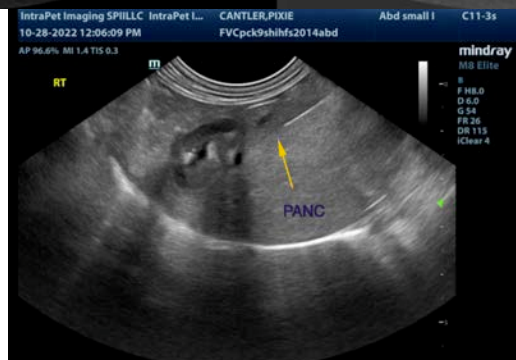
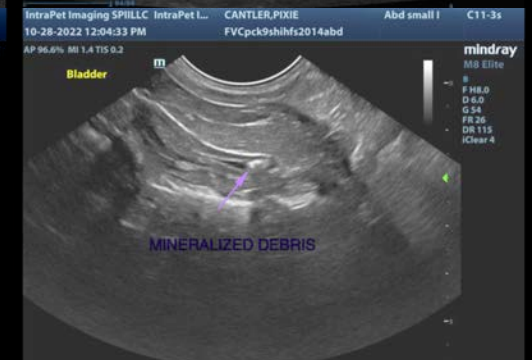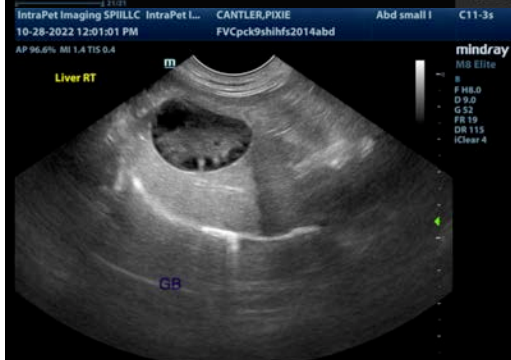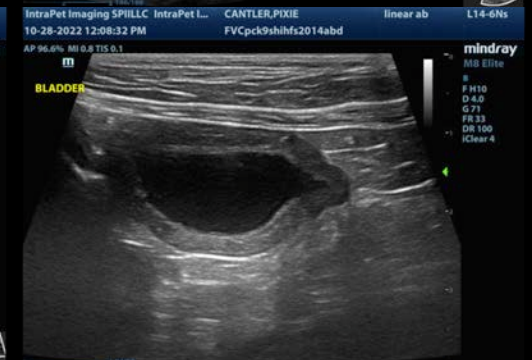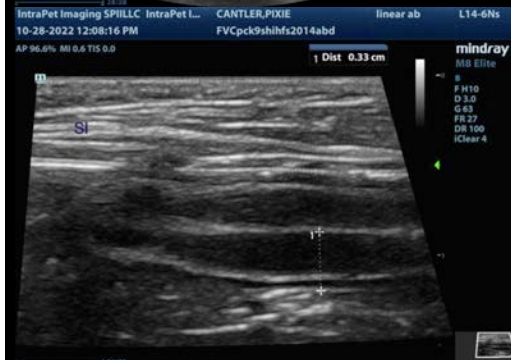
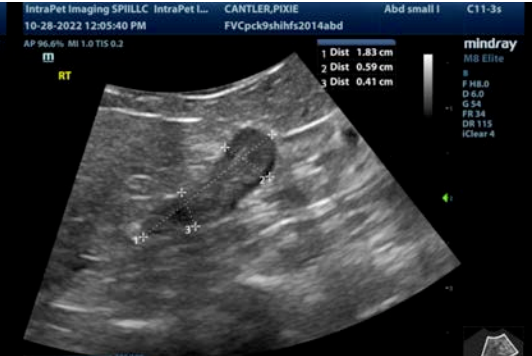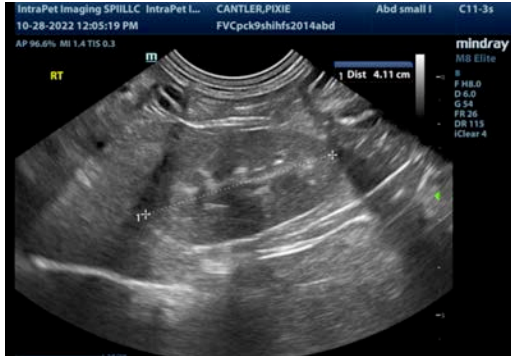The kidneys have reduced corticomedullary distinction for a dog of this age. The significance of this is unclear. Correlate with urine specific gravity and renal values. Recommend baseline blood pressure.

The liver is large and heterogeneous. No focal lesions are observed. Additionally, there is an early mucocele observed in the gallbladder, but no surrounding inflammation or wall thickening. Consider starting Ursodiol therapy and continuing to monitor bloodwork and the appearance of the gallbladder with ultrasound. You could consider a liver function test and a fine needle aspirate to look for significant liver dysfunction and rule out round cell neoplasia.

Consider such differentials as neurologic episodes, pain episodes (neck, back, nerve, etc.). Triglycerides are significantly elevated. Confirm these levels on a 12 hour fast. If they remain elevated, an ultra low-fat diet may be recommended. Additionally, recommend a blood pressure evaluation (as recommended above) and an ionized calcium to determine if the hypercalcemia is real.

Recommend three view thoracic radiographs to evaluate for possible concurrent thoracic disease/involvement.





**The information and recommendations provided are based on the images presented by the referring veterinarian/sonographer. No evaluation can be communicated regarding pathology that was not visible in the image/video clips provided.**

Thank you for this referral. If the clinical or image interpretation does not parallel your findings or if I can be of any further assistance please contact me.

Kathleen Sennello DVM,MS, Diplomate ACVIM (Small animal Internal Medicine)  
kathleen.sennello@sonopath.com