

**DATE PRESENTING CLINICAL SIGNS**

10/28/22

Vomiting with blood, diarrhea ATO in room: - lethargic this morning – vomiting began 8:00 PM last night- saw pink in it - progressed to bile- last vomited this AM after drinking water - went to RDVM on 10/5 for bile vomiting, no blood- recommended bland diet, sent out fecal (normal) but did not do BW -ate yesterday morning- refused food last night (offered chicken and rice) - currently on diamond naturals chicken and rice diet - no chance on FB/toxicity, does have hx of eating house rabbit feces - Owner mentioned that P has had coughing spells/ shortness of breath- was suspicious of a collapsed trachea but rDVM did not think it was that Prior medical hx: - bile vomiting episodes around 9/24, saw rdvm 10/5. meds: - carafate from rdvm 10/5

PATIENT

Lilly Carnohan

SPECIES

Canine

Current Medications: Protonix, Ondansetron, Buprenorphine.

Lab Results: WBC 20k, Neuts 17k.

BREED

Shih Tzu

Date of Previous IntraPet Ultrasound: No previous.

Sedation: Not required to complete full diagnostic ultrasound.

Stat Report: STAT requested.

SEX

Spayed Female

ULTRASONOGRAPHIC EXAMINATION OF THE ABDOMEN**Urinary System**

The urinary bladder is moderately distended with anechoic urine. The Bladder wall, trigone, ureteral papillae and visible urethra (to a depth of 2cm) appear normal with no evidence of wall thickening, mucosal irregularities, masses or cystic calculi.

AGE

6/26/15

The left kidney has a normal shape and size (4.75 cm) with cortical cysts and small non-obstructive nephroliths. Overall echogenicity is slightly hyperechoic with poor corticomedullary distinction and a typical 1:3 cortex:medulla ratio. There is no evidence of focal perinephric inflammation or effusion. There is no evidence of pyelectasia, infarcts or hydroureter. Renal vasculature is normal.

WEIGHT

10.8 Pounds

The right kidney has a normal shape and size (4.57 cm) with small cortical cysts and non-obstructive nephroliths. Overall echogenicity is slightly hyperechoic with poor corticomedullary distinction and a typical 1:3 cortex:medulla ratio. There is no evidence of focal perinephric inflammation or effusion. There is no evidence of pyelectasia, nephroliths, infarcts or hydroureter. Renal vasculature is normal.

INTERPRETED BY

Kathleen Sennello DVM,
MS, Diplomate ACVIM
(Small Animal Internal
Medicine)

Adrenal Glands

The left adrenal gland is normal in size measuring 0.44 cm at the caudal pole. It is observed in its normal position cranial to the left renal artery. It is normal in appearance (uniformly hypoechoic) and shape with no evidence of a mass effect.

IMAGING PERFORMED BY

Rachel Brilhart RDMS

The right adrenal gland is normal in size measuring 0.41 cm at the caudal pole. It is observed in its normal position between the cranial aspect of the right kidney and the caudal vena cava. It is normal in appearance (uniformly hypoechoic) and shape with no evidence of a mass effect.

HOSPITAL NAME

Animal Emergency
Hospital

Spleen

The spleen is subjectively normal in size, echotexture is homogenous, and the splenic capsule is smooth with no irregularities. The blood flow through the hilus and splenic parenchyma appears normal. No focal parenchymal abnormalities are visualized.

REFERRING VET

Dr. Martinoli

Liver

The liver is subjectively normal in size, and echogenicity with smooth peripheral margins. The parenchyma is homogenous echotexture. The visible portions of the vasculature and biliary tract appear normal. No focal nodules or cystic lesions are observed.

INVOICE

42449

The gallbladder lumen is moderately distended. The wall of the gall bladder is not thickened and has a smooth mucosal surface. Luminal contents are mild and primarily anechoic. The cystic and common bile ducts are normal/not visible.

Gastrointestinal

The stomach contains minimal luminal contents. It measures at a normal thickness of <0.7cm with some variability due to the presence of rugal folds. The distinction of the gastric wall layers is adequate and there is no impression of reduced peristaltic activity. No masses or focal lesions were observed.

The visualized areas of duodenum, jejunum and ileum have a uniform diameter with minimal fluid distension. Wall appears subjectively, mildly increased. Bowel loops follow a typical curvilinear path with distinct wall layering. Jejunum wall measures 0.25 cm. Visualized peristalsis appears appropriate. There is a focal area of what appears to be jejunum that reveals a mildly thickened bowel loop at approximately 0.35 cm that progresses to more severe thickening with fuzzy layering and walls measuring approximately 0.45 cm that progresses to reveal a large intraluminal structure measuring approximately 0.89 cm x 2.0 cm. This structure is somewhat irregular and has a soft shadow. Findings could be consistent with organic intraluminal material, possibly tissue (but not color flow), but a likely obstruction or partial obstruction exists. This area is surrounded by hyperechoic mesentery and free fluid (localized peritonitis).

The ileocecal junction was visualized and exhibited normal intact wall layering and is subjectively of normal thickness. Sections of colon are visualized with formed fecal material and gas shadowing distally. There is no observed focal or generalized colon wall thickening or loss of layering.

Pancreas

The pancreas is prominent and mottled compared to the surrounding isoechoic mesentery. There is no evidence of nodules or cystic lesions. There is no evidence of regional mesenteric inflammation or fluid.

Free Abdomen

There is scant free abdominal fluid around the bowel lesion. There are prominent mesenteric lymph nodes with a lymph node at the ileocecal junction measuring 0.56 cm x 0.48 cm and a hyperechoic mesentery around the bowel lesion.

PRIMARY FINDINGS

- Generalized mild small intestinal thickening with a focal area of thickened bowel with decreased detail of layering and an intraluminal structure – Findings are concerning for an intraluminal foreign body with either severe inflammatory change to the bowel wall or possibly infiltrative neoplasia.
- Mild mesenteric lymphadenopathy – The prominent abdominal lymph nodes are most consistent with reactive lymphadenitis or lymphoid hyperplasia. Neoplastic infiltration is considered less likely.
- Scant focal fluid and hyperechoic mesentery around the bowel lesion – Findings are consistent with focal peritonitis (bacterial or sterile).

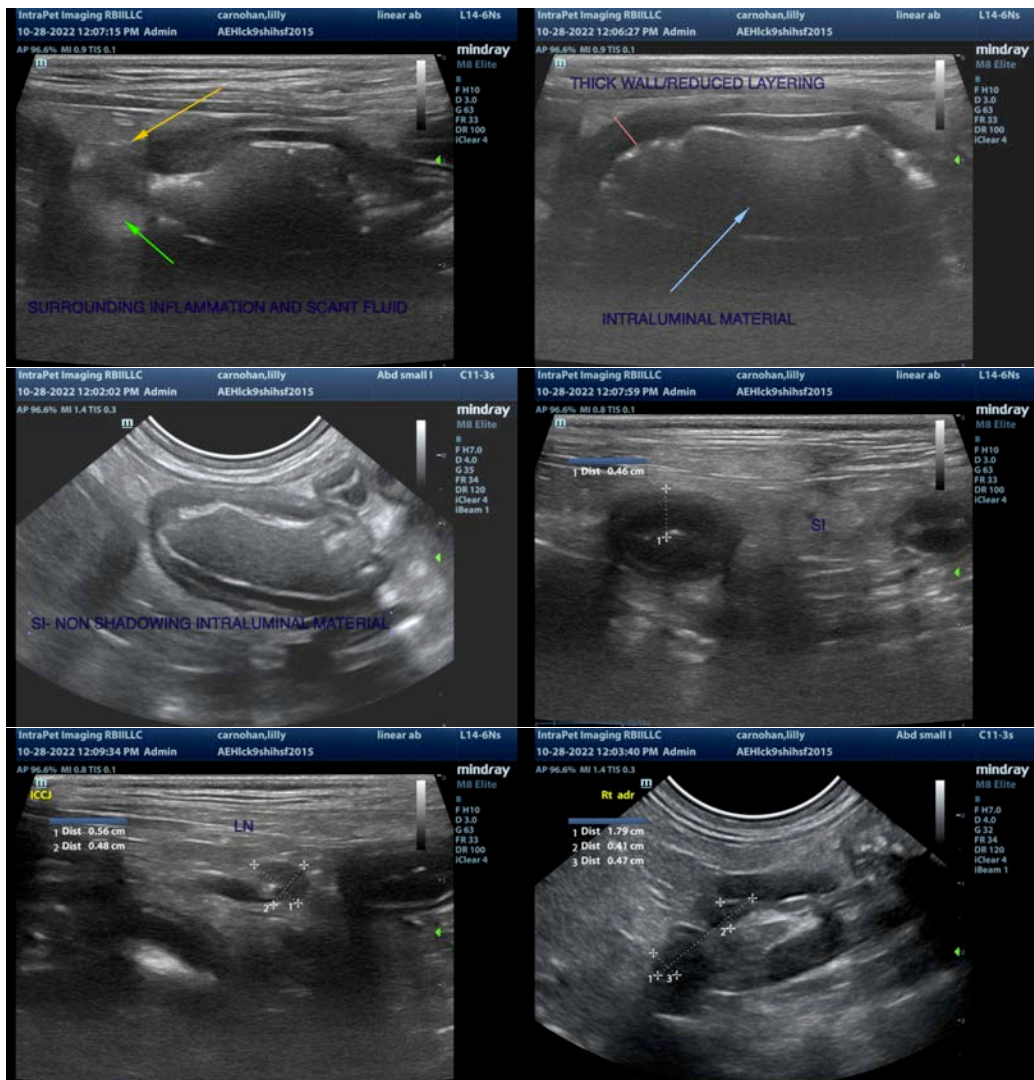
SECONDARY FINDINGS

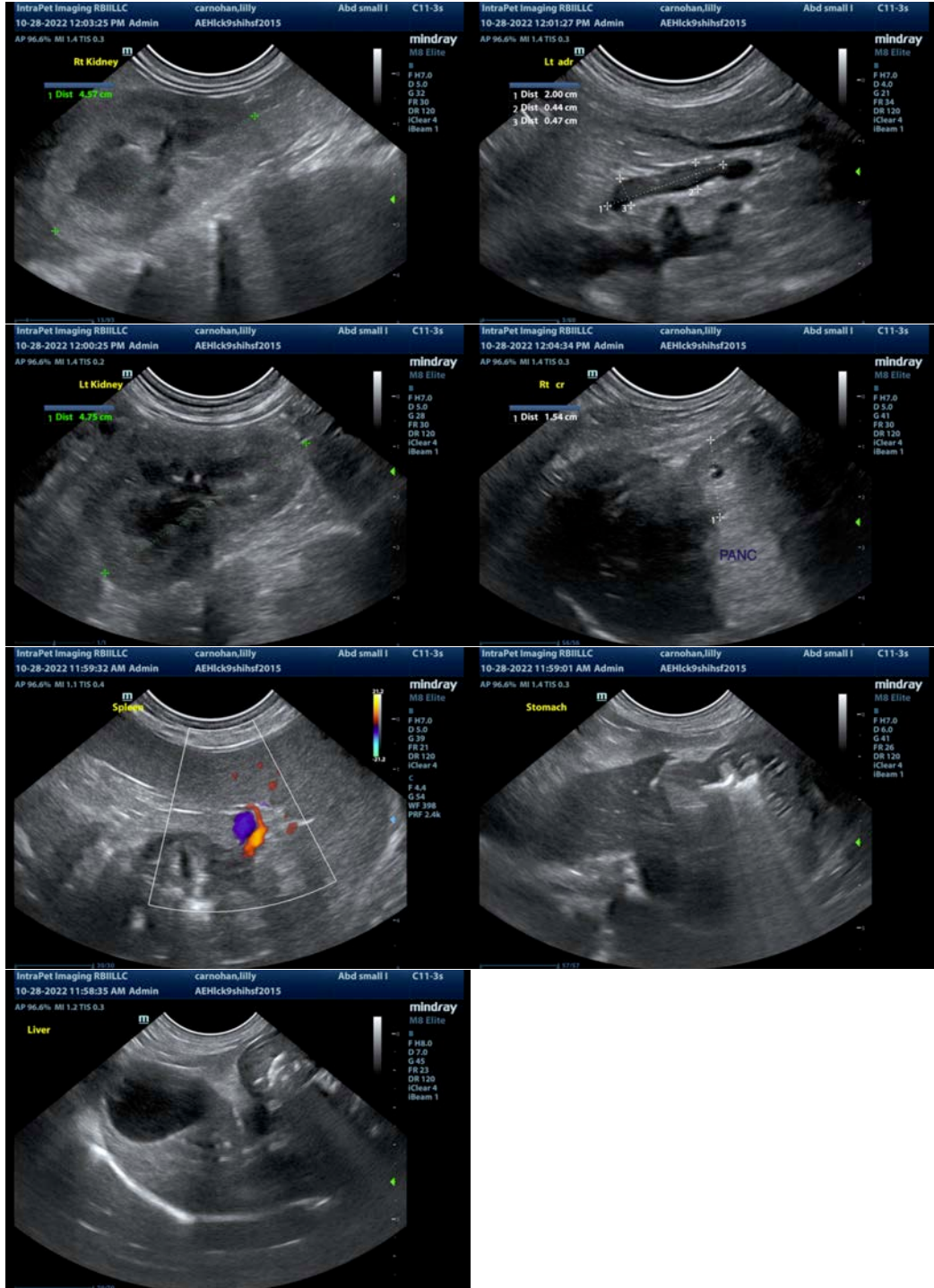
- Decreased corticomedullary distinction in both kidneys with small cortical cysts and non-obstructive nephroliths – Mild loss of corticomedullary distinction in both kidneys could be consistent with chronic degenerative disease or interstitial nephrosis.
- Prominent, mottled pancreas – The pancreatic changes are most consistent with age-related parenchymal remodeling, potentially secondary to a prior inflammatory episode, early fibrosis or chronic pancreatitis.

INTERPRETATION OF THE FINDINGS & FURTHER RECOMMENDATIONS

The bowel appears generally mildly thickened, but there is a focal area of bowel that has a significantly thickened wall and reduced detail of layering, and an intraluminal structure with a soft shadow. These findings are suggestive of intraluminal foreign material with either severely inflamed bowel surrounding this lesion, or possibly a focal bowel mass. Recommend surgical evaluation with the possibility of needing to resect a bowel mass. Additionally, recommend biopsies with histopathology of this tissue.

Recommend three view thoracic radiographs to evaluate for possible concurrent thoracic disease/involvement.





The information and recommendations provided are based on the images presented by the referring veterinarian/sonographer. No evaluation can be communicated regarding pathology that was not visible in the image/video clips provided.

Thank you for this referral. If the clinical or image interpretation does not parallel your findings or if I can be of any further assistance please contact me.

Kathleen Sennello DVM,MS, Diplomate ACVIM (Small animal Internal Medicine)
kathleen.sennello@sonopath.com