



PATIENT

Montana Sky Davis

SPECIES

Canine

BREED

Australian Cattle Dog

SEX

Spayed Female

AGE

10 ½ years

WEIGHT

39.4 lbs

INTERPRETED BY

Kathleen Sennello
DVM, MS, Diplomate
ACVIM (Small Animal
Internal Medicine)

IMAGING PERFORMED BY

Dr. Schroeder

HOSPITAL NAME

Animal Health
Associates

REFERRING VET

Dr. Schroeder

INVOICE

92747

DATE

10/28/21

PRESENTING CLINICAL SIGNS

History: Senior dog adopted as a rescue 6 months ago. Vomiting 1-2 times per week, decreased mobility/energy Senior blood work showed markedly elevated spec cPL, ALP, lipase, mild elevation ALT, UPC

Abnormal PE/Chem/CBC/UA Results: Spec cPL 1114 ug/l ALP 982 U/l ALT 215 U/l Lipase 1594 U/l UPC 0.6 mild lymphopenia.

ULTRASONOGRAPHIC EXAMINATION OF THE ABDOMEN

Urinary System

The urinary bladder is moderately distended with anechoic urine. The Bladder wall, trigone, ureteral papillae and visible urethra (to a depth of 2cm) appear normal with no evidence of wall thickening, mucosal irregularities, masses or cystic calculi.

The left kidney has a normal shape and size (5.8 cm). Overall echogenicity is normal with adequate corticomedullary distinction and a typical 1:3 cortex:medulla ratio. There is no evidence of perinephric inflammation or effusion. There is no evidence of pyelectasia, nephroliths, infarcts or hydroureter. Renal vasculature is normal.

The right kidney has a normal shape and size (6.46 cm). Overall echogenicity is normal with adequate corticomedullary distinction and a typical 1:3 cortex:medulla ratio. There is no evidence of perinephric inflammation or effusion. There is no evidence of pyelectasia, nephroliths, infarcts or hydroureter. Renal vasculature is normal.

Adrenal Glands

The left adrenal gland is normal in size measuring 0.52 cm at the caudal pole It is observed in its normal position cranial to the left renal artery. It is normal in appearance (uniformly hypoechoic) and shape with no evidence of a mass effect.

The right adrenal gland is normal in size measuring 0.7 cm at the caudal pole It is observed in its normal position between the cranial aspect of the right kidney and the caudal vena cava. It is normal in appearance (uniformly hypoechoic) and shape with no evidence of a mass effect.

Spleen

The spleen is subjectively normal in size and the echotexture is homogenous. The splenic capsule is smooth with no visible irregularities. Rare discrete focal hyperechoic, perivascular parenchymal abnormalities are present. The appearance of these lesions is most consistent with benign splenic myelolipomas. The blood flow through the hilus and splenic parenchyma appears normal. One of the larger, prominent, hyperechoic nodules visualized measures 1.45 cm.



PATIENT

Liver

Montana Sky Davis

The liver is large, heterogenous and irregular in shape with an isoechoic/hypoechoic nodule in the periphery measuring 1.36 cm. The gallbladder lumen is moderately distended. The wall of the gallbladder is not thickened and has a smooth mucosal surface. Luminal contents are primarily anechoic. The cystic and common bile ducts are normal/not visible.

SPECIES

Canine

BREED

Australian Cattle Dog

Gastrointestinal

The stomach contains minimal luminal contents. It measures at a normal thickness of <0.7cm with some variability due to the presence of rugal folds. The distinction of the gastric wall layers is adequate and there is no impression of reduced peristaltic activity. No masses or focal lesions were observed.

SEX

Spayed Female

The visualized areas of duodenum, jejunum and ileum have a relatively uniform diameter with minimal fluid distension. Wall thickness is normal. Bowel loops follow a curvilinear path with distinct wall layering maintaining the typical 1:3 muscularis:mucosa layer ratio. The duodenum measured as normal (0.25 cm) and the jejunum measured as normal (0.31 cm). Visualized peristalsis appears appropriate. There were no focal lesions consistent with obstruction or a mass effect observed.

AGE

10 ½ years

The ileocecal junction was visualized and exhibited normal intact wall layering and is subjectively of normal thickness. Sections of colon are visualized with formed fecal material and gas shadowing distally. There is no observed focal or generalized colon wall thickening or loss of layering.

WEIGHT

39.4 lbs

Pancreas

The pancreas is normal and isoechoic to surrounding mesentery. There is no evidence of nodules or cystic lesions. There is no evidence of regional mesenteric inflammation or fluid.

INTERPRETED BY

Kathleen Sennello
DVM, MS, Diplomate
ACVIM (Small Animal
Internal Medicine)

Free Abdomen

Evaluation of the peritoneal cavity did not reveal any evidence of effusion, or subjective lymphadenomegaly. The Medial iliac nodes appear normal and there was no evidence of a caudal aortic thrombus at the bifurcation. The omentum is of normal uniform echogenicity.

IMAGING PERFORMED BY

Dr. Schroeder

HOSPITAL NAME

Animal Health
Associates

ULTRASONOGRAPHIC FINDINGS

PRIMARY FINDINGS:

- Large, irregular heterogenous liver with an isoechoic to hypoechoic nodule. The diffuse hepatic changes are non-specific and could be consistent with vacuolar hepatopathy, nodular hyperplasia, inflammatory/immune-mediated disease, fibrosis, extramedullary hematopoiesis, toxic hepatopathy (e.g., copper), infiltrative neoplasia (less likely) or other hepatopathy.

REFERRING VET

Dr. Schroeder

SECONDARY FINDINGS:

- Numerous, hyperechoic foci within the splenic parenchyma. These nodules do not deviate the capsule and are most consistent with myelolipomas. Although a neoplastic process cannot be ruled out.

INVOICE

92747

DATE

10/28/21



PATIENT

Montana Sky Davis

SPECIES

Canine

BREED

Australian Cattle Dog

SEX

Spayed Female

AGE

10 ½ years

WEIGHT

39.4 lbs

INTERPRETED BY

Kathleen Sennello
DVM, MS, Diplomate
ACVIM (Small Animal
Internal Medicine)

IMAGING PERFORMED BY

Dr. Schroeder

HOSPITAL NAME

Animal Health
Associates

REFERRING VET

Dr. Schroeder

INVOICE

92747

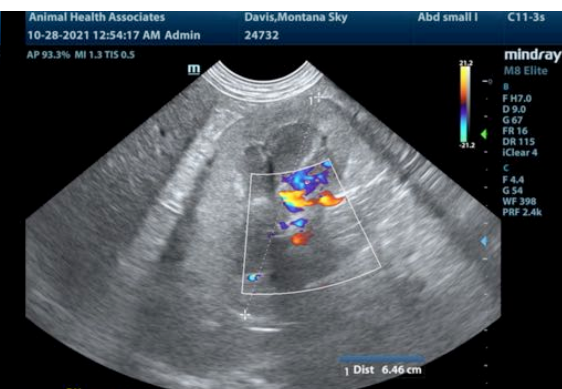
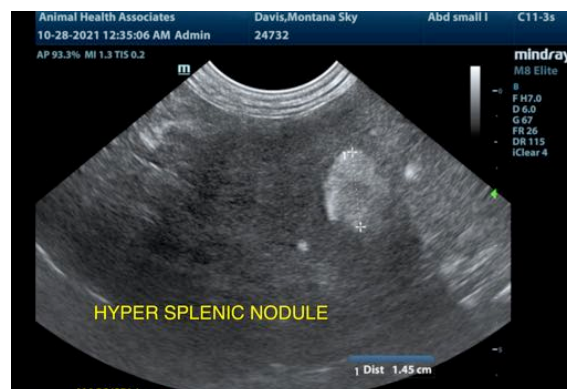
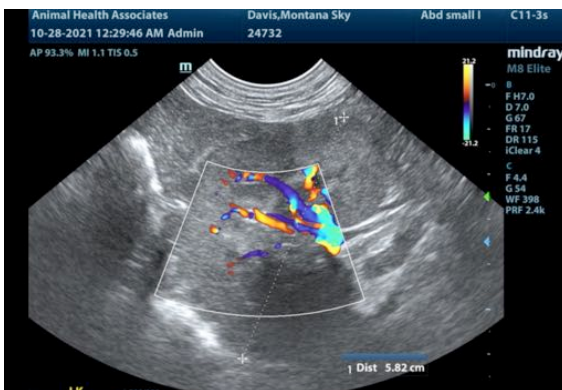
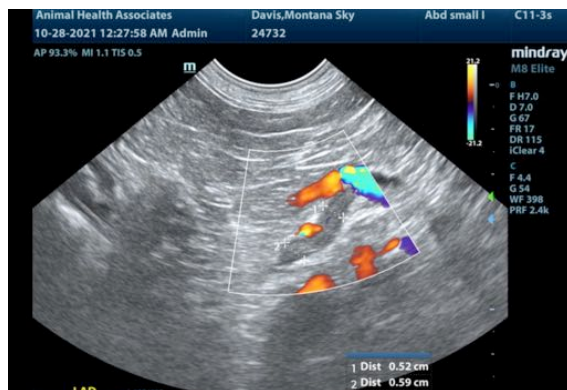
DATE

10/28/21

INTERPRETATION OF THE FINDINGS & FURTHER RECOMMENDATIONS

The liver is large, heterogenous and has irregular margins. There is a small, hypoechoic to isoechoic nodule visualized. These changes are non-specific and may be consistent with a benign process such as Cushing's disease or hepatitis, lymphoma, etc. The scan today supports a primary hepatopathy as no severe biliary changes were observed.

- Consider close evaluation of history for possible toxic changes examine medications, diet, dietary indiscretion etc...
- Consider PCR on urine/serum for leptospirosis (if not on antibiotics)/serology if recent antibiotic history
- If not already done, consider pre and post prandial bile acids to evaluate liver function
- If the ALP is significantly elevated relative to the ALT and symptoms consistent with Cushing's are present, consider adrenal function testing (ACTH stim)
- Consider Fine needle aspirate if round cell neoplasia is on your differential list (25 g needle, normal coags)
- If no response to supportive care (Denamarin, fluids, antibiotics,+/- Ursodiol etc...) Consider liver biopsy with samples obtained for histopathology, culture, and copper levels.





PATIENT

Montana Sky Davis

SPECIES

Canine

BREED

Australian Cattle Dog

SEX

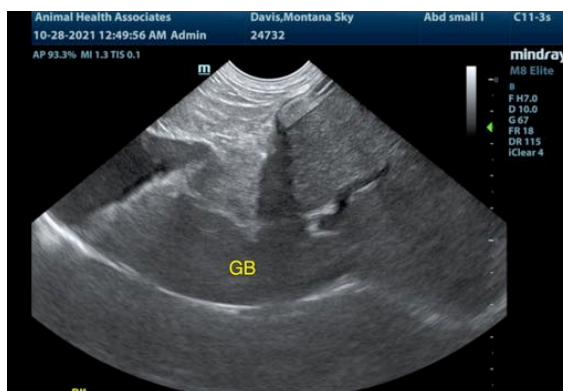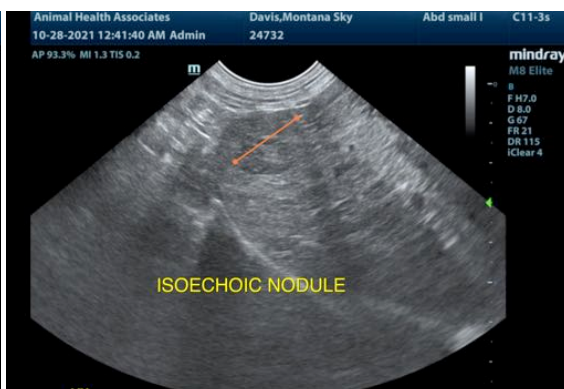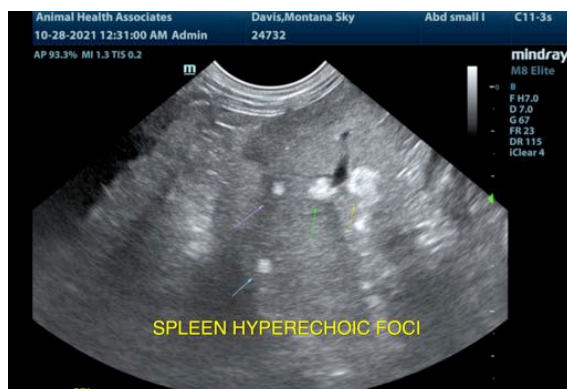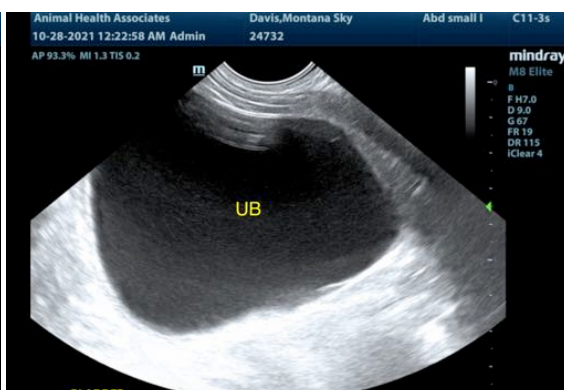
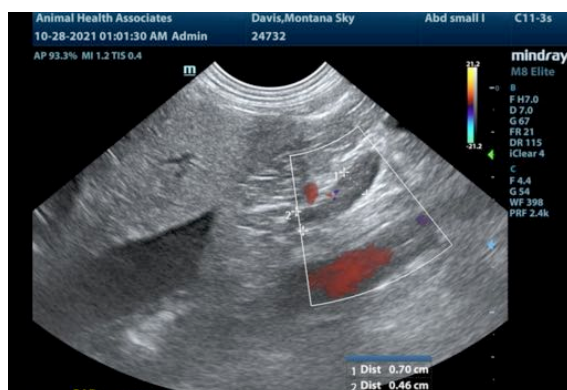Spayed Female

AGE

10 ½ years

WEIGHT

39.4 lbs



INTERPRETED BY

Kathleen Sennello
DVM, MS, Diplomate
ACVIM (Small Animal
Internal Medicine)

IMAGING PERFORMED BY

Dr. Schroeder

HOSPITAL NAME

Animal Health
Associates

REFERRING VET

Dr. Schroeder

INVOICE

92747

DATE

10/28/21

The information and recommendations provided are based on the images presented by the referring veterinarian. No evaluation can be communicated regarding pathology that was not visible in the image/video clips provided.

Thank you for this referral. If the clinical or image interpretation does not parallel your findings or if I can be of any further assistance please contact me.

Kathleen Sennello DVM,MS, Diplomate ACVIM (Small animal Internal Medicine)
kathleen.sennello@sonopath.com