
PATIENT PRESENTING CLINICAL SIGNS

Henri Ranieri

SPECIES

Feline

BREED

DLH

SEX

Neutered Male

AGE

5 Years

WEIGHT

7.9 kg

INTERPRETED BY

 Kathleen Sennello DVM,
 MS, Diplomate ACVIM
 (Small Animal Internal
 Medicine)

IMAGING PERFORMED BY

Kelly Reschny

HOSPITAL NAME

BPH Ancaster

REFERRING VET

Dr. Davis

INVOICE

42398

DATE

10/27/22

Intermittent GI upset, on long-term prednisolone and lactulose. Last ultrasound Dec 2021 showed signs of peritonitis, possible FIP, LMA, pancreatitis. Palpable mass effect. BAR has been on pred tapering since free fluid and enlarged liver/spleen seen on ultrasound last year. goes off food every time we try to taper pred but is currently doing well in 3/4 tab sid although o notes decrease in appetite since decreasing to this dose 2 weeks ago (he had been getting her up at 4 am for food when he was getting a full tab) o is doing away in august so will keep him on 3/4 tab sid until he's back he is getting 1.5ml lactulose daily as well. O notes stools are a bit small and light still meds: Prednisolone 5mg 3/4 tab SID; Lactulose 1.5ml SID

Abnormal PE/Chem/CBC/UA Results: Please see previous US report attached.

ULTRASONOGRAPHIC EXAMINATION OF THE ABDOMEN
Urinary System

The urinary bladder is moderately distended with mild primarily suspended echogenic debris present. The Bladder wall, trigone, ureteral papillae and visible urethra (to a depth of 2cm) appear normal with no evidence of wall thickening, mucosal irregularities, masses or calculi. Echogenic debris of this type can be associated with small crystals, cellular debris and proteinaceous debris.

The left kidney has a normal shape and size (4.49 cm). Overall echogenicity is normal with adequate corticomedullary distinction and a typical 1:3 cortex:medulla ratio. There is no evidence of focal perinephric inflammation or effusion. There is no evidence of pyelectasia, nephroliths, infarcts or hydroureter. Renal vasculature is normal.

The right kidney has a normal shape and size (4.03 cm). Overall echogenicity is normal with adequate corticomedullary distinction and a typical 1:3 cortex:medulla ratio. There is no evidence of focal perinephric inflammation or effusion. There is no evidence of pyelectasia, nephroliths, infarcts or hydroureter. Renal vasculature is normal.

Adrenal Glands

The left adrenal gland is normal in size measuring 0.23 cm at the caudal pole. It is observed in its normal position cranial to the left renal artery. It is normal in appearance (uniformly hypoechoic) and shape with no evidence of a mass effect.

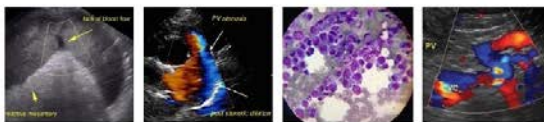
The right adrenal gland is normal in size measuring 0.21 cm at the caudal pole. It is observed in its normal position between the cranial aspect of the right kidney and the caudal vena cava. It is normal in appearance (uniformly hypoechoic) and shape with no evidence of a mass effect.

Spleen

The spleen is normal/borderline large (0.94 cm in width at the level of the hilus), echotexture is homogenous, and the splenic capsule is smooth with no irregularities. The blood flow through the hilus and splenic parenchyma appears normal. No focal parenchymal abnormalities are visualized.

Liver

The liver is subjectively normal in size, and echogenicity with smooth peripheral margins. The parenchyma is heterogenous in echotexture with subtle, indistinct focal mottling. The visible portions of the vasculature and biliary tract appear normal. No focal nodules or cystic lesions are observed.



PATIENT

Henri Ranieri

The gallbladder lumen is moderately distended. The wall of the gall bladder is not thickened and has a smooth mucosal surface. Luminal contents are mild and primarily anechoic. The cystic and common bile ducts are normal/not visible.

SPECIES

Feline

Gastrointestinal

The stomach contains minimal luminal contents. It measures at a normal thickness of <0.36cm with some variability due to the presence of rugal folds. The distinction of the gastric wall layers is adequate and there is no impression of reduced peristaltic activity. No masses or focal lesions were observed.

BREED

DLH

The visualized areas of duodenum, jejunum and ileum have a uniform diameter with minimal fluid distension. Wall thickness is normal to slightly increased. Bowel loops follow a typical curvilinear path with distinct wall layering, but some areas display a prominent muscularis layer which does not display the typical 1:3 muscularis:mucosa layer ratio. Jejunum wall measures 0.30 cm. Visualized peristalsis appears appropriate. There were no focal lesions consistent with obstruction or a mass effect observed.

SEX

Neutered Male

The ileocecal junction was visualized and exhibited normal intact wall layering and is subjectively of normal thickness. Sections of colon are visualized with formed fecal material and gas shadowing distally. There is no observed focal or generalized colon wall thickening or loss of layering.

AGE

5 Years

Pancreas

The pancreas is not clearly visualized.

WEIGHT

7.9 kg

Free Abdomen

Evaluation of the peritoneal cavity did not reveal any evidence of effusion.

There is a poorly defined hypoechoic lesion, most consistent with a mesenteric lymph node, measuring 1.38 cm in diameter.

INTERPRETED BY

Kathleen Sennello DVM,
MS, Diplomate ACVIM
(Small Animal Internal
Medicine)

Additionally, there is an ill-defined hypoechoic lesion in the mid abdomen, measuring 3.57 cm x 3.58 cm. Margins are very indistinct and there is bowel associated with this lesion. Consider the possibility of bowel adhesions creating a mass effect.

The omentum is diffusely hyperechoic, but no nodules are seen in the mesentery.

IMAGING PERFORMED BY

Kelly Reschny

ULTRASONOGRAPHIC FINDINGS

- Mildly echogenic debris in the urinary bladder – The echogenic debris in the bladder lumen could be consistent with cells, crystals, and/or mucus.

HOSPITAL NAME

BPH Ancaster

- Heterogeneous liver – Hepatic changes are non-specific and could be consistent with inflammation/infection (cholangiohepatitis), infiltrative neoplasia, lipidosis or other hepatopathy.

REFERRING VET

Dr. Davis

- Prominent muscularis layer to the small intestine – The small intestinal wall changes could be consistent with an underlying inflammatory process. These types of changes can sometimes be seen in normal older cats. Correlate with clinical signs.

INVOICE

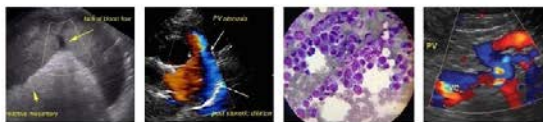
42398

- Ill-defined hypoechoic mass effect associated with several loops of bowel – Consider the possibility of an adhesion connecting several bowel loops.

- Mesenteric lymphadenopathy – The prominent abdominal lymph nodes are most consistent with reactive lymphadenitis or lymphoid hyperplasia. Neoplastic infiltration is considered less likely.

DATE

10/27/22



PATIENT

- Diffusely hyperechoic mesentery

Henri Ranieri

INTERPRETATION OF THE FINDINGS & FURTHER RECOMMENDATIONS

SPECIES

I am so happy to see this kitty stable and doing reasonably well. Although today's scan is not normal, it is significantly improved in that the fluid is gone, the inflammation in the abdomen is less severe, and the omentum is diffusely hyperechoic instead of nodular and mixed echogenicity.

Feline

BREED

There are some ill-defined prominent lymph nodes and a possible mid abdominal mass effect that has very indistinct borders. I'm wondering if this could represent adhesions? The bowel overall appears less inflamed, and there is no significant corrugation. The spleen appears more normal and is stable in size.

DLH

SEX

I would likely consider staying the course. If there is a problem with the chronic Prednisone therapy, you could consider concurrent use of a different immunosuppressant to try and reduce the Prednisone dose, but for now I would be very happy with this outcome. If more information is desired, you could consider a urinalysis and culture due to the echogenic debris in the urinary bladder. You could aspirate a mesenteric lymph node and/or the liver. Recommend continued monitoring.

Neutered Male

AGE

5 Years

WEIGHT

7.9 kg

INTERPRETED BY

Kathleen Sennello DVM,
MS, Diplomate ACVIM
(Small Animal Internal
Medicine)

IMAGING PERFORMED BY

Kelly Reschny

HOSPITAL NAME

BPH Ancaster

REFERRING VET

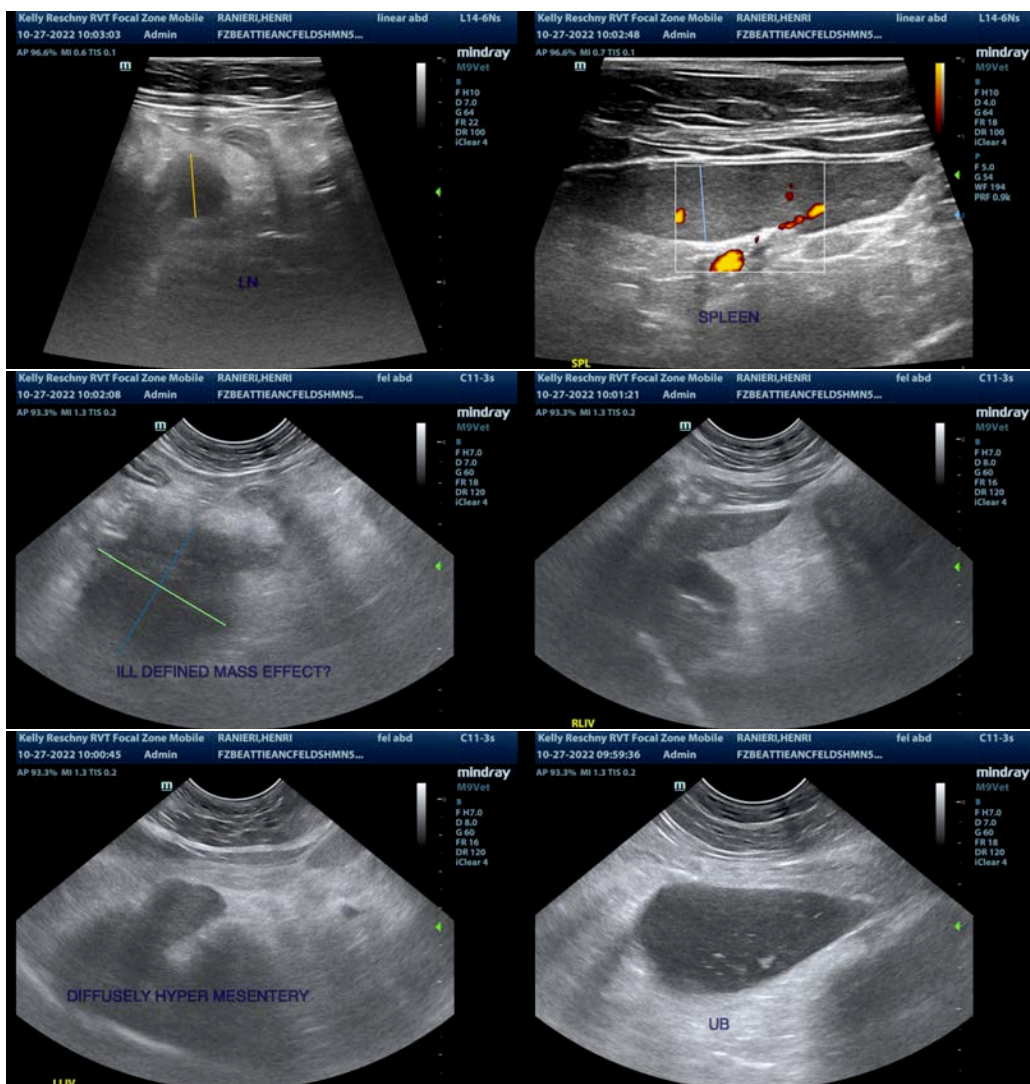
Dr. Davis

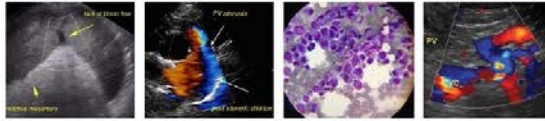
INVOICE

42398

DATE

10/27/22





PATIENT

Henri Ranieri

SPECIES

Feline

BREED

DLH

SEX

Neutered Male

AGE

5 Years

WEIGHT

7.9 kg

INTERPRETED BY

Kathleen Sennello DVM,
MS, Diplomate ACVIM
(Small Animal Internal
Medicine)

**IMAGING
PERFORMED BY**

Kelly Reschny

HOSPITAL NAME

BPH Ancaster

REFERRING VET

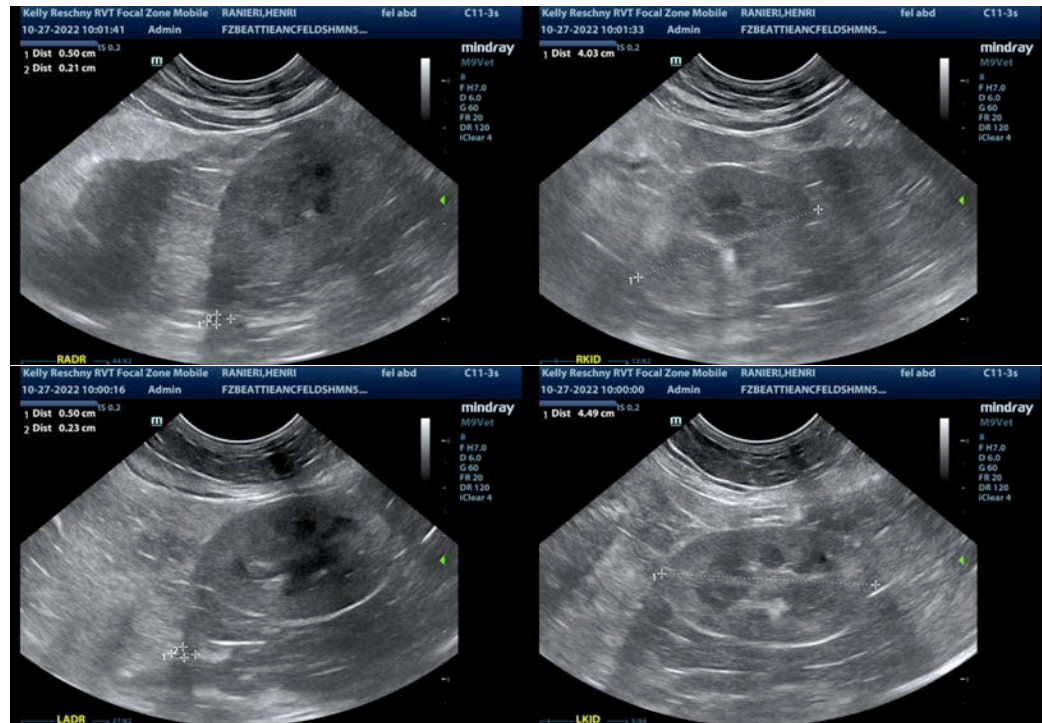
Dr. Davis

INVOICE

42398

DATE

10/27/22



The information and recommendations provided are based on the images presented by the referring veterinarian/sonographer. No evaluation can be communicated regarding pathology that was not visible in the image/video clips provided.

Thank you for this referral. If the clinical or image interpretation does not parallel your findings or if I can be of any further assistance please contact me.

Kathleen Sennello DVM,MS, Diplomate ACVIM (Small animal Internal Medicine)

kathleen.sennello@sonopath.com