

**DATE PRESENTING CLINICAL SIGNS**

10/27/22 Pt presents with polyphagia, PU/PD x 2 month duration. Liver enzymes are elevated and urine is dilute.

PATIENT Current Medications: None listed.

Lab Results: See attached.

Cyril March Date of Previous IntraPet Ultrasound: No previous.

Sedation: Not required to complete full diagnostic ultrasound.

Stat Report: Not requested.

SPECIES

Canine

ULTRASONOGRAPHIC EXAMINATION OF THE ABDOMEN**BREED** *Urinary System*

Terrier X

The urinary bladder is moderately distended with anechoic urine. The Bladder wall, trigone, ureteral papillae and visible urethra (to a depth of 2cm) appear normal with no evidence of wall thickening, mucosal irregularities, masses or cystic calculi.

SEX

Neutered Male

The prostate is normal in size (0.90 cm) and shape for this neutered male dog. The parenchyma is homogenous and the external margins are smooth. The prostatic urethra appears normal with no evidence of irregularity, invasion, mass effect or calculi.

AGE

1/3/15

The left kidney has a normal shape and size (5.42 cm). Overall echogenicity is normal with adequate corticomedullary distinction and a typical 1:3 cortex:medulla ratio. There is no evidence of focal perinephric inflammation or effusion. There is no evidence of pyelectasia, nephroliths, infarcts or hydroureter. Renal vasculature is normal. There is a slightly mixed echogenic, round lesion in the cranial pole of the kidney measuring 1.22 cm x 1.27 cm. This lesion could represent a complex cyst or a nodule.

WEIGHT

28.5 Pounds

The right kidney has a normal shape and size (5.57 cm). Overall echogenicity is normal with adequate corticomedullary distinction and a typical 1:3 cortex:medulla ratio. There is no evidence of focal perinephric inflammation or effusion. There is no evidence of pyelectasia, nephroliths, infarcts or hydroureter. Renal vasculature is normal.

INTERPRETED BY

Kathleen Sennello DVM,
MS, Diplomate ACVIM
(Small Animal Internal
Medicine)

Adrenal Glands

The left adrenal gland is normal in size measuring 0.62 cm at the caudal pole. It is observed in its normal position cranial to the left renal artery. It is normal in appearance (uniformly hypoechoic) and shape with no evidence of a mass effect.

IMAGING PERFORMED BY

Rachel Brilhart RDMS

The right adrenal gland is normal in size measuring 0.54 cm at the caudal pole. It is observed in its normal position between the cranial aspect of the right kidney and the caudal vena cava. It is normal in appearance (uniformly hypoechoic) and shape with no evidence of a mass effect.

HOSPITAL NAME

Bayside AMC

Spleen

The spleen is subjectively normal in size, echotexture is homogenous, and the splenic capsule is smooth with no irregularities. The blood flow through the hilus and splenic parenchyma appears normal. There is a 0.69 cm hypoechoic nodule visualized in the region of the hilus.

REFERRING VET

Dr. Sims

Liver**INVOICE**

42425

The liver is subjectively normal in size, and echogenicity with smooth peripheral margins. The parenchyma is homogenous echotexture. The visible portions of the vasculature and biliary tract appear normal. No focal nodules or cystic lesions are observed.

The gallbladder lumen is moderately distended. The wall of the gall bladder is not thickened and has a smooth mucosal surface. Luminal contents are mild and primarily anechoic. The cystic and common bile ducts are normal/not visible.

Gastrointestinal

The stomach contains minimal luminal contents. It measures at a normal thickness of <0.7cm with some variability due to the presence of rugal folds. The distinction of the gastric wall layers is adequate and there is no impression of reduced peristaltic activity. No masses or focal lesions were observed.

The visualized areas of duodenum, jejunum and ileum have a relatively uniform diameter with minimal fluid distension. Wall thickness is normal. Bowel loops follow a curvilinear path with distinct wall layering maintaining the typical 1:3 muscularis:mucosa layer ratio. Duodenum wall measured 0.51 cm. Jejunum wall measures 0.43 cm. Visualized peristalsis appears appropriate. There were no focal lesions consistent with obstruction or a mass effect observed.

The ileocecal junction was visualized and exhibited normal intact wall layering and is subjectively of normal thickness. Sections of colon are visualized with formed fecal material and gas shadowing distally. There is no observed focal or generalized colon wall thickening or loss of layering.

Pancreas

The pancreas is prominent and mottled compared to the surrounding isoechoic mesentery. There is no evidence of nodules or cystic lesions. There is no evidence of regional mesenteric inflammation or fluid.

Free Abdomen

Evaluation of the peritoneal cavity did not reveal any evidence of effusion, or subjective lymphadenomegaly. The Medial iliac nodes appear normal and there was no evidence of a caudal aortic thrombus at the bifurcation. The omentum is of normal uniform echogenicity.

Other

A brief view of the heart was submitted. No significant pericardial effusion was seen.

ULTRASONOGRAPHIC FINDINGS

- Mixed echogenic lesion in the cranial pole of the left kidney – The appearance is suggestive of either a nodule or a complex echogenic cyst.
- Hypoechoic nodule in the spleen – There is a non-cavitated, hypoechoic splenic nodule visualized. Differentials include lymphoid hyperplasia, extramedullary hematopoiesis, infiltrative neoplasia, inflammation, other. Cytology or histopathology would be necessary to get a definitive diagnosis.
- Prominent, mottled pancreas – The pancreatic changes are most consistent with age-related parenchymal remodeling, potentially secondary to a prior inflammatory episode, early fibrosis or chronic pancreatitis.

INTERPRETATION OF THE FINDINGS & FURTHER RECOMMENDATIONS

The adrenal glands are relatively normal in size and appearance. This does not exclude the possibility of underlying Cushing's but may make it less likely. Correlate findings with the clinical signs. If there is a persistent strong suspicion, then consider adrenal function testing.

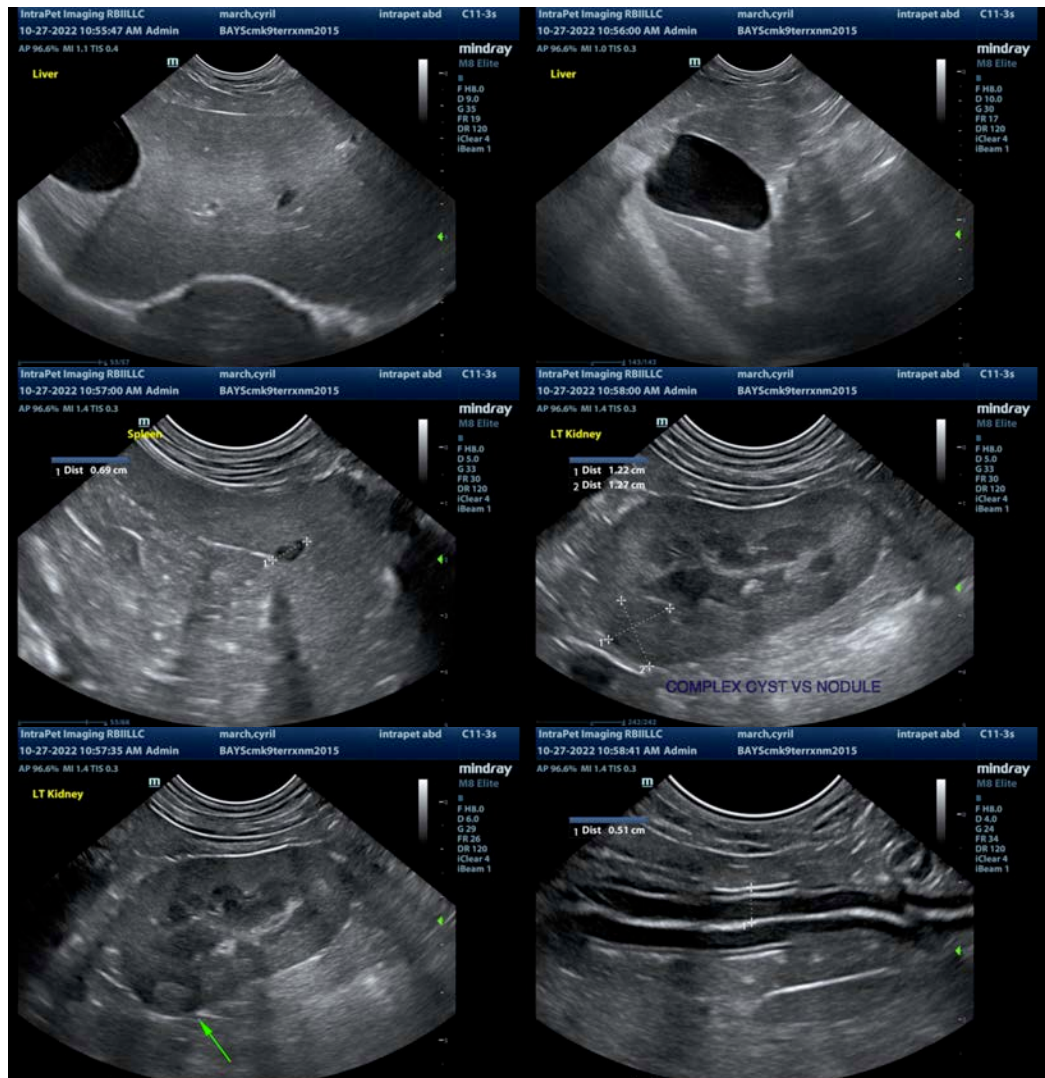
Additionally, depending on the liver enzyme elevations present, consider a liver function test and a fine needle aspirate of the liver, as this might help rule out primary liver disease as a differential.

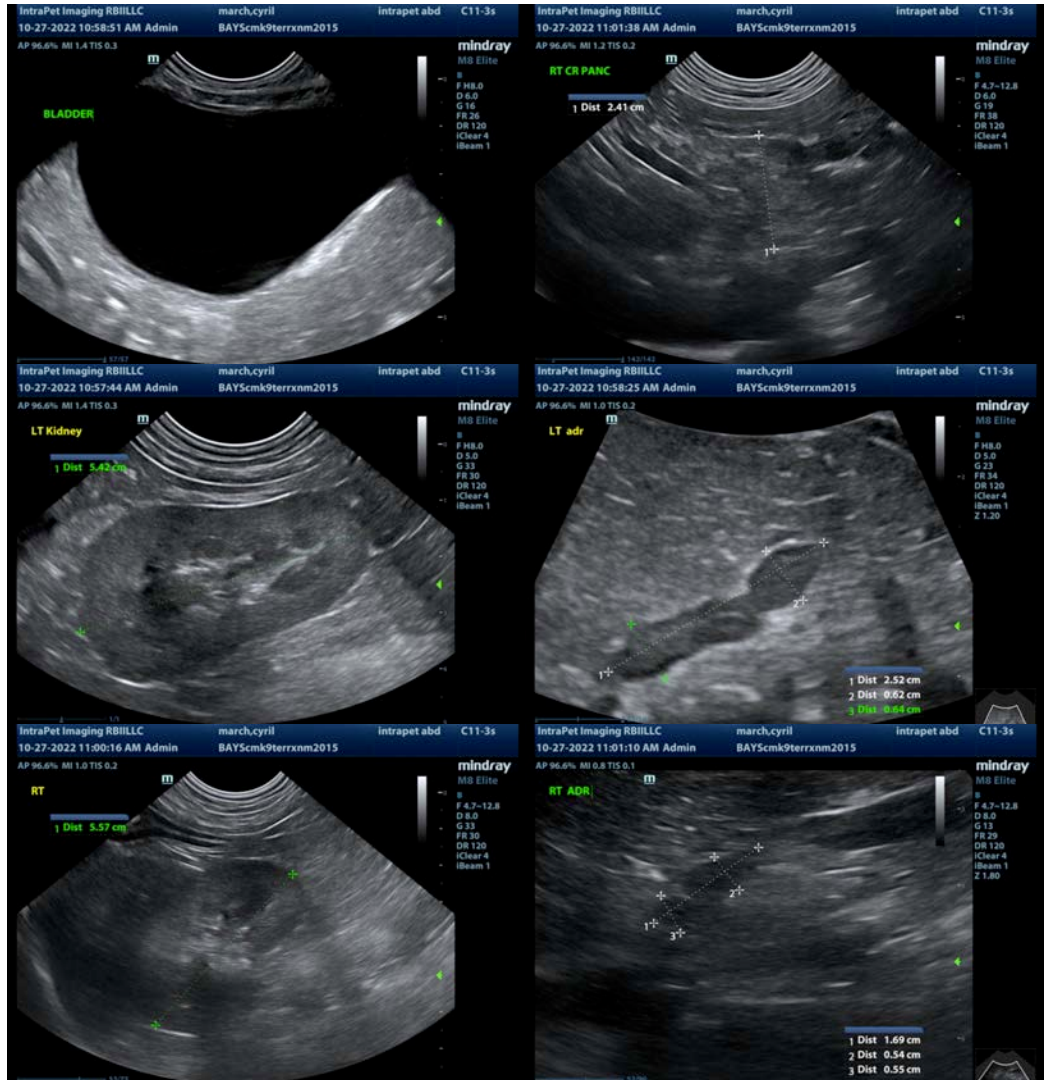
There is a lesion in the cranial pole of the left kidney. This could represent an echogenic benign cyst or could be an early nodule. Unfortunately, the location of this lesion makes an aspirate unlikely to be possible. Options moving forward would include a contrast CT scan to better evaluate the lesion or continued monitoring with ultrasound (recheck in 6-12 weeks).

Recommend three view thoracic radiographs to evaluate for possible concurrent thoracic disease/involvement.

There is a small hypoechoic splenic lesion visualized. Unfortunately, the location of this lesion makes a fine needle aspirate difficult/not possible. Options would include either continued monitoring with ultrasound or a splenectomy (consider recheck of the spleen at the same time as the renal nodule).

Additionally, consider other differentials for PU/PD. Recommend urinalysis and culture, possibly Leptospirosis screening, confirm normal calcium levels, etc.





The information and recommendations provided are based on the images presented by the referring veterinarian/sonographer. No evaluation can be communicated regarding pathology that was not visible in the image/video clips provided.

Thank you for this referral. If the clinical or image interpretation does not parallel your findings or if I can be of any further assistance please contact me.

Kathleen Sennello DVM,MS, Diplomate ACVIM (Small animal Internal Medicine)
 kathleen.sennello@sonopath.com