

IMAGING PERFORMED BY

IntraPet.com



SonoPath

Clinical Sonography & Telectology

EDUCATIONAL TELECONSULTATION SERVICES™

1-800-838-4268 info@sonopath.com SonoPath.com

DATE PRESENTING CLINICAL SIGNS

10/27/22 Hx of several months of elevated liver chems. Dog has been doing ok/eating ok but has lost about a pound in last 3 months.

PATIENT

Cheddar Glass Current Medications: Denamarin.
Lab Results: 8/19- ALT 285, ALKP 132, AST 84, GGT 21. 6/20- ALT 167, ALKP 75, AST 47, GGT 139. 4/21- ALT 73, ALKP 75. 4/22 ALT 557, ALKP 286. 9/22- ALT 304, ALKP 513.

SPECIES

Canine

Date of Previous IntraPet Ultrasound: No previous.
Sedation: Not required to complete full diagnostic ultrasound.
Stat Report: Not requested.

BREED

Poodle X

ULTRASONOGRAPHIC EXAMINATION OF THE ABDOMEN

SEX

Spayed Female

Urinary System

The urinary bladder is moderately distended with anechoic urine. The Bladder wall, trigone, ureteral papillae and visible urethra (to a depth of 2cm) appear normal with no evidence of wall thickening, mucosal irregularities, masses or cystic calculi.

AGE

2/28/05

The left kidney has a normal shape and size (4.94 cm) with small cortical cysts, the largest of which measures 0.91 cm. Overall echogenicity is slightly hyperechoic with poor corticomedullary distinction and a typical 1:3 cortex:medulla ratio. There is no evidence of focal perinephric inflammation or effusion. There is no evidence of pyelectasia, nephroliths, infarcts or hydroureter. Renal vasculature is normal.

WEIGHT

11.2 Pounds

The right kidney has a normal shape and size (4.52 cm) with small cortical cysts and pyelectasia at 0.24 cm. Overall echogenicity is slightly hyperechoic with poor corticomedullary distinction and a typical 1:3 cortex:medulla ratio. There is no evidence of focal perinephric inflammation or effusion. There is no evidence of nephroliths, infarcts or hydroureter. Renal vasculature is normal.

INTERPRETED BY

Kathleen Sennello DVM,
MS, Diplomate ACVIM
(Small Animal Internal
Medicine)

Adrenal Glands

The left adrenal gland is borderline large, measuring 0.44 cm at the cranial pole, 0.76 cm at the caudal pole, and 1.6 cm in length. It is observed in its normal position cranial to the left renal artery. It is slightly irregular in appearance in that the caudal pole is large and slightly irregular with poor distinction in the region of the left renal artery. There could be concern for an early mass effect and extension. Close continued monitoring is warranted.

IMAGING PERFORMED BY

Rachel Brilhart RDMS

The right adrenal gland is normal in size measuring 0.62 cm at the caudal pole. It is observed in its normal position between the cranial aspect of the right kidney and the caudal vena cava. It is normal in appearance (uniformly hypoechoic) and shape with no evidence of a mass effect.

HOSPITAL NAME

Healing Paws Vet
Wellness Center

Spleen

The spleen is subjectively normal in size, echotexture is homogenous, and the splenic capsule is smooth with no irregularities. The blood flow through the hilus and splenic parenchyma appears normal. No focal parenchymal abnormalities are visualized.

REFERRING VET

Dr. Levitsky

Liver

The liver is large and irregular. The parenchyma is heterogenous in echotexture with subtle, indistinct focal mottling. The visible portions of the vasculature and biliary tract appear normal. There are numerous large, hyperechoic cystic, multilobulated mass effects in the liver. It is somewhat difficult to determine if there are multiple masses, or if these represent extensions/lobulations of once mass effect. There is a very large mass on the right side measuring 9.39 cm x 5.92 cm, a mass near the gallbladder measuring 4.34 cm x 3.89 cm, and another mass measuring 5.64 cm x 4.7 cm.

INVOICE

42421

The gall bladder lumen is moderately distended. The wall of the gall bladder is not thickened and has a smooth mucosal surface. There is a moderate amount of non-organized echogenic debris. The cystic and common bile ducts are normal/not visible.

Gastrointestinal

The stomach contains minimal luminal contents. It measures at a normal thickness of <0.7cm with some variability due to the presence of rugal folds. The distinction of the gastric wall layers is adequate and there is no impression of reduced peristaltic activity. No masses or focal lesions were observed.

The visualized areas of duodenum, jejunum and ileum have a relatively uniform diameter with minimal fluid distension. Wall thickness is normal. Bowel loops follow a curvilinear path with distinct wall layering maintaining the typical 1:3 muscularis:mucosa layer ratio. Duodenum wall measured 0.42 cm. Jejunum wall measured 0.31 cm. Visualized peristalsis appears appropriate. There were no focal lesions consistent with obstruction or a mass effect observed.

The ileocecal junction was visualized and exhibited normal intact wall layering and is subjectively of normal thickness. Sections of colon are visualized with formed fecal material and gas shadowing distally. There is no observed focal or generalized colon wall thickening or loss of layering.

Pancreas

The pancreas is normal and isoechoic to surrounding mesentery. There is no evidence of nodules or cystic lesions. There is no evidence of regional mesenteric inflammation or fluid.

Free Abdomen

Evaluation of the peritoneal cavity did not reveal any evidence of effusion, or subjective lymphadenomegaly. The Medial iliac nodes appear normal and there was no evidence of a caudal aortic thrombus at the bifurcation. The omentum is of normal uniform echogenicity.

ULTRASONOGRAPHIC FINDINGS

- Slightly irregular caudal pole of the left adrenal gland – The significance of this is currently unclear. Recommend continued monitoring for progression of the possible mass effect.
- Numerous large, hyperechoic, cystic, multilobulated mass effects within the liver – Possible differentials would include adenoma, carcinoma, other. These lesions may very well be benign but are very extensive.
- Decreased corticomedullary distinction in both kidneys with small cortical cysts and right-sided mild pyelectasia – The bilateral renal findings are consistent with age-related change. Pyelectasia of the kidney(s) could be consistent with pyelonephritis, chronic renal disease, secondary to PU/PD or fluid therapy (if applicable), other.

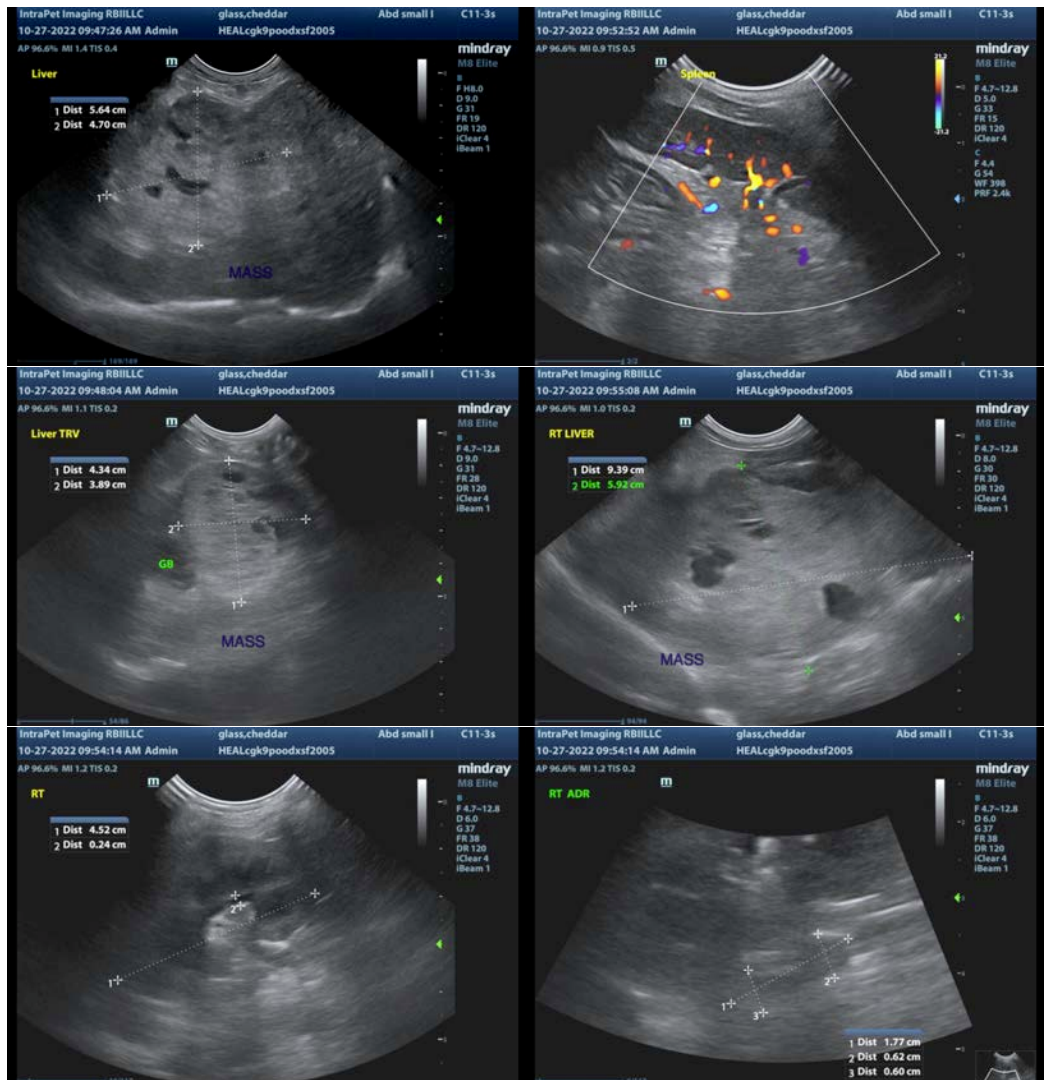
INTERPRETATION OF THE FINDINGS & FURTHER RECOMMENDATIONS

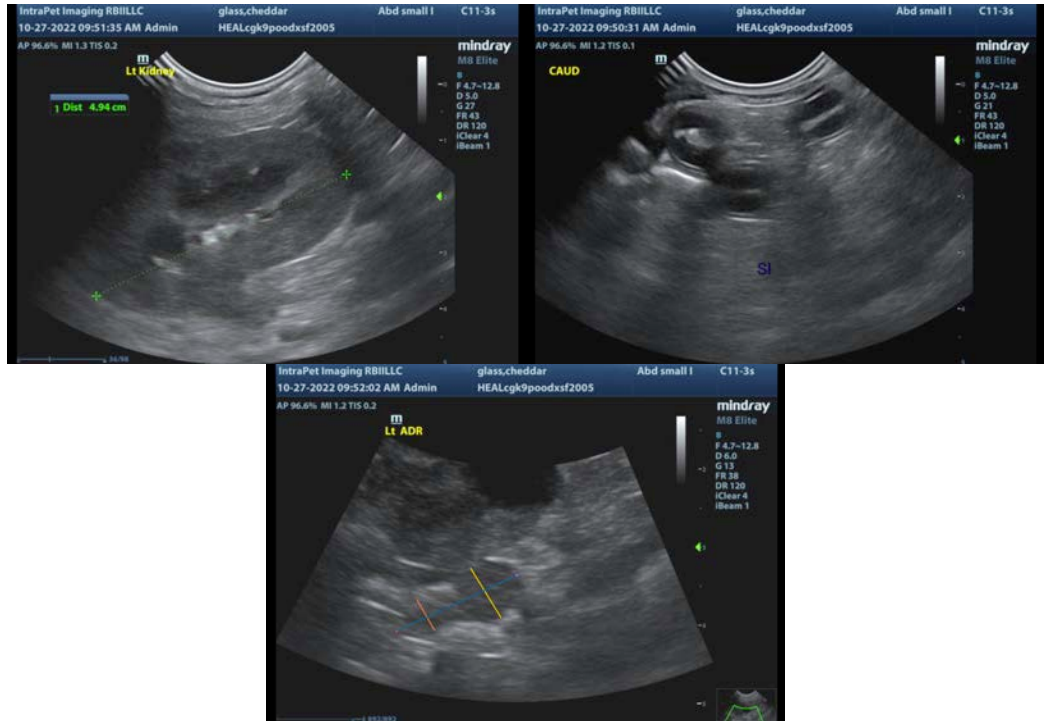
There are numerous large cystic mass effects within the liver. This is the likely source of the liver enzyme elevations. If surgical resection would be considered, a CT scan would be necessary to get a more global view of the extent of these lesions and determine if resection is a possibility. Additionally, you could consider a fine needle aspirate to rule out round cell neoplasia (which I think is very unlikely). These mass lesions could be benign and relatively slow-growing, but at this point they are very large and may be causing discomfort due to their size.

Recommend three view thoracic radiographs to evaluate for possible concurrent thoracic disease/involvement.

The caudal pole of the left adrenal gland appears somewhat enlarged and slightly irregular. Recommend a recheck ultrasound in 4-6 weeks to look for any significant changes, as this could represent an early mass lesion. Alternately, if a CT scan of the liver is performed, recommend concurrent evaluation of the left adrenal gland.

The changes observed in the kidneys are likely associated with age related change. Consider a urinalysis and culture to further evaluate the pyelectasia of the right kidney. Additionally, recommend a blood pressure.





The information and recommendations provided are based on the images presented by the referring veterinarian/sonographer. No evaluation can be communicated regarding pathology that was not visible in the image/video clips provided.

Thank you for this referral. If the clinical or image interpretation does not parallel your findings or if I can be of any further assistance please contact me.

Kathleen Sennello DVM,MS, Diplomate ACVIM (Small animal Internal Medicine)
kathleen.sennello@sonopath.com