



**PATIENT**

Boots Durst

**SPECIES**

Feline

**BREED**

DSH

**SEX**

Neutered Male

**AGE**

10 Years

**WEIGHT**

14.8 Pounds

**INTERPRETED BY**

Kathleen Sennello DVM,  
MS, Diplomate ACVIM  
(Small Animal Internal  
Medicine)

**IMAGING  
PERFORMED BY**

Dr. Sorbo

**HOSPITAL NAME**

Mill Brook AC

**REFERRING VET**

Dr. Sorbo

**INVOICE**

42399

**DATE**

10/27/22

**PRESENTING CLINICAL SIGNS**

Long history of vomiting. Past month vomiting has increased to every other day, sometimes food, sometimes bile. Slight decrease in appetite. Chewing more on things in the house. Hx of dental 3/2022

Abnormal PE/Chem/CBC/UA Results: Weight gain, overweight. Rest of exam WNL. Senior blood work: CREA 2.1, TRIGlycerides 472, no UA yet.

**ULTRASONOGRAPHIC EXAMINATION OF THE ABDOMEN**

**Urinary System**

The urinary bladder is moderately distended with anechoic urine. The Bladder wall, trigone, ureteral papillae and visible urethra (to a depth of 2cm) appear normal with no evidence of wall thickening, mucosal irregularities, masses or cystic calculi.

The left kidney has a normal shape and size (4.16 cm). Overall echogenicity is normal with adequate corticomedullary distinction and a typical 1:3 cortex:medulla ratio. There is no evidence of focal perinephric inflammation or effusion. There is no evidence of pyelectasia, nephroliths, infarcts or hydroureter. Renal vasculature is normal.

The right kidney has a normal shape and size (3.57 cm). Overall echogenicity is normal with adequate corticomedullary distinction and a typical 1:3 cortex:medulla ratio. There is no evidence of focal perinephric inflammation or effusion. There is no evidence of pyelectasia, nephroliths, infarcts or hydroureter. Renal vasculature is normal.

**Adrenal Glands**

The left adrenal gland is normal in size measuring 0.33 cm at the caudal pole. It is observed in its normal position cranial to the left renal artery. It is normal in appearance (uniformly hypoechoic) and shape with no evidence of a mass effect.

The right adrenal gland is normal in size measuring 0.30 cm at the caudal pole. It is observed in its normal position between the cranial aspect of the right kidney and the caudal vena cava. It is normal in appearance (uniformly hypoechoic) and shape with no evidence of a mass effect.

**Spleen**

The spleen is subjectively normal in size (0.83 cm in width at the level of the hilus), echotexture is homogenous, and the splenic capsule is smooth with no irregularities. The blood flow through the hilus and splenic parenchyma appears normal. No focal parenchymal abnormalities are visualized.

**Liver**

The liver is subjectively normal in size, and echogenicity with smooth peripheral margins. The parenchyma is homogenous echotexture. The visible portions of the vasculature and biliary tract appear normal. No focal nodules or cystic lesions are observed.

The gallbladder lumen is moderately distended. The wall of the gall bladder is not thickened and has a smooth mucosal surface. Luminal contents are mild and primarily anechoic. The cystic and common bile ducts are normal/not visible.

**Gastrointestinal**

The stomach contains minimal luminal contents. It appears normal but measures slightly thickened at 0.41 cm with some variability due to the presence of rugal folds. The distinction of the gastric wall layers



**PATIENT**

Boots Durst

is adequate and there is no impression of reduced peristaltic activity. The stomach appears relatively normal, although the wall measures as slightly thickened, and there appears to be some fluid in the pyloric region.

**SPECIES**

Feline

The visualized areas of duodenum, jejunum and ileum have a relatively uniform diameter with minimal fluid distension. Wall thickness is normal. Bowel loops follow a curvilinear path with distinct wall layering maintaining the typical 1:3 muscularis:mucosa layer ratio. Jejunum wall measures 0.22 cm. Visualized peristalsis appears appropriate. There were no focal lesions consistent with obstruction or a mass effect observed.

**BREED**

DSH

The ileocecal junction was visualized and exhibited normal intact wall layering and is subjectively of normal thickness. Sections of colon are visualized with formed fecal material and gas shadowing distally. There is no observed focal or generalized colon wall thickening or loss of layering.

**SEX**

**Pancreas**

Neutered Male

The pancreas is normal and isoechoic to surrounding mesentery. There is no evidence of nodules or cystic lesions. There is no evidence of regional mesenteric inflammation or fluid.

**AGE**

**Free Abdomen**

10 Years

Evaluation of the peritoneal cavity did not reveal any evidence of effusion, or subjective lymphadenomegaly. The Medial iliac nodes appear normal and there was no evidence of a caudal aortic thrombus at the bifurcation. The omentum is of normal uniform echogenicity.

**WEIGHT**

14.8 Pounds

**ULTRASONOGRAPHIC FINDINGS**

- Questionably prominent gastric wall with intact layering – Findings are likely consistent with mild gastritis or artifactual thickening of the gastric wall.

**INTERPRETED BY**

**INTERPRETATION OF THE FINDINGS & FURTHER RECOMMENDATIONS**

Kathleen Sennello DVM,  
MS, Diplomate ACVIM  
(Small Animal Internal  
Medicine)

No significant lesions are visualized on today's exam. The gastric wall may be slightly thickened, but there is intact wall layering. There is a small amount of fluid within the pyloric region, which could indicate delayed gastric emptying, a recent drink, etc. Based on the chronicity of this issue, I would consider obtaining GI biopsies endoscopically, provided bloodwork is normal and there are no significant metabolic reasons for vomiting. Prior to taking that next step, consider:

**IMAGING PERFORMED BY**

- Consider a novel protein/hydrolyzed protein diet (exclusively at least 4-6 weeks)
- Consider a GI panel to Texas A&M for evaluation of B12 levels, folate, PLI/TLI etc.. to further evaluate for pancreatic/small intestinal disease.
- Consider chronic probiotic therapy.
- Recommend three view thoracic radiographs to evaluate for possible concurrent thoracic disease/involvement.

Dr. Sorbo

**HOSPITAL NAME**

Mill Brook AC

**REFERRING VET**

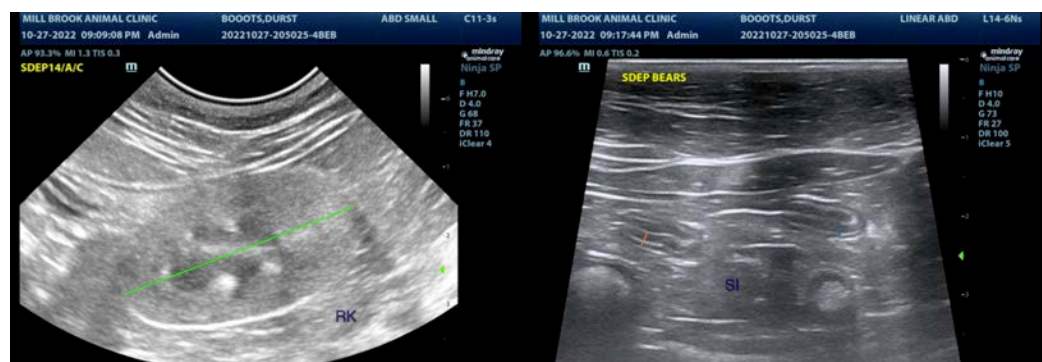
Dr. Sorbo

**INVOICE**

42399

**DATE**

10/27/22





**PATIENT**

Boots Durst

**SPECIES**

Feline

**BREED**

DSH

**SEX**

Neutered Male

**AGE**

10 Years

**WEIGHT**

14.8 Pounds

**INTERPRETED BY**

Kathleen Sennello DVM,  
MS, Diplomate ACVIM  
(Small Animal Internal  
Medicine)

**IMAGING  
PERFORMED BY**

Dr. Sorbo

**HOSPITAL NAME**

Mill Brook AC

**REFERRING VET**

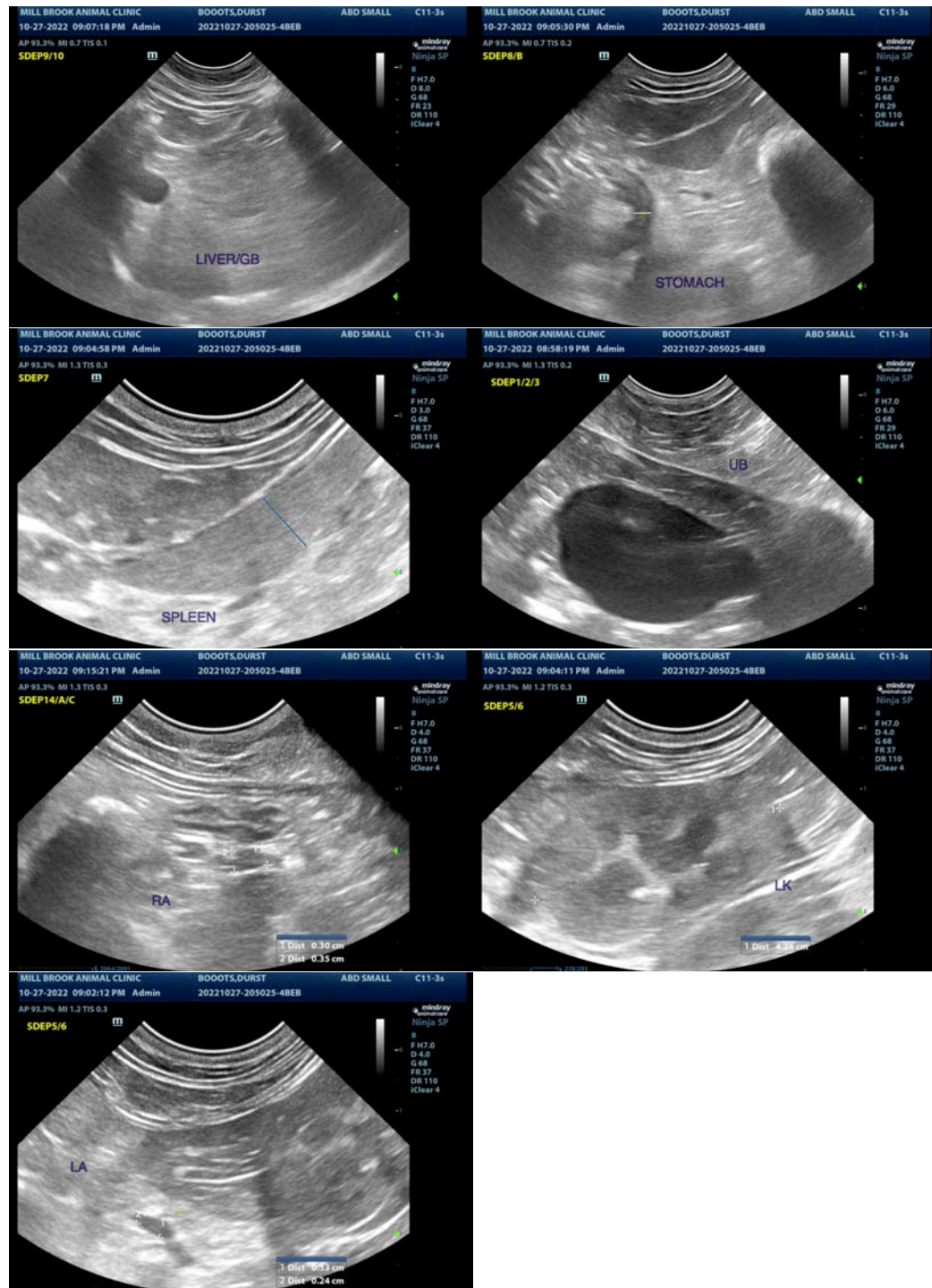
Dr. Sorbo

**INVOICE**

42399

**DATE**

10/27/22





**PATIENT**

Boots Durst

The information and recommendations provided are based on the images presented by the referring veterinarian/sonographer. No evaluation can be communicated regarding pathology that was not visible in the image/video clips provided.

**SPECIES**

Feline

Thank you for this referral. If the clinical or image interpretation does not parallel your findings or if I can be of any further assistance please contact me.

Kathleen Sennello DVM,MS, Diplomate ACVIM (Small animal Internal Medicine)

kathleen.sennello@sonopath.com

**BREED**

DSH

**SEX**

Neutered Male

**AGE**

10 Years

**WEIGHT**

14.8 Pounds

**INTERPRETED BY**

Kathleen Sennello DVM,  
MS, Diplomate ACVIM  
(Small Animal Internal  
Medicine)

**IMAGING  
PERFORMED BY**

Dr. Sorbo

**HOSPITAL NAME**

Mill Brook AC

**REFERRING VET**

Dr. Sorbo

**INVOICE**

42399

**DATE**

10/27/22