



**PATIENT**

Missy Freeman

**PRESENTING CLINICAL SIGNS**

**SPECIES**

Canine

"Missy" Owner is Cathy Freeman Weight is 39.15 kg Age is 8 years old. She is a spayed female labrador. Current medications include 50mg Proin EOD. And phenobarb 97.2mg bid. Presenting complaint is seizures. 7 gran mal seizures in past 20 hours as of 7-9-21. Had one seizure during the ultrasound lasting about 45 seconds. Did not have any seizures since starting the medication in July. Was sedated with 10mg xylazine and 0.5cc dolorex for the ultrasound. Dr. Kelly increased the phenobarb to 1.5 of the 97.2mg tablets bid

**BREED**

Labrador

**ULTRASONOGRAPHIC EXAMINATION OF THE ABDOMEN**

**SEX**

Spayed Female

**Urinary System**

The urinary bladder is moderately distended with anechoic urine. The Bladder wall, trigone, ureteral papillae and visible urethra (to a depth of 2cm) appear normal with no evidence of wall thickening, mucosal irregularities, masses or cystic calculi.

**AGE**

8 Years

The left kidney has a normal shape and size (5.74 cm) with pinpoint non-obstructive nephroliths. Overall echogenicity is normal with adequate corticomedullary distinction and a typical 1:3 cortex:medulla ratio. There is no evidence of perinephric inflammation or effusion. There is no evidence of pyelectasia, infarcts or hydroureter. Renal vasculature is normal.

**WEIGHT**

39.15 kg

The right kidney has a normal shape and size (6.48 cm) with rare pinpoint non-obstructive nephroliths. Overall echogenicity is normal with adequate corticomedullary distinction and a typical 1:3 cortex:medulla ratio. There is no evidence of perinephric inflammation or effusion. There is no evidence of pyelectasia, infarcts or hydroureter. Renal vasculature is normal.

**INTERPRETED BY**

Kathleen Sennello DVM,  
MS, Diplomate ACVIM  
(Small Animal Internal  
Medicine)

**Adrenal Glands**

The left adrenal gland is normal in size measuring 0.56 cm at the caudal pole. It is observed in its normal position cranial to the left renal artery. It is normal in appearance (uniformly hypoechoic) and shape with no evidence of a mass effect.

**IMAGING PERFORMED BY**

Loetitia Saint-Jacques, RVT

The right adrenal gland is normal in size measuring 0.56 cm at the caudal pole. It is observed in its normal position between the cranial aspect of the right kidney and the caudal vena cava. It is normal in appearance (uniformly hypoechoic) and shape with no evidence of a mass effect.

**HOSPITAL NAME**

Roundhill AH

**Spleen**

The spleen is subjectively normal in size, echotexture is homogenous, and the splenic capsule is smooth with no irregularities. The blood flow through the hilus and splenic parenchyma appears normal. No focal parenchymal abnormalities are visualized.

**REFERRING VET**

Dr. Carl Kelly

**Liver**

The liver is large in size and normal in echogenicity with smooth peripheral margins. The parenchyma is heterogenous in echotexture with subtle, indistinct focal mottling. The visible portions of the vasculature and biliary tract appear normal. No focal nodules or cystic lesions are observed.

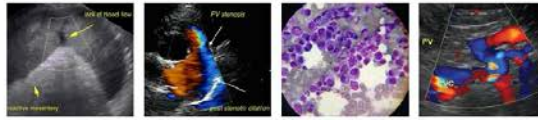
**INVOICE**

26717

The gall bladder lumen is moderately distended. The wall of the gall bladder is not thickened and has a smooth mucosal surface. There is a mild amount of non-organized echogenic debris. The cystic and common bile ducts are normal/not visible.

**DATE**

10/27/21



**PATIENT**

Missy Freeman

**Gastrointestinal**

**SPECIES**

Canine

**BREED**

Labrador

**SEX**

Spayed Female

**AGE**

8 Years

**WEIGHT**

39.15 kg

The stomach contains minimal luminal contents. It measures at a normal thickness of <0.7cm with some variability due to the presence of rugal folds. The distinction of the gastric wall layers is adequate and there is no impression of reduced peristaltic activity. No masses or focal lesions were observed.

The visualized areas of duodenum, jejunum and ileum have a relatively uniform diameter with minimal fluid distension. Wall thickness is normal. Bowel loops follow a curvilinear path with distinct wall layering maintaining the typical 1:3 muscularis:mucosa layer ratio. Duodenum wall measured 0.53 cm. Jejunum wall measured 0.45 cm. Visualized peristalsis appears appropriate. There were no focal lesions consistent with obstruction or a mass effect observed.

The ileocecal junction was visualized and exhibited normal intact wall layering and is subjectively of normal thickness. Sections of colon are visualized with formed fecal material and gas shadowing distally. There is no observed focal or generalized colon wall thickening or loss of layering.

**Pancreas**

The pancreas is normal and isoechoic to surrounding mesentery. There is no evidence of nodules or cystic lesions. There is no evidence of regional mesenteric inflammation or fluid.

**Free Abdomen**

Evaluation of the peritoneal cavity did not reveal any evidence of effusion, or subjective lymphadenomegaly. The Medial iliac nodes appear normal and there was no evidence of a caudal aortic thrombus at the bifurcation. The omentum is of normal uniform echogenicity.

**INTERPRETED BY**

Kathleen Sennello DVM,  
MS, Diplomate ACVIM  
(Small Animal Internal  
Medicine)

**Other**

A brief view of the heart was submitted. No significant pericardial effusion was seen.

**IMAGING PERFORMED BY**

Loetitia Saint-Jacques, RVT

**PRIMARY FINDINGS**

- Large, heterogeneous liver – The diffuse hepatic changes are non-specific and could be consistent with vacuolar hepatopathy, nodular hyperplasia, inflammatory/immune-mediated disease, fibrosis, extramedullary hematopoiesis, toxic hepatopathy (e.g., copper), infiltrative neoplasia (less likely) or other hepatopathy. This is relatively mild and likely secondary to the Phenobarbital therapy.

**HOSPITAL NAME**

Roundhill AH

**SECONDARY FINDINGS**

- Piinpoint non-obstructive nephroliths in both kidneys – The hyperechoic mineralized foci observed at the corticomedullary junction of the left/right kidney are consistent with small, non-obstructive nephroliths.
- Mild gallbladder debris – The gastric distension and hypomotility could be consistent with focal ileus or a proximal duodenal obstruction.

**REFERRING VET**

Dr. Carl Kelly

**INVOICE**

26717

**DATE**

10/27/21

**INTERPRETATION OF THE FINDINGS & FURTHER RECOMMENDATIONS**

Today's scan is relatively normal for a dog on Phenobarbital. No mass lesions were identified. Correlate with blood work findings to further evaluate for metabolic causes of seizures. If this is thought unlikely, recommended 3-view thoracic radiographs and referral to/consultation with a veterinary neurologist about alternative anti-seizure therapies. These can be more efficacious and have fewer side effects than the Phenobarbital.



**PATIENT**

Missy Freeman

**SPECIES**

Canine

**BREED**

Labrador

**SEX**

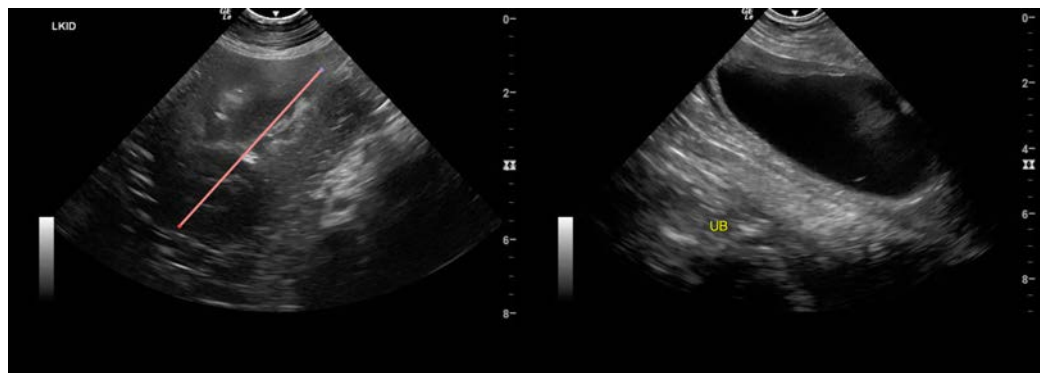
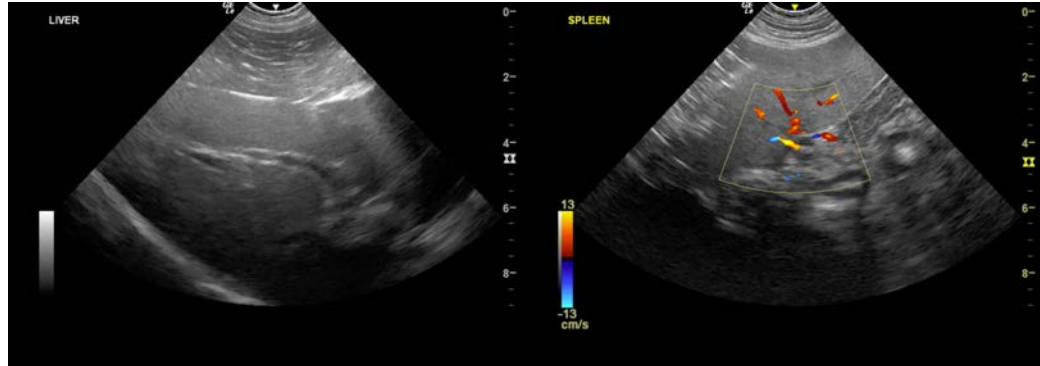
Spayed Female

**AGE**

8 Years

**WEIGHT**

39.15 kg



**INTERPRETED BY**

Kathleen Sennello DVM,  
MS, Diplomate ACVIM  
(Small Animal Internal  
Medicine)

**IMAGING PERFORMED BY**

Loetitia Saint-Jacques, RVT

**HOSPITAL NAME**

Roundhill AH

**REFERRING VET**

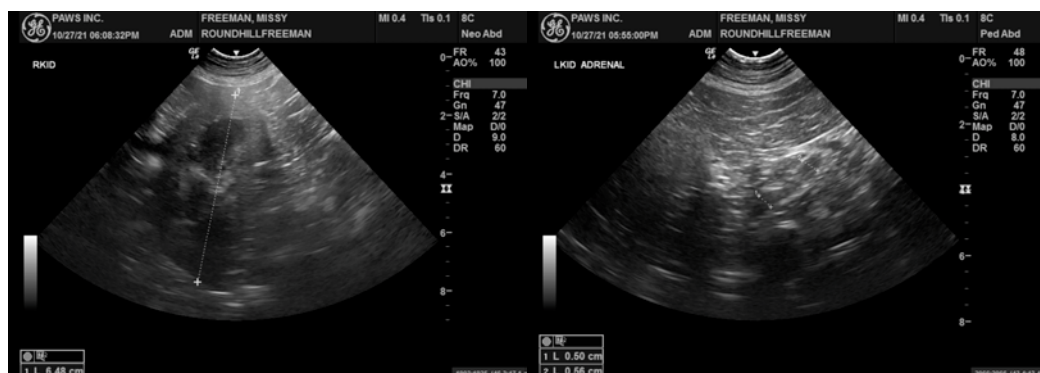
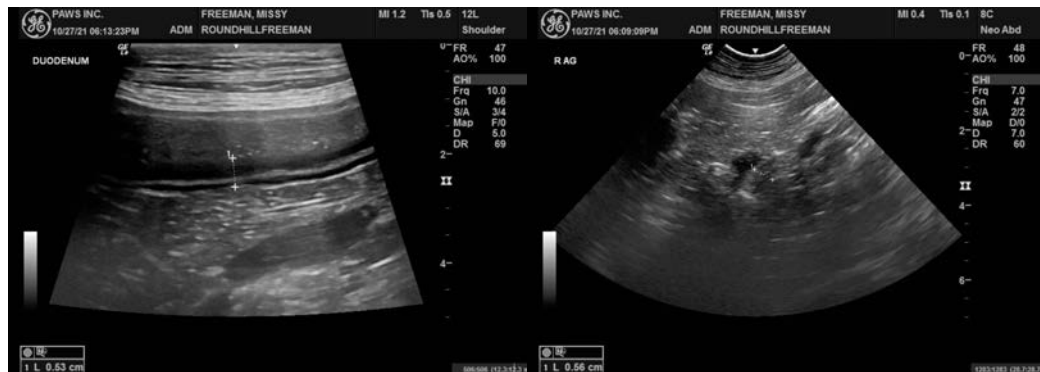Dr. Carl Kelly

**INVOICE**

26717

**DATE**

10/27/21





**PATIENT**

Missy Freeman

The information and recommendations provided are based on the images presented by the referring veterinarian. No evaluation can be communicated regarding pathology that was not visible in the image/video clips provided.

**SPECIES**

Canine

Thank you for this referral. If the clinical or image interpretation does not parallel your findings or if I can be of any further assistance please contact me.

**BREED**

Labrador

Kathleen Sennello DVM,MS, Diplomate ACVIM (Small animal Internal Medicine)

kathleen.sennello@sonopath.com

**SEX**

Spayed Female

**AGE**

8 Years

**WEIGHT**

39.15 kg

**INTERPRETED BY**

Kathleen Sennello DVM,  
MS, Diplomate ACVIM  
(Small Animal Internal  
Medicine)

**IMAGING PERFORMED  
BY**

Loetitia Saint-Jacques, RVT

**HOSPITAL NAME**

Roundhill AH

**REFERRING VET**

Dr. Carl Kelly

**INVOICE**

26717

**DATE**

10/27/21