

**PATIENT**

Juno Dahm

**PRESENTING CLINICAL SIGNS**

**SPECIES**

Canine

1) Acute neurologic event resulting in head tilt, nystagmus, ataxia A2) One episode of vomiting last night A3) Non regenerative anemia: 29% today, down from 39% four weeks ago A4) Splenic nodules A5) Scant pericardial effusion (DVM fast scan)  
Abnormal PE/Chem/CBC/UA Results: aspirate of abdominal fluid was blood

**BREED**

Golden Retriever

**ULTRASONOGRAPHIC EXAMINATION OF THE ABDOMEN**

**Urinary System**

**SEX**

Neutered Male

The urinary bladder is minimally distended with anechoic urine. The Bladder wall, trigone, ureteral papillae and visible urethra (to a depth of 2cm) appear normal with no evidence of wall thickening, mucosal irregularities, masses or cystic calculi.

**AGE**

13 Years

The visualized areas of prostate and surrounding tissue appear normal. Unfortunately, the prostate is not fully visualized likely due to its intrapelvic location. Correlate with rectal exam findings.

**WEIGHT**

69 Pounds

The left kidney has a normal shape and size (6.4 cm). Overall echogenicity is normal with adequate corticomedullary distinction and a typical 1:3 cortex:medulla ratio. There is no evidence of perinephric inflammation or effusion. There is no evidence of pyelectasia, nephroliths, infarcts or hydroureter. Renal vasculature is normal.

The right kidney has a normal shape and size (5.65 cm). Overall echogenicity is normal with adequate corticomedullary distinction and a typical 1:3 cortex:medulla ratio. There is no evidence of perinephric inflammation or effusion. There is no evidence of pyelectasia, nephroliths, infarcts or hydroureter. Renal vasculature is normal.

**INTERPRETED BY**

Kathleen Sennello DVM,  
MS, Diplomate ACVIM  
(Small Animal Internal  
Medicine)

**Adrenal Glands**

The left adrenal gland is normal in size measuring 0.77 cm at the caudal pole. It is observed in its normal position cranial to the left renal artery. It is normal in appearance (uniformly hypoechoic) and shape with no evidence of a mass effect.

**IMAGING PERFORMED BY**

Loetitia Saint-Jacques, RVT

The right adrenal gland is difficult to visualized, but glimpses of it are seen and it appears to be normal.

**HOSPITAL NAME**

Donner Truckee VH

**Spleen**

The spleen is subjectively normal in size. The spleen echotexture is heterogenous and mottled, the splenic capsule is smooth with no irregularities. The blood flow through the hilus and splenic parenchyma appears normal. There are at least two hypoechoic nodules visualized in the spleen. The larger nodule is hypoechoic, solid, and mildly expansile, measuring 2.28 cm x 2.82 cm (previous measurement 1.8 cm x 2.7 cm). The other hypoechoic nodule is non-cavitated and visualized within the parenchyma, measuring 2.19 cm x 2.84 cm (previous measurement approximately 1.2 cm). Additionally, there are numerous hyperechoic foci throughout the spleen, most consistent with benign myelolipomas.

**REFERRING VET**

Dr. Vannini

**Liver**

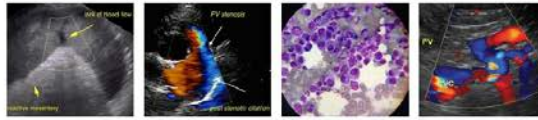
**INVOICE**

26679

The liver is subjectively normal in size, and echogenicity with smooth peripheral margins. The parenchyma is heterogenous in echotexture with subtle, indistinct focal mottling. The visible portions of the vasculature and biliary tract appear normal. There is an isoechoic mass effect within the hepatic parenchyma, measuring 2.93 cm x 1.36 cm (this is suspected to have measured 1.6 cm at the last evaluation). Additionally, there is a large mixed echogenic solid, irregular mass effect in the right cranial abdomen, which appears to be touching the liver. it is also in the area of the pancreas and right adrenal.

**DATE**

10/27/21



**PATIENT**

Juno Dahm The gall bladder lumen is moderately distended. The wall of the gall bladder is not thickened and has a smooth mucosal surface. There is a large amount of primarily non-organized echogenic debris, but early organization is evident, making this consistent with an early mucocele. There is no evidence of bile duct dilation.

**SPECIES**

Canine **Gastrointestinal**

**BREED**

Golden Retriever The stomach contains minimal luminal contents. It measures at a normal thickness of <0.7cm with some variability due to the presence of rugal folds. The distinction of the gastric wall layers is adequate and there is no impression of reduced peristaltic activity. No masses or focal lesions were observed.

**SEX**

Neutered Male The visualized areas of duodenum, jejunum and ileum have a relatively uniform diameter with minimal fluid distension. Wall thickness is normal. Bowel loops follow a curvilinear path with distinct wall layering maintaining the typical 1:3 muscularis:mucosa layer ratio. The duodenum measured as normal (between 0.3-0.5cm in wall thickness) and the jejunum measured as normal (between 0.2-0.47cm.) Visualized peristalsis appears appropriate. There were no focal lesions consistent with obstruction or a mass effect observed.

**AGE**

13 Years The ileocecal junction was visualized and exhibited normal intact wall layering and is subjectively of normal thickness. Sections of colon are visualized with formed fecal material and gas shadowing distally. There is no observed focal or generalized colon wall thickening or loss of layering.

**WEIGHT**

69 Pounds **Pancreas**  
The pancreas is normal and isoechoic to surrounding mesentery. There is a large mass effect in the right cranial thorax, which is in the area of the liver, cranial aspect of the right limb of the pancreas and the right adrenal gland. I suspect pancreatic origin is less likely, but possible. There is no evidence of regional mesenteric inflammation or fluid.

**INTERPRETED BY**

Kathleen Sennello DVM,  
MS, Diplomate ACVIM  
(Small Animal Internal  
Medicine)

**Free Abdomen**

There is a moderate amount of echogenic free fluid (sampled to be consistent with blood). There is no lymphadenopathy. The omentum is generally of increased echogenicity, particularly in the right cranial abdomen.

**IMAGING PERFORMED BY**

Loetitia Saint-Jacques, RVT

**Other**

No pericardial effusion is visualized, but there is a hypoechoic structure adjacent to the heart, measuring 3.7 cm. Recommend cardiac ultrasound/thoracic CT to further evaluate.

**HOSPITAL NAME**

Donner Truckee VH

**ULTRASONOGRAPHIC FINDINGS**

**REFERRING VET**

Dr. Vannini

- Large mass effect in the right cranial abdomen – This mass was not reported in the last scan, so it is likely rapidly growing/evolving. The organ of origin is not clear. Consider liver, pancreas, and right adrenal as possibilities.
- Heterogeneous liver with isoechoic intraparenchymal nodule – The diffuse hepatic changes are non-specific and could be consistent with vacuolar hepatopathy, nodular hyperplasia, inflammatory/immune-mediated disease, fibrosis, extramedullary hematopoiesis, toxic hepatopathy (e.g., copper), infiltrative neoplasia (less likely) or other hepatopathy.
- Hypoechoic splenic nodules – Both nodules previously described appear larger than previous measurements. There are several, non-cavitated, hypoechoic splenic nodules visualized. Differentials include lymphoid hyperplasia, extramedullary hematopoiesis, infiltrative

**INVOICE**

26679

**DATE**

10/27/21



**PATIENT**

Juno Dahm neoplasia, inflammation, other. Cytology or histopathology would be necessary to get a definitive diagnosis.

**SPECIES**

Canine

- Early gallbladder mucocele – The gallbladder debris is starting to organized and adhere to the gallbladder wall. This should be monitored closely for the need for surgical intervention. Recommend starting Ursodiol.

**BREED**

Golden Retriever

- Moderate amount of free abdominal fluid – Sampling per history is consistent with a hemoabdomen.
- Concern for possible intrathoracic lesions adjacent to the heart – Recommend cardiac ultrasound or thoracic CT (provided radiographs to not show a lesion).

**SEX**

Neutered Male

**INTERPRETATION OF THE FINDINGS & FURTHER RECOMMENDATIONS**

**AGE**

13 Years

There are numerous mass effects within the abdomen, and a suspected hemoabdomen. The source of the bleeding is not clear, but there are several possibilities. The mass lesion in the right cranial abdomen is very concerning in that it appears to be rapidly developing, and its organ of origin is not 100% clear. There are nodules in the liver and spleen. This could represent metastatic disease, but can also represent concurrent regenerative nodules, benign lesions, etc.

**WEIGHT**

69 Pounds

The ideal situation would be to have a whole body CT scan to evaluate the thorax and abdominal structures to try to determine a surgical plan. If this is not possible, you could consider an abdominal exploratory due to the hemoabdomen, but recommend an experienced veterinary surgeon, as this could be associated with a complicated removal/vascular invasion, etc.

**INTERPRETED BY**

Kathleen Sennello DVM,  
MS, Diplomate ACVIM  
(Small Animal Internal  
Medicine)

**IMAGING PERFORMED BY**

Loetitia Saint-Jacques, RVT

**HOSPITAL NAME**

Donner Truckee VH

**REFERRING VET**

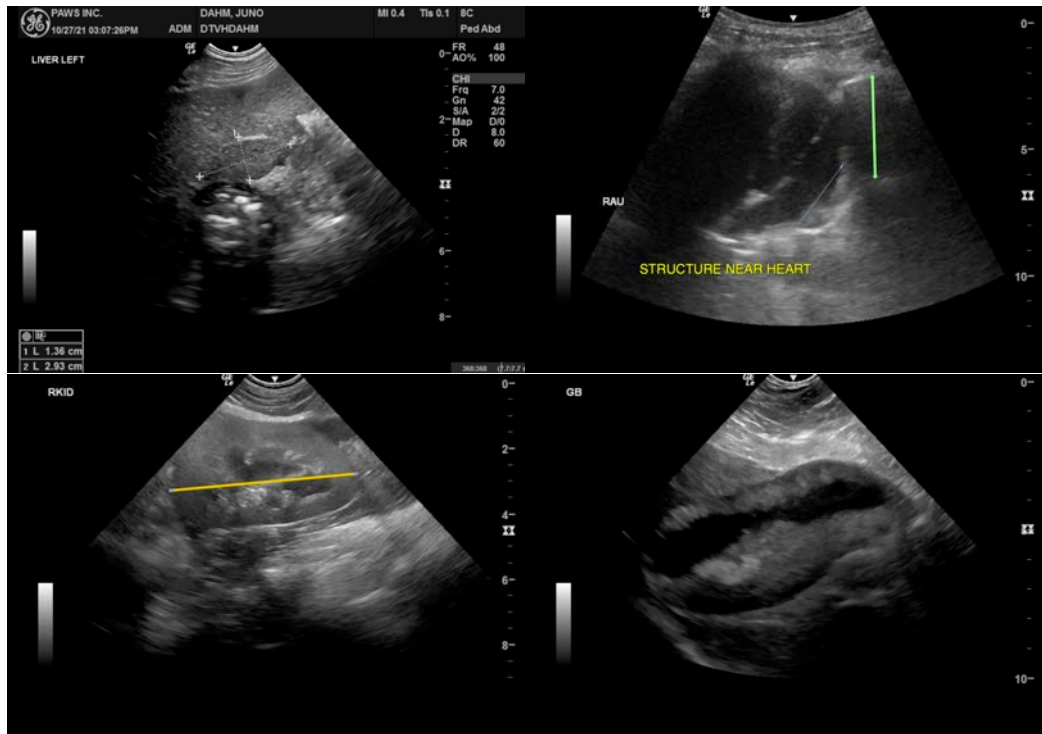
Dr. Vannini

**INVOICE**

26679

**DATE**

10/27/21





**PATIENT**

Juno Dahm

**SPECIES**

Canine

**BREED**

Golden Retriever

**SEX**

Neutered Male

**AGE**

13 Years

**WEIGHT**

69 Pounds

**INTERPRETED BY**

Kathleen Sennello DVM,  
MS, Diplomate ACVIM  
(Small Animal Internal  
Medicine)

**IMAGING PERFORMED BY**

Loetitia Saint-Jacques, RVT

**HOSPITAL NAME**

Donner Truckee VH

**REFERRING VET**

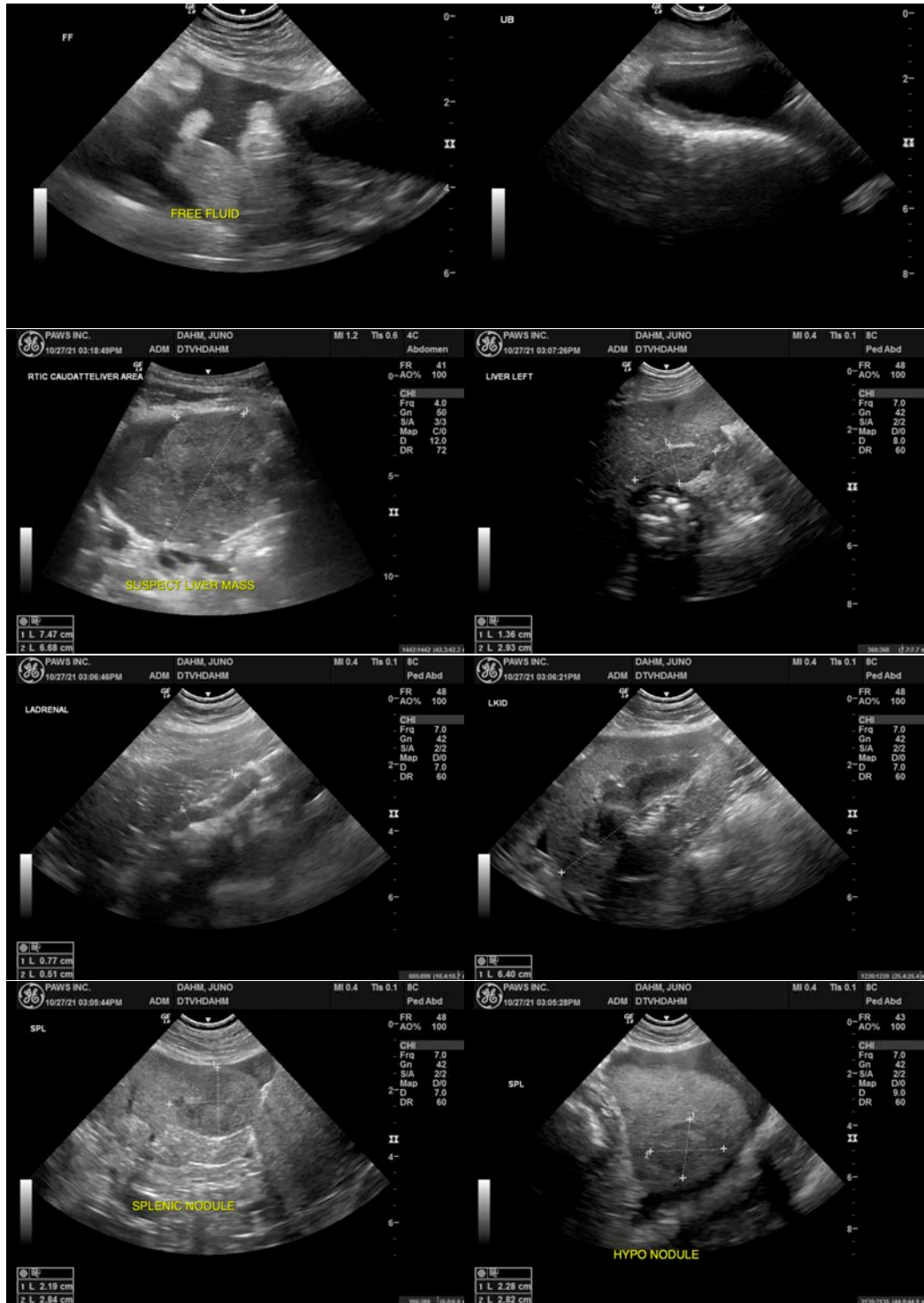
Dr. Vannini

**INVOICE**

26679

**DATE**

10/27/21





**PATIENT**

Juno Dahm

The information and recommendations provided are based on the images presented by the referring veterinarian. No evaluation can be communicated regarding pathology that was not visible in the image/video clips provided.

**SPECIES**

Canine

Thank you for this referral. If the clinical or image interpretation does not parallel your findings or if I can be of any further assistance please contact me.

**BREED**

Golden Retriever

Kathleen Sennello DVM,MS, Diplomate ACVIM (Small animal Internal Medicine)

kathleen.sennello@sonopath.com

**SEX**

Neutered Male

**AGE**

13 Years

**WEIGHT**

69 Pounds

**INTERPRETED BY**

Kathleen Sennello DVM,  
MS, Diplomate ACVIM  
(Small Animal Internal  
Medicine)

**IMAGING PERFORMED BY**

Loetitia Saint-Jacques, RVT

**HOSPITAL NAME**

Donner Truckee VH

**REFERRING VET**

Dr. Vannini

**INVOICE**

26679

**DATE**

10/27/21