



PATIENT

Henry Seamen

SPECIES

Canine

BREED

Brussels Griffon

SEX

Neutered Male

AGE

9 Years

WEIGHT

13 Pounds

INTERPRETED BY

Kathleen Sennello DVM,
MS, Diplomate ACVIM
(Small Animal Internal
Medicine)

IMAGING PERFORMED BY

Kelly Vazquez

HOSPITAL NAME

Westwood Regional

REFERRING VET

Dr. Aronow

INVOICE

42354

DATE

10/26/22

PRESENTING CLINICAL SIGNS

1 day of acute vomiting/diarrhea, severe painful mid abdomen, restless. (Ongoing history of G.I.sensitivity, but well managed on Venison based diet). Was on Apoquel + anti-inflammatory for 3 days, discontinued 3 days ago.

Abnormal PE/Chem/CBC/UA Results: Bloods: pending.

ULTRASONOGRAPHIC EXAMINATION OF THE ABDOMEN

Urinary System

The urinary bladder is moderately distended with anechoic urine. The Bladder wall, trigone, ureteral papillae and visible urethra (to a depth of 2cm) appear normal with no evidence of wall thickening, mucosal irregularities, masses or cystic calculi.

The visualized areas of prostate and surrounding tissue appear normal. Unfortunately, the prostate is not fully visualized likely due to its intrapelvic location. Correlate with rectal exam findings.

The left kidney has a normal shape and size (3.6 cm). Overall echogenicity is normal with adequate corticomedullary distinction and a typical 1:3 cortex:medulla ratio. There is no evidence of focal perinephric inflammation or effusion. There is no evidence of pyelectasia, nephroliths, infarcts or hydroureter. Renal vasculature is normal.

The right kidney has a normal shape and size (3.47 cm). Overall echogenicity is normal with adequate corticomedullary distinction and a typical 1:3 cortex:medulla ratio. There is no evidence of focal perinephric inflammation or effusion. There is no evidence of pyelectasia, nephroliths, infarcts or hydroureter. Renal vasculature is normal.

Adrenal Glands

The left adrenal gland is normal in size measuring 0.39 cm at the caudal pole. It is observed in its normal position cranial to the left renal artery. It is normal in appearance (uniformly hypoechoic) and shape with no evidence of a mass effect.

The right adrenal gland is normal in size measuring 0.57 cm at the caudal pole. It is observed in its normal position between the cranial aspect of the right kidney and the caudal vena cava. It is normal in appearance (uniformly hypoechoic) and shape with no evidence of a mass effect.

Spleen

The spleen is subjectively normal in size, echotexture is homogenous, and the splenic capsule is smooth with no irregularities. The blood flow through the hilus and splenic parenchyma appears normal. No focal parenchymal abnormalities are visualized.

Liver

The liver is subjectively normal in size, and echogenicity with smooth peripheral margins. The parenchyma is homogenous echotexture. The visible portions of the vasculature and biliary tract appear normal. No focal nodules or cystic lesions are observed.

The gallbladder lumen is moderately distended. The wall of the gall bladder is not thickened and has a smooth mucosal surface. Luminal contents are mild and primarily anechoic. The cystic and common bile ducts are normal/not visible.



PATIENT

Henry Seamen

Gastrointestinal

The stomach contains minimal luminal contents. It measures at a normal thickness of <0.7cm with some variability due to the presence of rugal folds. The distinction of the gastric wall layers is adequate and there is no impression of reduced peristaltic activity. No masses or focal lesions were observed.

SPECIES

Canine

The visualized areas of duodenum, jejunum and ileum have a relatively uniform diameter with minimal fluid distension. Wall thickness is normal. Bowel loops follow a curvilinear path with distinct wall layering maintaining the typical 1:3 muscularis:mucosa layer ratio. Duodenum wall measures 0.48 cm. Jejunum wall measures 0.39 cm. Visualized peristalsis appears appropriate. There were no focal lesions consistent with obstruction or a mass effect observed.

BREED

Brussels Griffon

The ileocecal junction was visualized and exhibited normal intact wall layering and is subjectively of normal thickness. Sections of colon are visualized with formed fecal material and gas shadowing distally. There is no observed focal or generalized colon wall thickening or loss of layering.

SEX

Neutered Male

Pancreas

The pancreas is normal and isoechoic to surrounding mesentery. There is no evidence of nodules or cystic lesions. There is no evidence of regional mesenteric inflammation or fluid.

AGE

9 Years

Free Abdomen

Evaluation of the peritoneal cavity did not reveal any evidence of effusion, or subjective lymphadenomegaly. The Medial iliac nodes appear normal and there was no evidence of a caudal aortic thrombus at the bifurcation. The omentum is slightly hyperechoic in the right cranial abdomen.

WEIGHT

13 Pounds

ULTRASONOGRAPHIC FINDINGS

- Visible left limb of the pancreas with mildly hyperechoic mesentery in the right cranial abdomen – These findings are very subtle but could be consistent with mild focal pancreatic inflammation. Correlate with a cPLI measurement.

INTERPRETED BY

Kathleen Sennello DVM,
MS, Diplomate ACVIM
(Small Animal Internal
Medicine)

INTERPRETATION OF THE FINDINGS & FURTHER RECOMMENDATIONS

Today's scan appears relatively normal considering the significant symptoms described. There is no evidence of an obstruction pattern, and it was difficult to visualize any significant pancreatic inflammation. Findings are likely most consistent with acute gastroenteritis, although pancreatitis and ingested foreign material cannot be completely ruled out. Correlate with an abdominal radiograph and a cPLI measurement. Recommend supportive therapy for gastroenteritis and serial radiographs. If the patient is worsening, consider reimaging or exploratory surgery.

IMAGING PERFORMED BY

Kelly Vazquez

HOSPITAL NAME

Westwood Regional

REFERRING VET

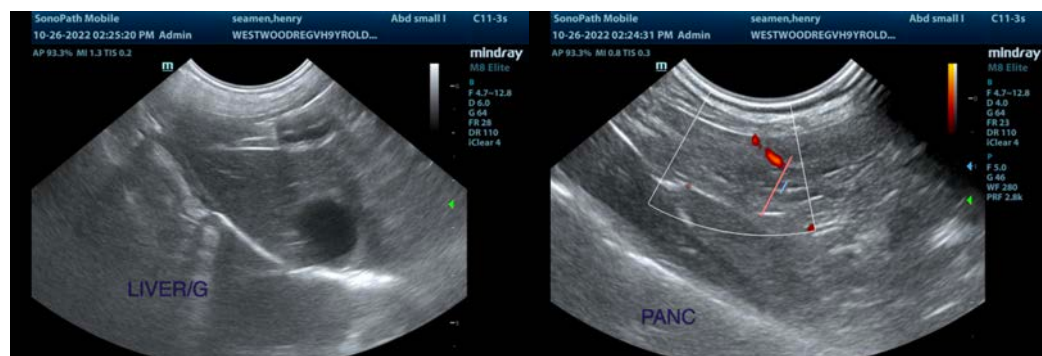
Dr. Aronow

INVOICE

42354

DATE

10/26/22





PATIENT

Henry Seamen

SPECIES

Canine

BREED

Brussels Griffon

SEX

Neutered Male

AGE

9 Years

WEIGHT

13 Pounds

INTERPRETED BY

Kathleen Sennello DVM,
MS, Diplomate ACVIM
(Small Animal Internal
Medicine)

**IMAGING
PERFORMED BY**

Kelly Vazquez

HOSPITAL NAME

Westwood Regional

REFERRING VET

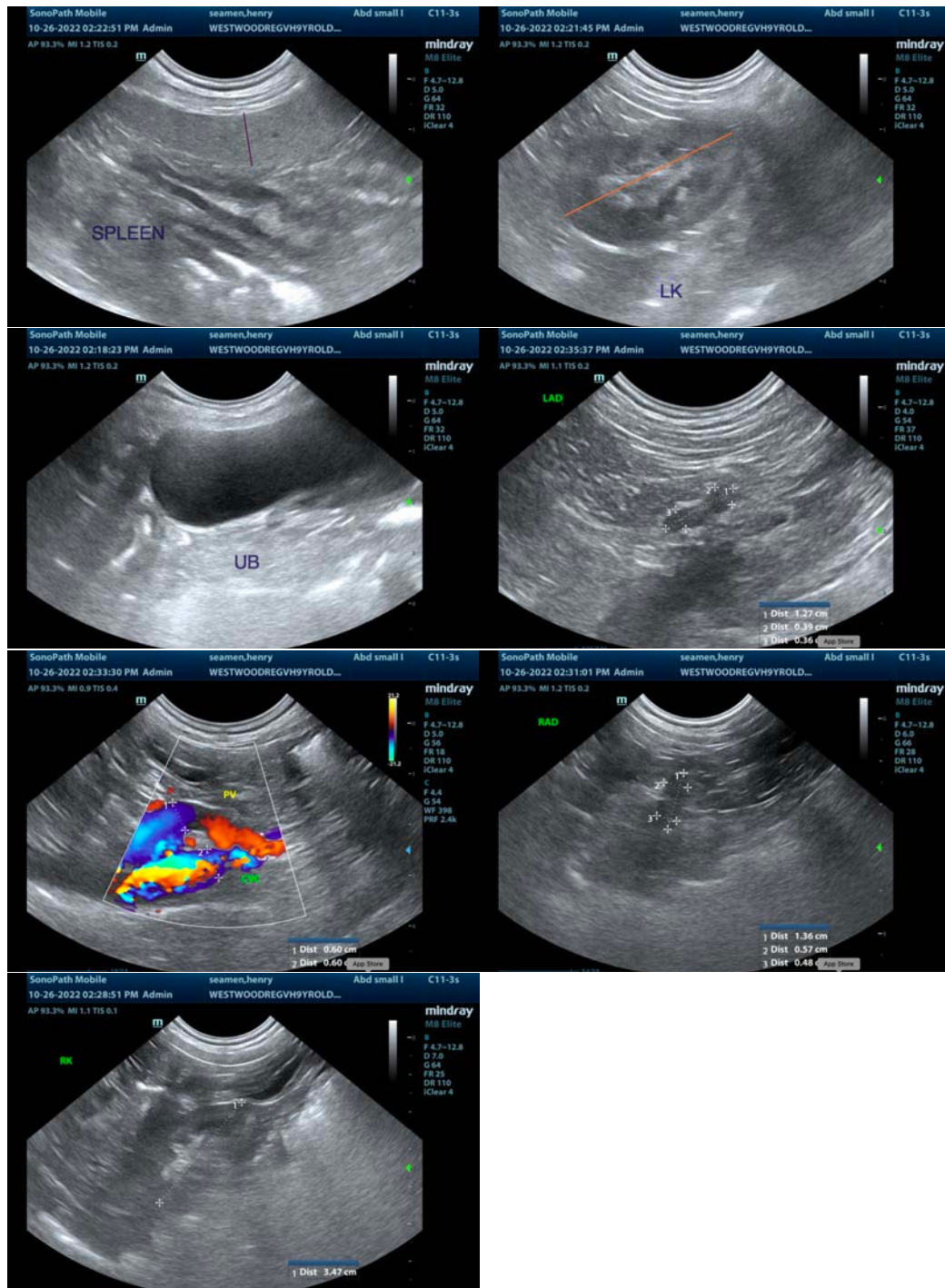
Dr. Aronow

INVOICE

42354

DATE

10/26/22





PATIENT

Henry Seamen

The information and recommendations provided are based on the images presented by the referring veterinarian/sonographer. No evaluation can be communicated regarding pathology that was not visible in the image/video clips provided.

SPECIES

Canine

Thank you for this referral. If the clinical or image interpretation does not parallel your findings or if I can be of any further assistance please contact me.

Kathleen Sennello DVM,MS, Diplomate ACVIM (Small animal Internal Medicine)

BREED

Brussels Griffon

kathleen.sennello@sonopath.com

SEX

Neutered Male

AGE

9 Years

WEIGHT

13 Pounds

INTERPRETED BY

Kathleen Sennello DVM,
MS, Diplomate ACVIM
(Small Animal Internal
Medicine)

**IMAGING
PERFORMED BY**

Kelly Vazquez

HOSPITAL NAME

Westwood Regional

REFERRING VET

Dr. Aronow

INVOICE

42354

DATE

10/26/22