



PATIENT

DeeDee Druar

SPECIES

Canine

BREED

Mini Schnauzer X

SEX

Spayed Female

AGE

9 Years

WEIGHT

11.6 Pounds

INTERPRETED BY

Kathleen Sennello DVM,
MS, Diplomate ACVIM
(Small Animal Internal
Medicine)

**IMAGING
PERFORMED BY**

Dr. Hayley Biederbeck

HOSPITAL NAME

Lomsnes Vet Hospital

REFERRING VET

Dr. Hayley Biederbeck

INVOICE

42362

DATE

10/26/22

PRESENTING CLINICAL SIGNS

Elevated liver values as cause for u/s. Weight is stable, clinically doing well. No fever. Has never been out of Red Deer area and we do not have leptospirosis here. No urinary symptoms or past hx of this.

Abnormal PE/Chem/CBC/UA Results: ALT- 176 (10-125), AlkP 520 (23-212), Alb 4.1 (2.2-3.9), CBC-nsf 4dx-neg

ULTRASONOGRAPHIC EXAMINATION OF THE ABDOMEN

Urinary System

The urinary bladder is moderately distended with anechoic urine. The Bladder wall, trigone, ureteral papillae and visible urethra (to a depth of 2cm) appear normal with no evidence of wall thickening, mucosal irregularities, masses or cystic calculi.

The left kidney has a normal shape and size (4.86 cm). Overall echogenicity is normal with adequate corticomedullary distinction and a typical 1:3 cortex:medulla ratio. There is no evidence of focal perinephric inflammation or effusion. There is no evidence of pyelectasia, nephroliths, infarcts or hydronephrosis. Renal vasculature is normal.

The right kidney has a normal shape and size (5.0 cm). Overall echogenicity is normal with adequate corticomedullary distinction and a typical 1:3 cortex:medulla ratio. There is no evidence of focal perinephric inflammation or effusion. There is no evidence of pyelectasia, nephroliths, infarcts or hydronephrosis. Renal vasculature is normal.

Adrenal Glands

The left adrenal gland is normal in size measuring 0.42 cm at the caudal pole. It is observed in its normal position cranial to the left renal artery. It is normal in appearance (uniformly hypoechoic) and shape with no evidence of a mass effect.

The right adrenal gland is normal in size measuring 0.49 cm at the caudal pole. It is observed in its normal position between the cranial aspect of the right kidney and the caudal vena cava. It is normal in appearance (uniformly hypoechoic) and shape with no evidence of a mass effect.

Spleen

The spleen is subjectively normal in size, echotexture is homogenous, and the splenic capsule is smooth with no irregularities. The blood flow through the hilus and splenic parenchyma appears normal. No focal parenchymal abnormalities are visualized.

Liver

The liver is subjectively normal in size, and echogenicity with smooth peripheral margins. The parenchyma is heterogenous in echotexture with subtle, indistinct focal mottling. The visible portions of the vasculature and biliary tract appear normal. No focal nodules or cystic lesions are observed.

The gall bladder lumen is significantly distended. Some areas of the wall appear mildly thickened with adherent debris. There is a large amount of primarily non-organized echogenic debris. There is no evidence of bile duct dilation.



PATIENT

DeeDee Druar

SPECIES

Canine

BREED

Mini Schnauzer X

SEX

Spayed Female

AGE

9 Years

WEIGHT

11.6 Pounds

INTERPRETED BY

Kathleen Sennello DVM,
MS, Diplomate ACVIM
(Small Animal Internal
Medicine)

**IMAGING
PERFORMED BY**

Dr. Hayley Biederbeck

HOSPITAL NAME

Lomsnes Vet Hospital

REFERRING VET

Dr. Hayley Biederbeck

INVOICE

42362

DATE

10/26/22

Gastrointestinal

The stomach contains minimal luminal contents. It measures at a normal thickness of <0.7cm with some variability due to the presence of rugal folds. The distinction of the gastric wall layers is adequate and there is no impression of reduced peristaltic activity. No masses or focal lesions were observed.

The visualized areas of duodenum, jejunum and ileum have a relatively uniform diameter with minimal fluid distension. Wall thickness is normal. Bowel loops follow a curvilinear path with distinct wall layering maintaining the typical 1:3 muscularis:mucosa layer ratio. Duodenum wall measures 0.42 cm. Jejunum wall measures 0.31 cm. Visualized peristalsis appears appropriate. There were no focal lesions consistent with obstruction or a mass effect observed.

The ileocecal junction was visualized and exhibited normal intact wall layering and is subjectively of normal thickness. Sections of colon are visualized with formed fecal material and gas shadowing distally. There is no observed focal or generalized colon wall thickening or loss of layering.

Pancreas

The pancreas is normal and isoechoic to surrounding mesentery. There is no evidence of nodules or cystic lesions. There is no evidence of regional mesenteric inflammation or fluid.

Free Abdomen

Evaluation of the peritoneal cavity did not reveal any evidence of effusion, or subjective lymphadenomegaly. The Medial iliac nodes appear normal and there was no evidence of a caudal aortic thrombus at the bifurcation. The omentum is of normal uniform echogenicity.

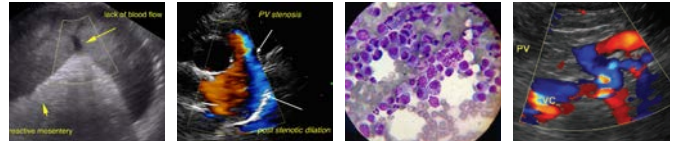
ULTRASONOGRAPHIC FINDINGS

- Heterogeneous liver – The diffuse hepatic changes are non-specific and could be consistent with vacuolar hepatopathy, nodular hyperplasia, inflammatory/immune-mediated disease, fibrosis, extramedullary hematopoiesis, toxic hepatopathy (e.g., copper), infiltrative neoplasia (less likely) or other hepatopathy.
- Large gallbladder debris – A large amount of debris is evident in the gall bladder with no evidence of a mucocele or associated inflammation at this time. This could represent an early mucocele or cholestasis, with minimal evidence of associated inflammation at this time. Continued monitoring of labwork and ultrasound are warranted for progression of this lesion. Ursodiol therapy could be considered.

INTERPRETATION OF THE FINDINGS & FURTHER RECOMMENDATIONS

No focal lesions are visualized on today's exam. The liver appears diffusely heterogeneous. This is a non-specific finding. The gallbladder has a relatively large amount of intraluminal debris, but no wall thickening and there is no surrounding inflammation. I suspect this is a primary hepatopathy, but you could consider the use of Ursodiol to try to prevent progression of the gallbladder changes. Consider the following for further evaluation of the primary hepatopathy:

- Consider close evaluation of history for possible toxic changes examine medications, diet, dietary indiscretion etc...
- Consider PCR on urine/serum for leptospirosis (if not on antibiotics)/serology if recent antibiotic history (You can skip this step if the likelihood of Leptospirosis is very low in your region).



PATIENT

DeeDee Druar

- If not already done, consider pre and post prandial bile acids to evaluate liver function

SPECIES

Canine

- If the ALP is significantly elevated relative to the ALT and symptoms consistent with Cushing's are present, consider adrenal function testing (ACTH stim)

BREED

Mini Schnauzer X

- Consider Fine needle aspirate if round cell neoplasia is on your differential list (25 g needle, normal coags)

- If no response to supportive care (Denamarin, fluids, antibiotics, +/- ursodiol etc.) Consider liver biopsy with samples obtained for histopathology, culture, and copper levels.

SEX

Spayed Female

AGE

9 Years

WEIGHT

11.6 Pounds

INTERPRETED BY

Kathleen Sennello DVM,
MS, Diplomate ACVIM
(Small Animal Internal
Medicine)

IMAGING PERFORMED BY

Dr. Hayley Biederbeck

HOSPITAL NAME

Lomsnes Vet Hospital

REFERRING VET

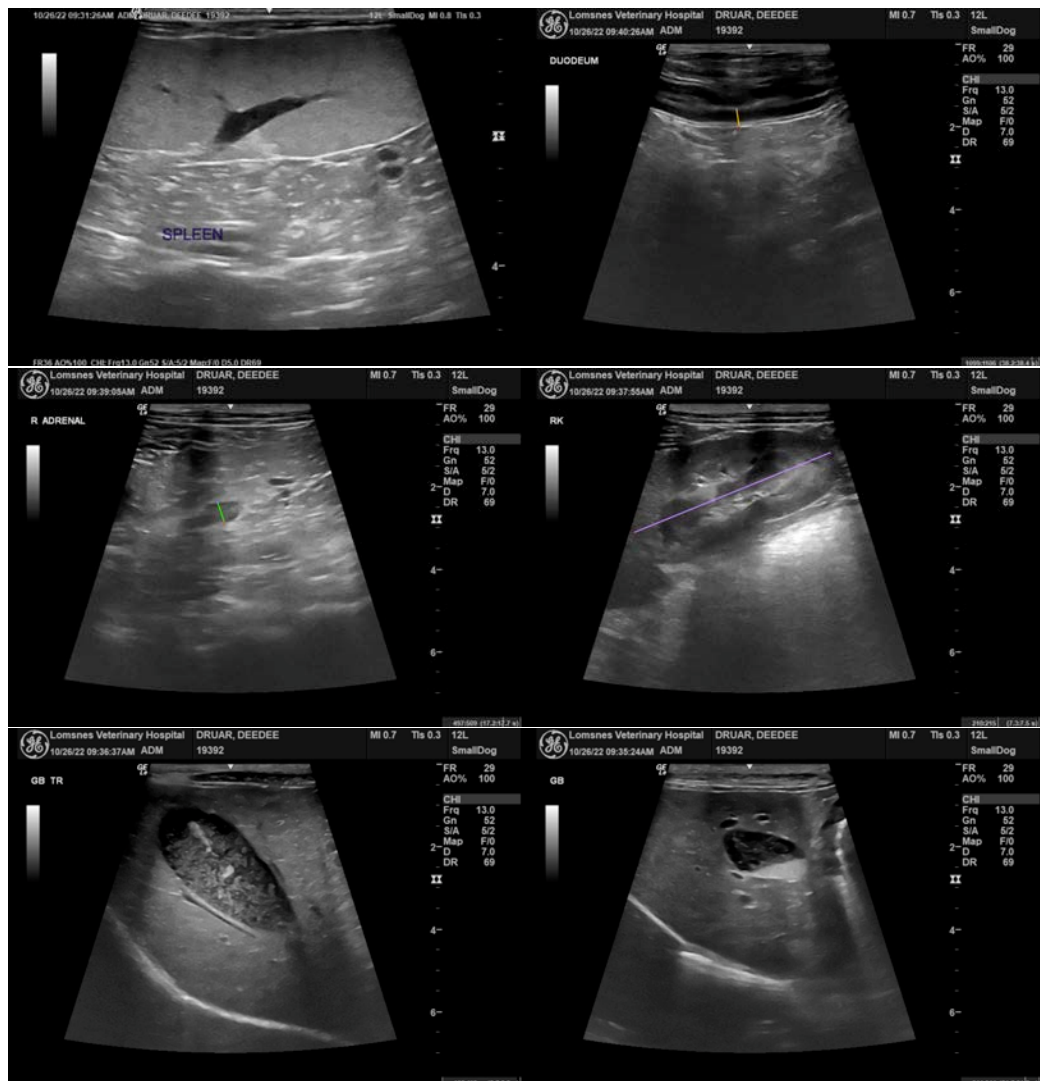
Dr. Hayley Biederbeck

INVOICE

42362

DATE

10/26/22





PATIENT

DeeDee Druar

SPECIES

Canine

BREED

Mini Schnauzer X

SEX

Spayed Female

AGE

9 Years

WEIGHT

11.6 Pounds

INTERPRETED BY

Kathleen Sennello DVM,
MS, Diplomate ACVIM
(Small Animal Internal
Medicine)

**IMAGING
PERFORMED BY**

Dr. Hayley Biederbeck

HOSPITAL NAME

Lomsnes Vet Hospital

REFERRING VET

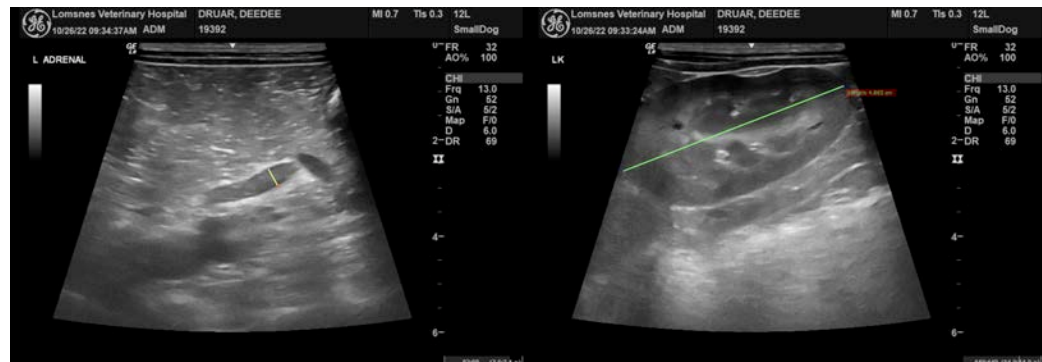
Dr. Hayley Biederbeck

INVOICE

42362

DATE

10/26/22



The information and recommendations provided are based on the images presented by the referring veterinarian/sonographer. No evaluation can be communicated regarding pathology that was not visible in the image/video clips provided.

Thank you for this referral. If the clinical or image interpretation does not parallel your findings or if I can be of any further assistance please contact me.

Kathleen Sennello DVM,MS, Diplomate ACVIM (Small animal Internal Medicine)

kathleen.sennello@sonopath.com