

PATIENT

Zeus Kaur

SPECIES

Canine

BREED

Shiba Inu

SEX

Neutered Male

AGE

3 Years 9 Months

WEIGHT

22.6 Pounds

INTERPRETED BY

Kathleen Sennello DVM,
MS, Diplomate ACVIM
(Small Animal Internal
Medicine)

IMAGING PERFORMED BY

Loetitia Saint-Jacques, RVT

HOSPITAL NAME

Marysville Veterinary

REFERRING VET

Dr. Grace Berg

INVOICE

26691

DATE

10/26/21

PRESENTING CLINICAL SIGNS

Chief Concern/Provisional Dx: Renal insufficiency, possible ureteral lith History: Pt has bouts of discomfort when urinates and pain in lower abdominal region. Physical : wnl Senior Screen Summary on 10/11/21: Increased SDMA and creatinine Congenital?

ULTRASONOGRAPHIC EXAMINATION OF THE ABDOMEN

Urinary System

The urinary bladder is moderately distended with anechoic urine. The Bladder wall, trigone, ureteral papillae and visible urethra (to a depth of 2cm) appear normal with no evidence of wall thickening, mucosal irregularities, masses or cystic calculi.

The prostate is normal in size (0.92 cm) and shape for this neutered male dog. The parenchyma is homogenous and the external margins are smooth. The prostatic urethra appears normal with no evidence of irregularity, invasion, mass effect or calculi.

The left kidney has a normal shape and size (4.2 cm) with rare pinpoint non-obstructive nephroliths. Overall echogenicity is normal with adequate corticomedullary distinction and a typical 1:3 cortex:medulla ratio. There is no evidence of perinephric inflammation or effusion. There is no evidence of pyelectasia, infarcts or hydroureter. Renal vasculature is normal.

The right kidney has a normal shape and size (4.21 cm) with rare non-obstructive pinpoint nephroliths. Overall echogenicity is normal with adequate corticomedullary distinction and a typical 1:3 cortex:medulla ratio. There is no evidence of perinephric inflammation or effusion. There is no evidence of pyelectasia, infarcts or hydroureter. Renal vasculature is normal.

Adrenal Glands

The left adrenal gland is normal in size measuring 0.5 cm at the caudal pole. It is observed in its normal position cranial to the left renal artery. It is normal in appearance (uniformly hypoechoic) and shape with no evidence of a mass effect.

The right adrenal gland is normal in size measuring 0.54 cm at the caudal pole. It is observed in its normal position between the cranial aspect of the right kidney and the caudal vena cava. It is normal in appearance (uniformly hypoechoic) and shape with no evidence of a mass effect.

Spleen

The spleen is subjectively normal in size, echotexture is homogenous, and the splenic capsule is smooth with no irregularities. The blood flow through the hilus and splenic parenchyma appears normal. No focal parenchymal abnormalities are visualized.

Liver

The liver is subjectively normal in size, and echogenicity with smooth peripheral margins. The parenchyma is homogenous echotexture. The visible portions of the vasculature and biliary tract appear normal. No focal nodules or cystic lesions are observed.

The gallbladder lumen is moderately distended. The wall of the gall bladder is not thickened and has a smooth mucosal surface. Luminal contents are primarily anechoic. The cystic and common bile ducts are normal/not visible.



PATIENT

Zeus Kaur ***Gastrointestinal***

SPECIES

Canine

BREED

Shiba Inu

SEX

Neutered Male

AGE

3 Years 9 Months

WEIGHT

22.6 Pounds

The stomach contains minimal luminal contents. It measures at a normal thickness of <0.7cm with some variability due to the presence of rugal folds. The distinction of the gastric wall layers is adequate and there is no impression of reduced peristaltic activity. No masses or focal lesions were observed.

The visualized areas of duodenum, jejunum and ileum have a relatively uniform diameter with minimal fluid distension. Wall thickness is normal. Bowel loops follow a curvilinear path with distinct wall layering maintaining the typical 1:3 muscularis:mucosa layer ratio. Duodenum wall measured 0.39 cm. Jejunum wall measured 0.17 cm. Visualized peristalsis appears appropriate. There were no focal lesions consistent with obstruction or a mass effect observed.

The ileocecal junction was visualized and exhibited normal intact wall layering and is subjectively of normal thickness. Sections of colon are visualized with formed fecal material and gas shadowing distally. There is no observed focal or generalized colon wall thickening or loss of layering.

Pancreas

The pancreas is normal and isoechoic to surrounding mesentery. There is no evidence of nodules or cystic lesions. There is no evidence of regional mesenteric inflammation or fluid.

Free Abdomen

No free fluid noted. Prominent mesenteric lymph nodes are visualized measuring 0.31, 0.27, 0.33 cm. The omentum is of normal echogenicity.

ULTRASONOGRAPHIC FINDINGS

INTERPRETED BY

Kathleen Sennello DVM,
MS, Diplomate ACVIM
(Small Animal Internal
Medicine)

- Occasional pinpoint non-obstructive nephroliths in the kidneys – The hyperechoic mineralized foci observed at the corticomedullary junction of the left/right kidney are consistent with small, non-obstructive nephroliths.
- Prominent mesenteric lymph nodes – The prominent abdominal lymph nodes are most consistent with reactive lymphadenitis or lymphoid hyperplasia. Neoplastic infiltration is considered less likely.

IMAGING PERFORMED BY

Loetitia Saint-Jacques, RVT

HOSPITAL NAME

Marysville Veterinary

REFERRING VET

Dr. Grace Berg

INTERPRETATION OF THE FINDINGS & FURTHER RECOMMENDATIONS

The changes observed on today's scan were relatively mild. No obvious cause for the pain on urination noted. Recommend urinalysis and culture. Consider comparing a free catch from a cysto sample to see if there is evidence of hemorrhage from the distal urinary tract. Consider passing a urethral catheter to see if it meets any resistance, and/or a contrast study (cystourethrogram) to see if any strictures, etc. show up. Additionally, evaluate for lumbosacral pain, as this can sometimes mimic caudal abdominal pain. Additionally, recommend blood pressure evaluation and urine protein levels.

INVOICE

26691

DATE

10/26/21



PATIENT

Zeus Kaur

SPECIES

Canine

BREED

Shiba Inu

SEX

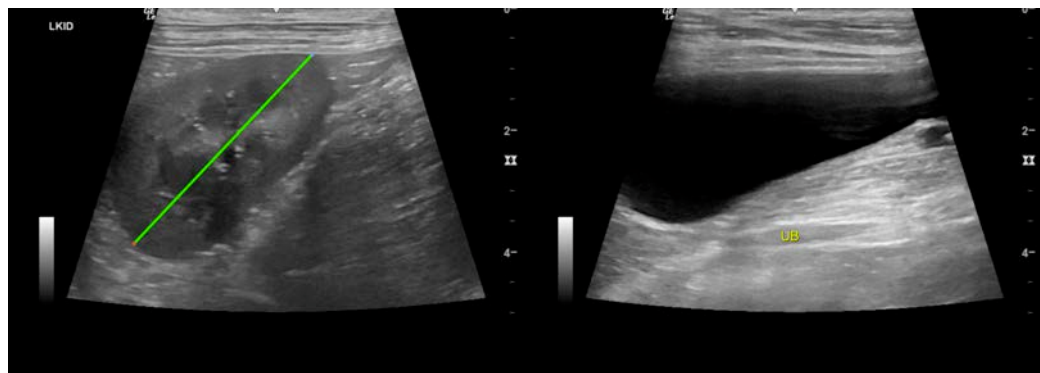
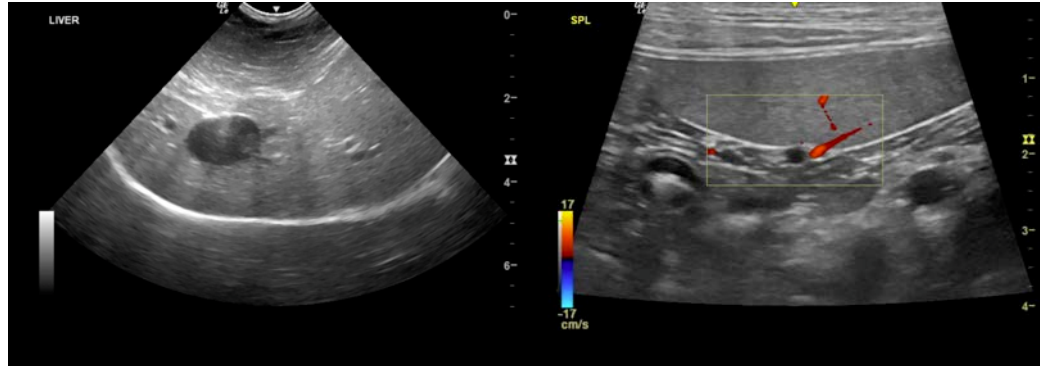
Neutered Male

AGE

3 Years 9 Months

WEIGHT

22.6 Pounds



INTERPRETED BY

Kathleen Sennello DVM,
MS, Diplomate ACVIM
(Small Animal Internal
Medicine)

IMAGING PERFORMED BY

Loetitia Saint-Jacques, RVT

HOSPITAL NAME

Marysville Veterinary

REFERRING VET

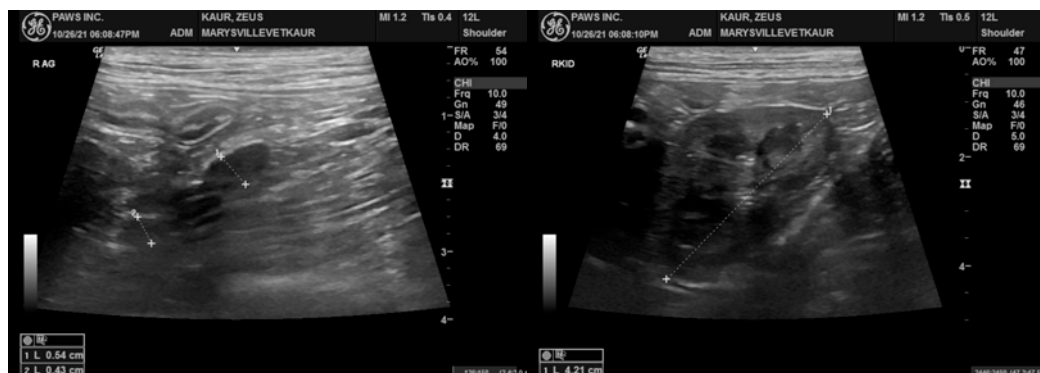
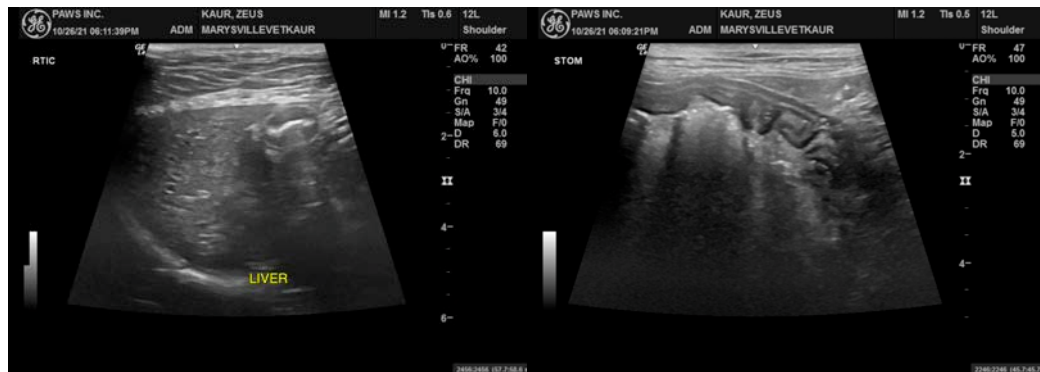
Dr. Grace Berg

INVOICE

26691

DATE

10/26/21





PATIENT

Zeus Kaur

SPECIES

Canine

BREED

Shiba Inu

SEX

Neutered Male

AGE

3 Years 9 Months

WEIGHT

22.6 Pounds

INTERPRETED BY

Kathleen Sennello DVM,
MS, Diplomate ACVIM
(Small Animal Internal
Medicine)

IMAGING PERFORMED BY

Loetitia Saint-Jacques, RVT

HOSPITAL NAME

Marysville Veterinary

REFERRING VET

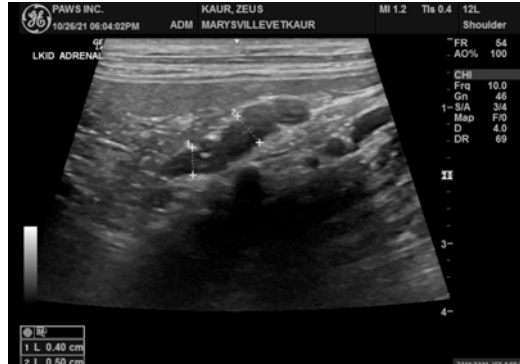Dr. Grace Berg

INVOICE

26691

DATE

10/26/21



The information and recommendations provided are based on the images presented by the referring veterinarian. No evaluation can be communicated regarding pathology that was not visible in the image/video clips provided.

Thank you for this referral. If the clinical or image interpretation does not parallel your findings or if I can be of any further assistance please contact me.

Kathleen Sennello DVM,MS, Diplomate ACVIM (Small animal Internal Medicine)

kathleen.sennello@sonopath.com