

**DATE**

10/26/21

PRESENTING CLINICAL SIGNS

History: intermittent recurring inappropriate urination. irritated skin-periuvular, previous episodes 4/2018, 8/2018, 9/2019, 12/2019, 9/2021.

Current Medications: No current medications.

PATIENT

Lucy Weller

Lab Results: Not provided by the veterinarian.

Radiographs: x-ray bladder - no stones. Attached separately.

Date of Previous IntraPet Ultrasound: No previous IntraPet scans.

Sedation: Sedation not required for scan.

Stat Report: STAT report not requested by the veterinarian.

SPECIES

Feline

ULTRASONOGRAPHIC EXAMINATION OF THE ABDOMEN**BREED**

Domestic Shorthair

Urinary System

The urinary bladder is moderately distended with mild primarily suspended echogenic debris present. The Bladder wall, trigone, ureteral papillae and visible urethra (to a depth of 2cm) appear normal with no evidence of wall thickening, mucosal irregularities, masses or calculi. Echogenic debris of this type can be associated with small crystals, cellular debris and proteinaceous debris.

SEX

Spayed Female

The left kidney has a normal shape and size (3.19 cm). Overall echogenicity is normal with adequate corticomedullary distinction and a typical 1:3 cortex:medulla ratio. There is no evidence of perinephric inflammation or effusion. There is no evidence of pyelectasia, nephroliths, infarcts or hydroureter. Renal vasculature is normal.

AGE

4/16

The right kidney has a normal shape and size (3.39 cm). Overall echogenicity is normal with adequate corticomedullary distinction and a typical 1:3 cortex:medulla ratio. There is no evidence of perinephric inflammation or effusion. There is no evidence of pyelectasia, nephroliths, infarcts or hydroureter. Renal vasculature is normal.

WEIGHT

8.5 lbs

INTERPRETED BY

Kathleen Sennello
DVM, MS, Diplomate
ACVIM (Small Animal
Internal Medicine)

Adrenal Glands

The left adrenal gland is normal in size measuring 0.4 cm at the caudal pole. It is observed in its normal position cranial to the left renal artery. It is normal in appearance (uniformly hypoechoic) and shape with no evidence of a mass effect.

The right adrenal gland is normal in size measuring 0.31 cm at the caudal pole. It is observed in its normal position between the cranial aspect of the right kidney and the caudal vena cava. It is normal in appearance (uniformly hypoechoic) and shape with no evidence of a mass effect.

HOSPITAL NAME

Bel Air VH

Spleen**REFERRING VET**

Dr. Schmidt

The spleen is subjectively normal in size, echotexture is homogenous, and the splenic capsule is smooth with no irregularities. The blood flow through the hilus and splenic parenchyma appears normal. No focal parenchymal abnormalities are visualized.

INVOICE

92659

Liver

The liver is subjectively normal in size, and echogenicity with smooth peripheral margins. The parenchyma is homogenous echotexture. The visible portions of the vasculature and biliary tract appear normal. No focal nodules or cystic lesions are observed. The gallbladder lumen is moderately distended. The wall of the gallbladder is not thickened and has a smooth mucosal surface. There is a moderate amount of non-organized echogenic debris. The cystic and common bile ducts are normal/not visible.

Gastrointestinal

The stomach contains minimal luminal contents. It measures at a normal thickness of <0.36cm with some variability due to the presence of rugal folds. The distinction of the gastric wall layers is adequate and there is no impression of reduced peristaltic activity. No masses or focal lesions were observed.

The visualized areas of duodenum, jejunum and ileum have a relatively uniform diameter with minimal fluid distension. Wall thickness is normal. Bowel loops follow a curvilinear path with distinct wall layering maintaining the typical 1:3 muscularis:mucosa layer ratio. The duodenum measured as normal and the jejunum measured as normal (0.28 cm). Visualized peristalsis appears appropriate. There were no focal lesions consistent with obstruction or a mass effect observed.

The ileocecal junction was visualized and exhibited normal intact wall layering and is subjectively of normal thickness. Sections of colon are visualized with formed fecal material and gas shadowing distally. There is no observed focal or generalized colon wall thickening or loss of layering.

Pancreas

The pancreas is prominent and hypoechoic as compared to the surrounding isoechoic mesentery. There is no evidence of nodules or cystic lesions. There is no evidence of regional mesenteric inflammation or fluid.

Free Abdomen

Evaluation of the peritoneal cavity did not reveal any evidence of effusion, or subjective lymphadenomegaly. The Medial iliac nodes appear normal and there was no evidence of a caudal aortic thrombus at the bifurcation. The omentum is of normal uniform echogenicity.

ULTRASONOGRAPHIC FINDINGS

PRIMARY FINDINGS:

- Echogenic debris in the urinary bladder.

SECONDARY FINDINGS:

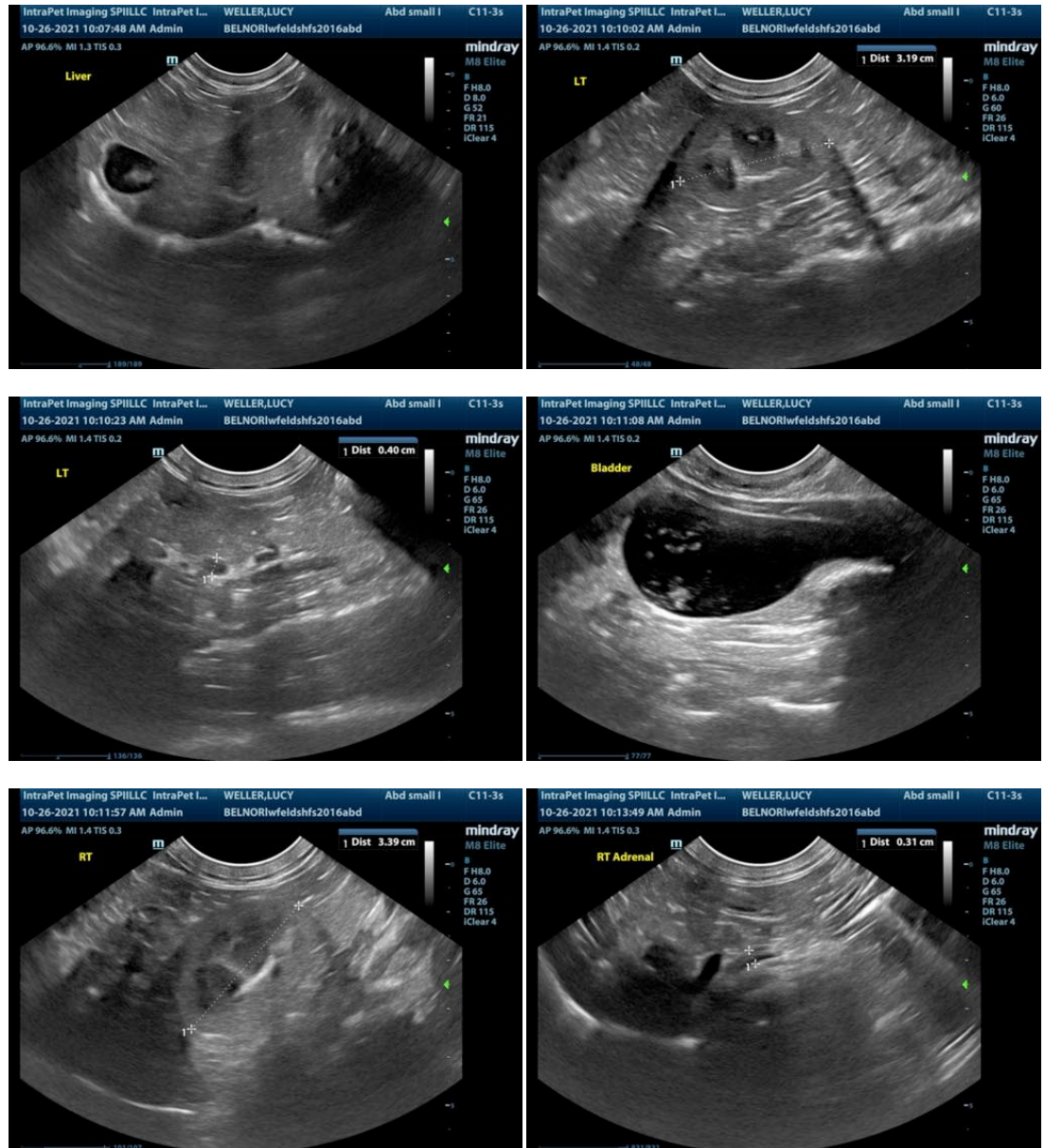
- Mildly prominent, hypoechoic pancreas. The pancreatic changes are most consistent with age-related parenchymal remodeling, potentially secondary to a prior inflammatory episode, early fibrosis or chronic pancreatitis.
- Mild echogenic debris in the gallbladder. The significance of the aggregated gallbladder debris is unclear. This could represent an early mucocele, cholestasis, or may be secondary to fasting.

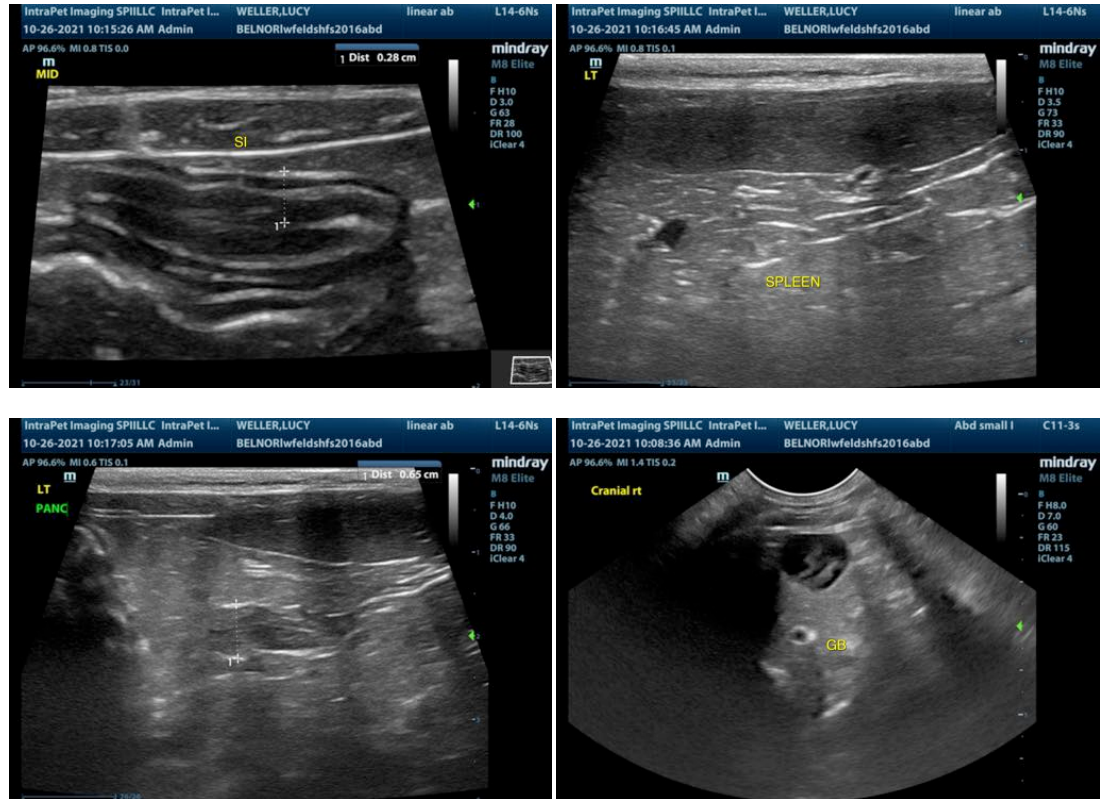
INTERPRETATION OF THE FINDINGS & FURTHER RECOMMENDATIONS

The urinary bladder and kidneys appear relatively normal. There is some echogenic debris in the urinary bladder which can be consistent with inflammation or even benign echogenic debris such as mucous, etc.

- Urinalysis and culture are recommended.
- If culture is negative then interstitial cystitis could be considered
- Treatment of FIC can be frustrating as it is a waxing and waning disease. Treatment strategies vary and there is no "one fits all" approach. There is currently no cure for FIC. Goals of therapy include reduction of severity and duration of clinical signs during an acute episode; increasing the interval between episodes; and decreasing severity of signs in cats with persistent FIC. Approximately 85% of cats will experience clinical improvement with or without therapy.

- Numerous therapies can be considered including: diet, multimodal environmental modification, analgesics, anti-inflammatories, anti-anxiety medications etc..
- Close observation is warranted as some cats do experience life-threatening urinary obstruction.
- If symptoms are worsening re-evaluation with ultrasound should be considered.





The information and recommendations provided are based on the images presented by the referring veterinarian. No evaluation can be communicated regarding pathology that was not visible in the image/video clips provided.

Thank you for this referral. If the clinical or image interpretation does not parallel your findings or if I can be of any further assistance please contact me.

Kathleen Sennello DVM,MS, Diplomate ACVIM (Small animal Internal Medicine)
kathleen.sennello@sonopath.com