

**DATE PRESENTING CLINICAL SIGNS**

10/25/22 Elevated ALT, no improvement with Denamarin/Amoxicillin course. No clinical signs.

PATIENT Current Medications: None currently.

Quinn Benzing

Lab Results: 10/19/22 ALT 614, ALP 243.

Date of Previous IntraPet Ultrasound: No previous.

Sedation: Not required to complete full diagnostic ultrasound.

Stat Report: Not requested.

SPECIES

Canine

ULTRASONOGRAPHIC EXAMINATION OF THE ABDOMEN**BREED** *Urinary System*

Retriever X

The urinary bladder is moderately distended with anechoic urine. The Bladder wall, trigone, ureteral papillae and visible urethra (to a depth of 2cm) appear normal with no evidence of wall thickening, mucosal irregularities, masses or cystic calculi.

SEX

Spayed Female

The left kidney has a normal shape and size (6.9 cm). Overall echogenicity is normal with adequate corticomedullary distinction and a typical 1:3 cortex:medulla ratio. There is no evidence of focal perinephric inflammation or effusion. There is no evidence of pyelectasia, nephroliths, infarcts or hydroureter. Renal vasculature is normal.

AGE

2/19/14

The right kidney has a normal shape and size (6.82 cm). Overall echogenicity is normal with adequate corticomedullary distinction and a typical 1:3 cortex:medulla ratio. There is no evidence of focal perinephric inflammation or effusion. There is no evidence of pyelectasia, nephroliths, infarcts or hydroureter. Renal vasculature is normal.

WEIGHT

45.6 Pounds

Adrenal Glands**INTERPRETED BY**

Kathleen Sennello DVM,
MS, Diplomate ACVIM
(Small Animal Internal
Medicine)

The left adrenal gland is normal in size measuring 0.87 cm at the caudal pole. It is observed in its normal position cranial to the left renal artery. It is normal in appearance (uniformly hypoechoic) and shape with no evidence of a mass effect.

The right adrenal gland is normal in size measuring 0.77 cm at the caudal pole. It is observed in its normal position between the cranial aspect of the right kidney and the caudal vena cava. It is normal in appearance (uniformly hypoechoic) and shape with no evidence of a mass effect.

IMAGING PERFORMED BY

Andi Parkinson RDMS

Spleen

The spleen is subjectively normal in size and the echotexture is homogenous. The splenic capsule is smooth with no visible irregularities. Rare discrete focal hyperechoic, perivascular parenchymal abnormalities are present. The appearance of these lesions is most consistent with benign splenic myelolipomas. The blood flow through the hilus and splenic parenchyma appears normal.

HOSPITAL NAME

Timonium AH

REFERRING VET

Dr. McIntyre

Liver

The liver is subjectively normal in size, and echogenicity with smooth peripheral margins. The parenchyma is heterogenous in echotexture with subtle, indistinct focal mottling. The visible portions of the vasculature and biliary tract appear normal. There are occasional ill-defined hyperechoic nodules. Two such nodules are visualized on the left side of the liver, one measuring 2.2 cm in diameter, and one measuring 1.5 cm in diameter.

INVOICE

42314

The gallbladder lumen is moderately distended. The wall of the gall bladder is not thickened and has a smooth mucosal surface. Luminal contents are mild and primarily anechoic. The cystic and common bile ducts are normal/not visible.

Gastrointestinal

The stomach contains minimal luminal contents. It measures at a normal thickness of <0.7cm with some variability due to the presence of rugal folds. The distinction of the gastric wall layers is adequate and there is no impression of reduced peristaltic activity. No masses or focal lesions were observed.

The visualized areas of duodenum, jejunum and ileum have a relatively uniform diameter with minimal fluid distension. Wall thickness is normal. Bowel loops follow a curvilinear path with distinct wall layering maintaining the typical 1:3 muscularis:mucosa layer ratio. The duodenum measured as normal (between 0.3-0.5cm in wall thickness) and the jejunum measured as normal (between 0.2-0.47cm.) Visualized peristalsis appears appropriate. There were no focal lesions consistent with obstruction or a mass effect observed.

The ileocecal junction was visualized and exhibited normal intact wall layering and is subjectively of normal thickness. Sections of colon are visualized with formed fecal material and gas shadowing distally. There is no observed focal or generalized colon wall thickening or loss of layering.

Pancreas

The pancreas is normal and isoechoic to surrounding mesentery. There is no evidence of nodules or cystic lesions. There is no evidence of regional mesenteric inflammation or fluid.

Free Abdomen

Evaluation of the peritoneal cavity did not reveal any evidence of effusion, or subjective lymphadenomegaly. The Medial iliac nodes appear normal and there was no evidence of a caudal aortic thrombus at the bifurcation. The omentum is of normal uniform echogenicity.

ULTRASONOGRAPHIC FINDINGS

- Heterogeneous liver with ill-defined hyperechoic nodules – The diffuse hepatic changes are non-specific and could be consistent with vacuolar hepatopathy, nodular hyperplasia, inflammatory/immune-mediated disease, fibrosis, extramedullary hematopoiesis, toxic hepatopathy (e.g., copper), infiltrative neoplasia (less likely) or other hepatopathy. The appearance of the nodules trends towards a benign process, but underlying neoplasia cannot be excluded as a possibility.

INTERPRETATION OF THE FINDINGS & FURTHER RECOMMENDATIONS

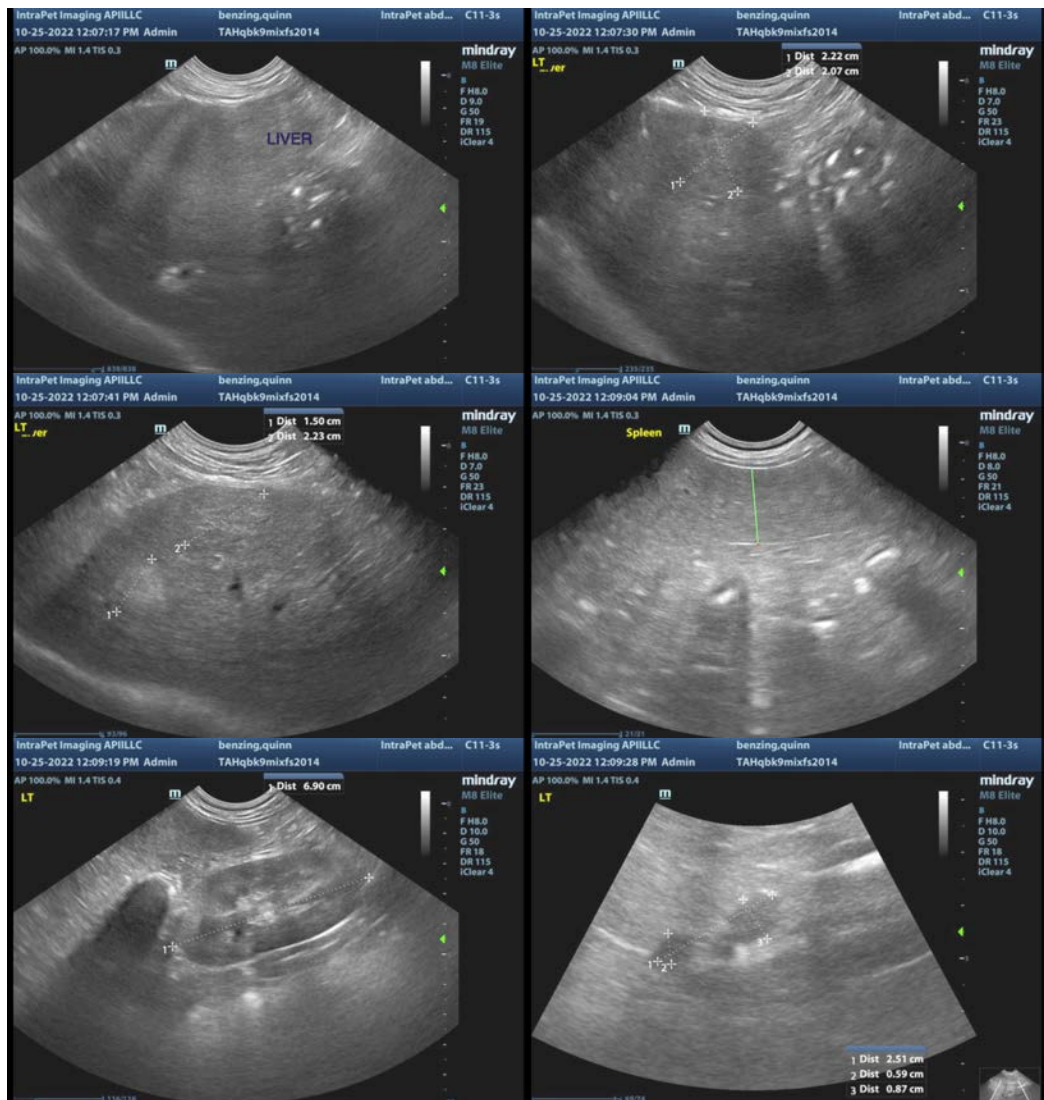
The liver appears somewhat heterogeneous on today's scan and there are ill-defined hyperechoic nodules. The appearance of these nodules has few criteria for malignancy, but an underlying malignancy cannot be 100% ruled out. These are my recommendations for elevated liver values in a dog:

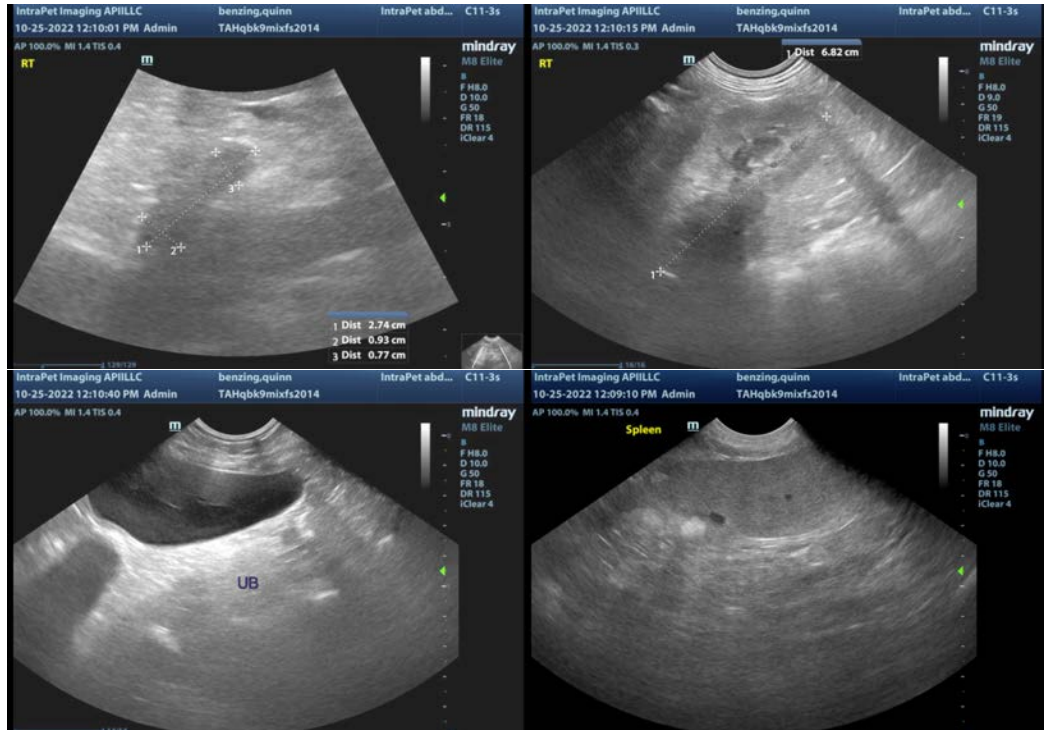
- Consider close evaluation of history for possible toxic changes examine medications, diet, dietary indiscretion etc...
- Consider PCR on urine/serum for leptospirosis (if not on antibiotics)/serology if recent antibiotic history
- If not already done, consider pre and post prandial bile acids to evaluate liver function
- If the ALP is significantly elevated relative to the ALT and symptoms consistent with Cushing's are present, consider adrenal function testing (ACTH stim)
- Consider Fine needle aspirate if round cell neoplasia is on your differentia list (25 g needle, normal coags)

- If no response to supportive care (Denamarin, fluids, antibiotics, +/- ursodiol etc.) Consider liver biopsy with samples obtained for histopathology, culture, and copper levels.

Female Labradors have a propensity towards chronic active hepatitis, which would likely require a surgical or laparoscopic liver biopsy to diagnose. This disease can be treated medically, but if not treated correctly can progress to liver failure, so I would be slightly more aggressive about proceeding to a biopsy, but a fine needle aspirate would be helpful, particularly if one of the hyperechoic nodules could be aspirated.

Recommend three view thoracic radiographs to evaluate for possible concurrent thoracic disease/involvement.





The information and recommendations provided are based on the images presented by the referring veterinarian/sonographer. No evaluation can be communicated regarding pathology that was not visible in the image/video clips provided.

Thank you for this referral. If the clinical or image interpretation does not parallel your findings or if I can be of any further assistance please contact me.

Kathleen Sennello DVM,MS, Diplomate ACVIM (Small animal Internal Medicine)
kathleen.sennello@sonopath.com