

**DATE**

10/22/21

PRESENTING CLINICAL SIGNS

History: **Presenting Complaint:** Breathing Difficulty; Not Eating Drinking More; Not Moving. **Notes:** New DKA, bili increase over 24 hours, still weak. 2/6 murmur.

Current Medications: Cerenia, Pantoprazole, Dextrose, KCl, Humulin-R, Convenia, Furosemide.

PATIENT

Daisy Beck

Lab Results: Attached separately.

Radiographs: Lateral and VD thorax - mild Broncho-interstitial changes.

Date of Previous IntraPet Ultrasound: No previous IntraPet scans.

Sedation: Sedation not required for scan.

Stat Report: STAT report not requested by the veterinarian.

SPECIES

Feline

ULTRASONOGRAPHIC EXAMINATION OF THE ABDOMEN**BREED**

Domestic Shorthair

Urinary System

The urinary bladder is moderately distended with anechoic urine. The Bladder wall, trigone, ureteral papillae and visible urethra (to a depth of 2cm) appear normal with no evidence of wall thickening, mucosal irregularities, masses or cystic calculi.

SEX

Spayed Female

The left kidney has a normal shape and size (4.44 cm). Overall echogenicity is normal with adequate corticomedullary distinction and a typical 1:3 cortex:medulla ratio. There is no evidence of perinephric inflammation or effusion. There is no evidence of pyelectasia, nephroliths, infarcts or hydroureter. Renal vasculature is normal.

AGE

10/20/09

The right kidney has a normal shape and size (4.44 cm). Overall echogenicity is normal with adequate corticomedullary distinction and a typical 1:3 cortex:medulla ratio. There is no evidence of perinephric inflammation or effusion. There is no evidence of pyelectasia, nephroliths, infarcts or hydroureter. Renal vasculature is normal.

WEIGHT

11 lbs

INTERPRETED BY

Kathleen Sennello
 DVM, MS, Diplomate
 ACVIM (Small Animal
 Internal Medicine)

Adrenal Glands

The left adrenal gland is normal in size measuring 0.5 cm at the caudal pole. It is observed in its normal position cranial to the left renal artery. It is normal in appearance (uniformly hypoechoic) and shape with no evidence of a mass effect.

The right adrenal gland is normal in size measuring 0.34 cm at the caudal pole. It is observed in its normal position between the cranial aspect of the right kidney and the caudal vena cava. It is normal in appearance (uniformly hypoechoic) and shape with no evidence of a mass effect.

HOSPITAL NAME

Animal Emergency
 Hospital

Spleen

The spleen is subjectively normal in size, echotexture is homogenous, and the splenic capsule is smooth with no irregularities. The blood flow through the hilus and splenic parenchyma appears normal. No focal parenchymal abnormalities are visualized.

REFERRING VET

Dr. Saubier

Liver

The liver is subjectively large in size with smooth peripheral margins. The parenchyma is hyperechoic and homogenous in echotexture. The visible portions of the vasculature and biliary tract appear normal. No focal nodules or cystic lesions are observed. The gallbladder lumen is moderately distended. The wall of the gallbladder is not thickened and has a smooth mucosal surface. Luminal contents are primarily anechoic. The cystic and common bile ducts are normal/not visible.

INVOICE

92571

Gastrointestinal

The stomach contains minimal luminal contents. It measures at a normal thickness of <0.36cm with some variability due to the presence of rugal folds. The distinction of the gastric wall layers is adequate and there is no impression of reduced peristaltic activity. No masses or focal lesions were observed.

The visualized areas of duodenum, jejunum and ileum have a relatively uniform diameter with minimal fluid distension. Wall thickness is normal. Bowel loops follow a curvilinear path with distinct wall layering maintaining the typical 1:3 muscularis:mucosa layer ratio. The duodenum measured as normal (between 0.13-0.38cm in wall thickness) and the jejunum measured as normal (between 0.15-0.36cm.) Visualized peristalsis appears appropriate. There were no focal lesions consistent with obstruction or a mass effect observed.

The ileocecal junction was visualized and exhibited normal intact wall layering and is subjectively of normal thickness. Sections of colon are visualized with formed fecal material and gas shadowing distally. There is no observed focal or generalized colon wall thickening or loss of layering.

Pancreas

The pancreas is large and hypoechoic to surrounding mesentery. There is no evidence of nodules or cystic lesions. There is evidence of regional mesenteric inflammation. Consistent with mild to moderate pancreatitis.

Free Abdomen

Evaluation of the peritoneal cavity did not reveal any evidence of effusion, or subjective lymphadenomegaly. The Medial iliac nodes appear normal and there was no evidence of a caudal aortic thrombus at the bifurcation. The omentum is of normal uniform echogenicity.

ULTRASONOGRAPHIC FINDINGS

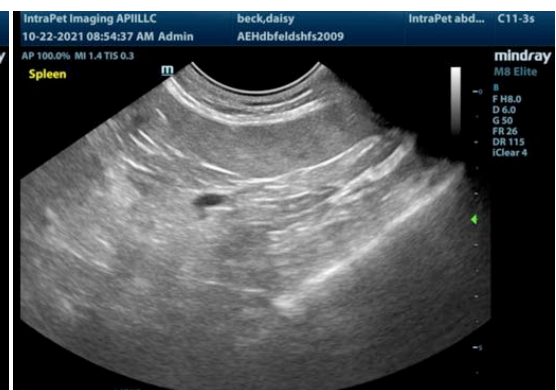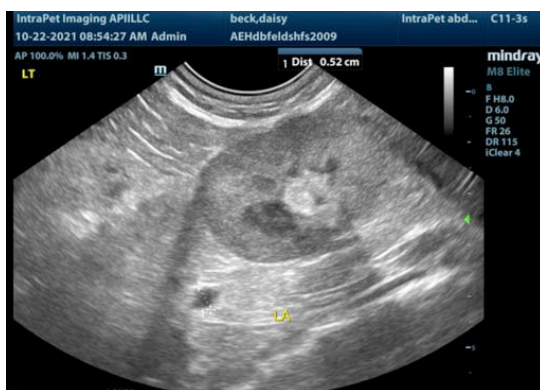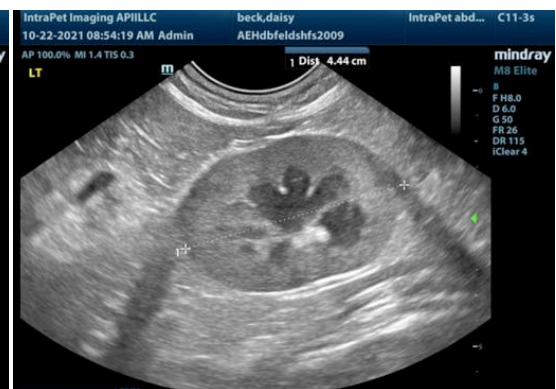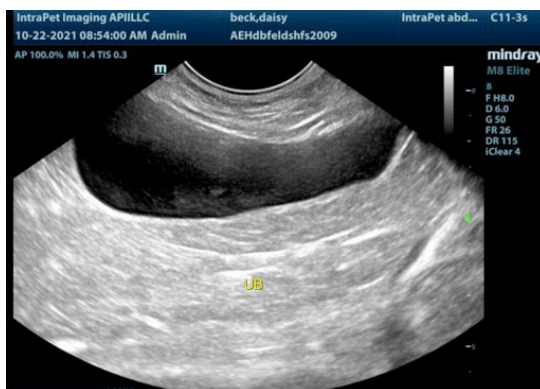
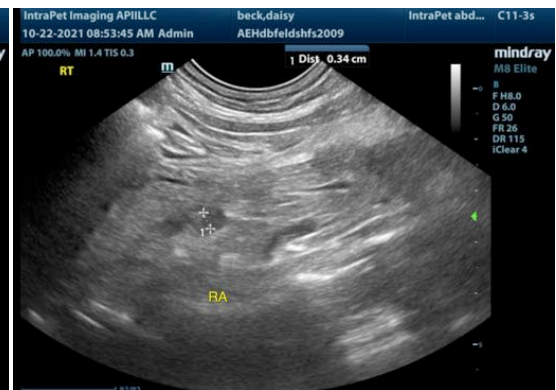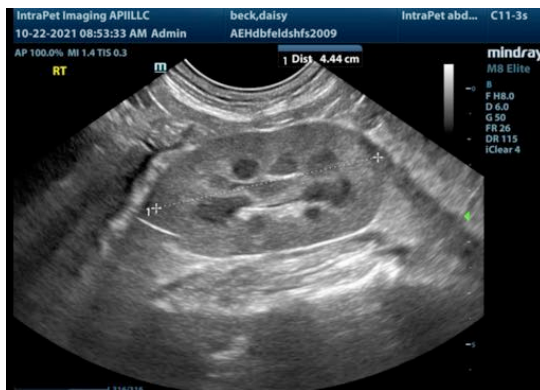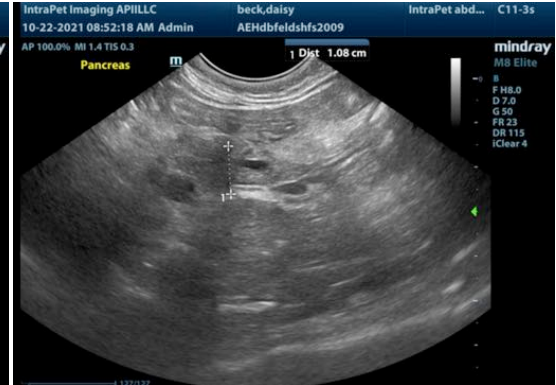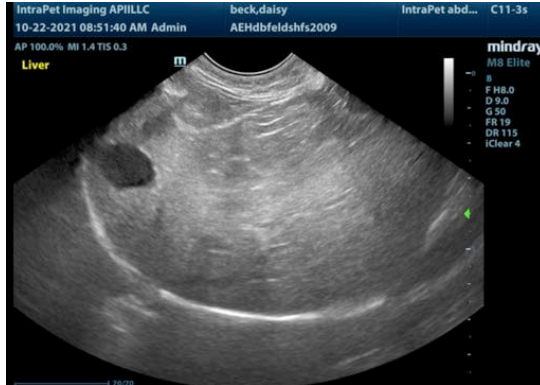PRIMARY FINDINGS:

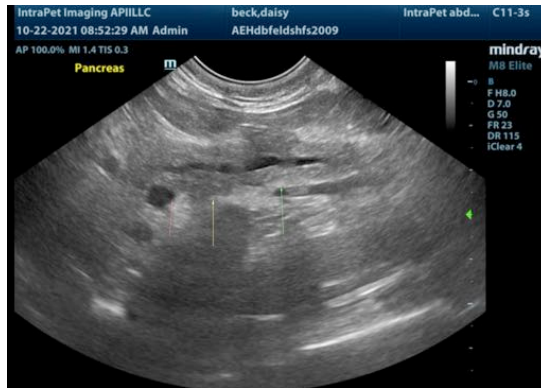Large hyperechoic liver. Hepatic changes are non-specific and could be consistent with hepatic lipidosis, inflammatory/infectious disease, infiltrative neoplasia, or other hepatopathy.

Prominent, hypoechoic pancreas surrounded by hyperechoic mesentery. The pancreatic changes are most consistent with mild/moderate pancreatitis/pancreatic infiltration. I recommend fPLI testing and continued monitoring for improvement or possible development of a pancreatic abscess. Consider FNA if not improving.

INTERPRETATION OF THE FINDINGS & FURTHER RECOMMENDATIONS

Ultrasonographic lesions are most consistent with a diabetic hepatopathy and mild to moderate pancreatitis. No overt evidence of pyelonephritis is present although urinalysis and culture is recommended. No focal mass lesions or concurrent issues are noted.





The information and recommendations provided are based on the images presented by the referring veterinarian. No evaluation can be communicated regarding pathology that was not visible in the image/video clips provided.

Thank you for this referral. If the clinical or image interpretation does not parallel your findings or if I can be of any further assistance please contact me.

Kathleen Sennello DVM,MS, Diplomate ACVIM (Small animal Internal Medicine)
kathleen.sennello@sonopath.com