

**DATE PRESENTING CLINICAL SIGNS**

10/21/21

PATIENT

History: Patient presents for on and off diarrhea. Today has also been vomiting food and bile. On and off diarrhea for months. Patient vomiting 3-4 times today as well - r/o panc vs ibd vs dietary indiscretion vs parasitic vs foreign body vs other.

Stella Mardaga

SPECIES

Current Medications: I/D
 Date of Previous IntraPet Ultrasound: No previous
 Sedation: not needed
 Stat Report: not requested

Canine

BREED**ULTRASONOGRAPHIC EXAMINATION OF THE ABDOMEN**

Bichon Frise Mix

Urinary System**SEX**

The urinary bladder is moderately distended with anechoic urine. The Bladder wall, trigone, ureteral papillae and visible urethra (to a depth of 2.0 cm) appear normal with no evidence of wall thickening, mucosal irregularities, masses or cystic calculi.

Spayed Female

AGE

The left kidney has a normal shape and size (4.28 cm). Overall echogenicity is normal with adequate corticomedullary distinction and a typical 1:3 cortex: medulla ratio. There is no evidence of perinephric inflammation or effusion. There is no evidence of pyelectasia, nephroliths, infarcts or hydroureter. Renal vasculature is normal.

2017

WEIGHT

14.09 Pounds

The right kidney has a normal shape and size (4.33 cm). Overall echogenicity is normal with adequate corticomedullary distinction and a typical 1:3 cortex: medulla ratio. There is no evidence of perinephric inflammation or effusion. There is no evidence of pyelectasia, nephroliths, infarcts or hydroureter. Renal vasculature is normal.

INTERPRETED BY

Kathleen Sennello DVM,
 MS, Diplomate ACVIM
 (Small Animal Internal
 Medicine)

Adrenal Glands

The left adrenal gland is normal in size measuring 0.59 cm. It is observed in its normal position cranial to the left renal artery. It is normal in appearance (uniformly hypoechoic) and shape with no evidence of a mass effect.

HOSPITAL NAME

Everhart VH

The right adrenal gland is normal in size measuring 0.44 cm. It is observed in its normal position between the cranial aspect of the right kidney and the caudal vena cava. It is normal in appearance (uniformly hypoechoic) and shape with no evidence of a mass effect.

REFERRING VET

Dr. Rubinstein

Spleen

The spleen is subjectively normal in size, echotexture is homogenous, and the splenic capsule is smooth with no irregularities. The blood flow through the hilus and splenic parenchyma appears normal. No focal parenchymal abnormalities are visualized.

INVOICE

13958

Liver

The liver is subjectively (normal, large, small, normal/large, normal/small) in size, and echogenicity with smooth peripheral margins. The parenchyma is heterogenous in echotexture with subtle, indistinct focal mottling. The visible portions of the vasculature and biliary tract appear normal. No focal nodules or cystic lesions are observed.

The gallbladder lumen is significantly distended. Some areas of the wall appear mildly thickened with adherent debris. There is a mild amount of primarily non-organized echogenic debris in the dependent

portion of the gallbladder. There is no evidence of bile duct dilation or inflammation around the gall bladder.

Gastrointestinal

The stomach is moderately dilated with fluid and irregular shadowing material most consistent with a large amount of ingesta and gas. It measures at a normal thickness of <0.7cm with some variability due to the presence of rugal folds. The distinction of the gastric wall layering is adequate and there is no impression of reduced peristaltic activity. No masses or focal lesions were observed.

The visualized areas of duodenum, jejunum and ileum have a uniform diameter with minimal fluid distension. Wall thickness is increased. Bowel loops follow a typical curvilinear path. Some areas have reduced detail of wall layering (+/- enter with mucosal speckling). Visualized peristalsis appears appropriate. There were no focal lesions consistent with obstruction or a mass effect observed. The duodenum measures 0.37 cm. The jejunum measures 0.35 cm.

The ileocecal junction was visualized and exhibited normal intact wall layering and is subjectively of normal thickness. Sections of colon are visualized with liquid fecal material and gas shadowing distally. There is no observed focal or generalized colon wall thickening or loss of layering.

Pancreas

The pancreas is prominent and mottled compared to the surrounding isoechoic mesentery. There is no evidence of nodules or cystic lesions. There is no evidence of regional mesenteric inflammation or fluid.

Free Abdomen

There is no evidence of free fluid. A mild mesenteric lymphadenopathy is present with mesenteric lymph node visualized, measuring 0.68 cm. The omentum is of normal echogenicity.

ULTRASONOGRAPHIC FINDINGS

Primary Findings

- Prominent mottled pancreas- The pancreatic changes are most consistent with mild pancreatitis or a recent episode of pancreatic inflammation.
- Large amount of shadowing ingesta within the gastric lumen, correlate this with feeding history. If adequately fasted, then consider delayed gastric emptying or a possible partial obstruction (none visualized).
- Mild mucosal speckling and subjective small intestinal wall thickening- The mild small intestinal wall changes may be a normal variant in this patient or could be consistent with an inflammatory process (e.g., inflammatory bowel disease). Bright mucosal speckling has been proposed to represent dilated lacteals or focal accumulation of mucus, cellular debris etc. in the mucosal crypts of the small intestine.
- Mild mesenteric lymphadenopathy- The prominent abdominal lymph nodes are most consistent with reactive lymphadenitis or lymphoid hyperplasia. Neoplastic infiltration is considered less likely.

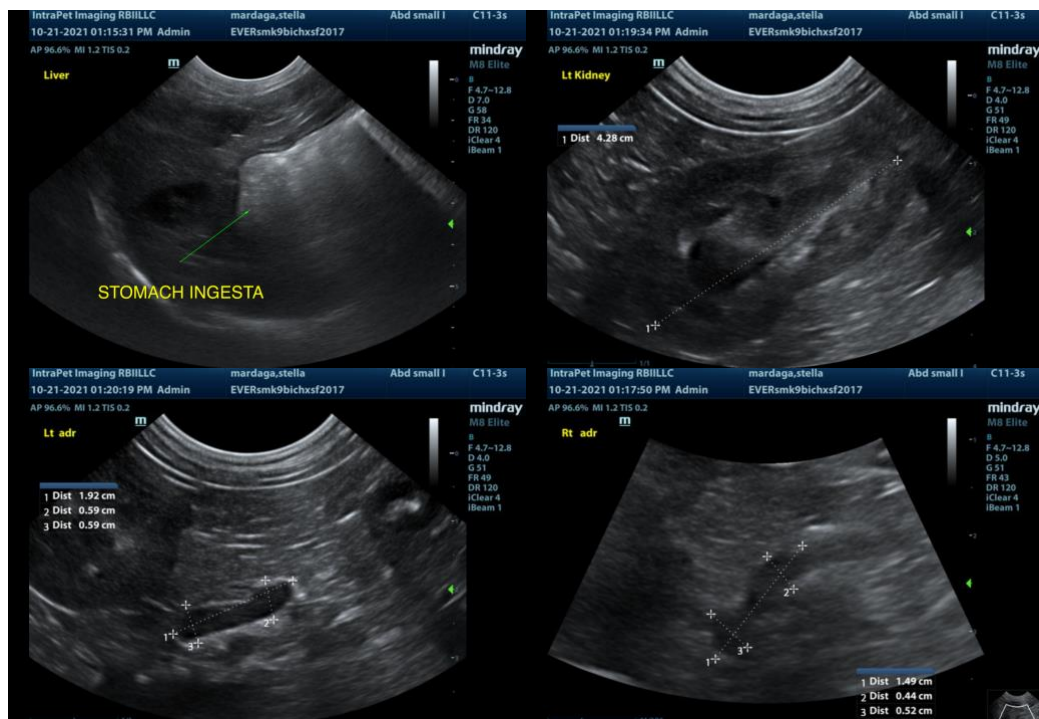
Secondary Findings

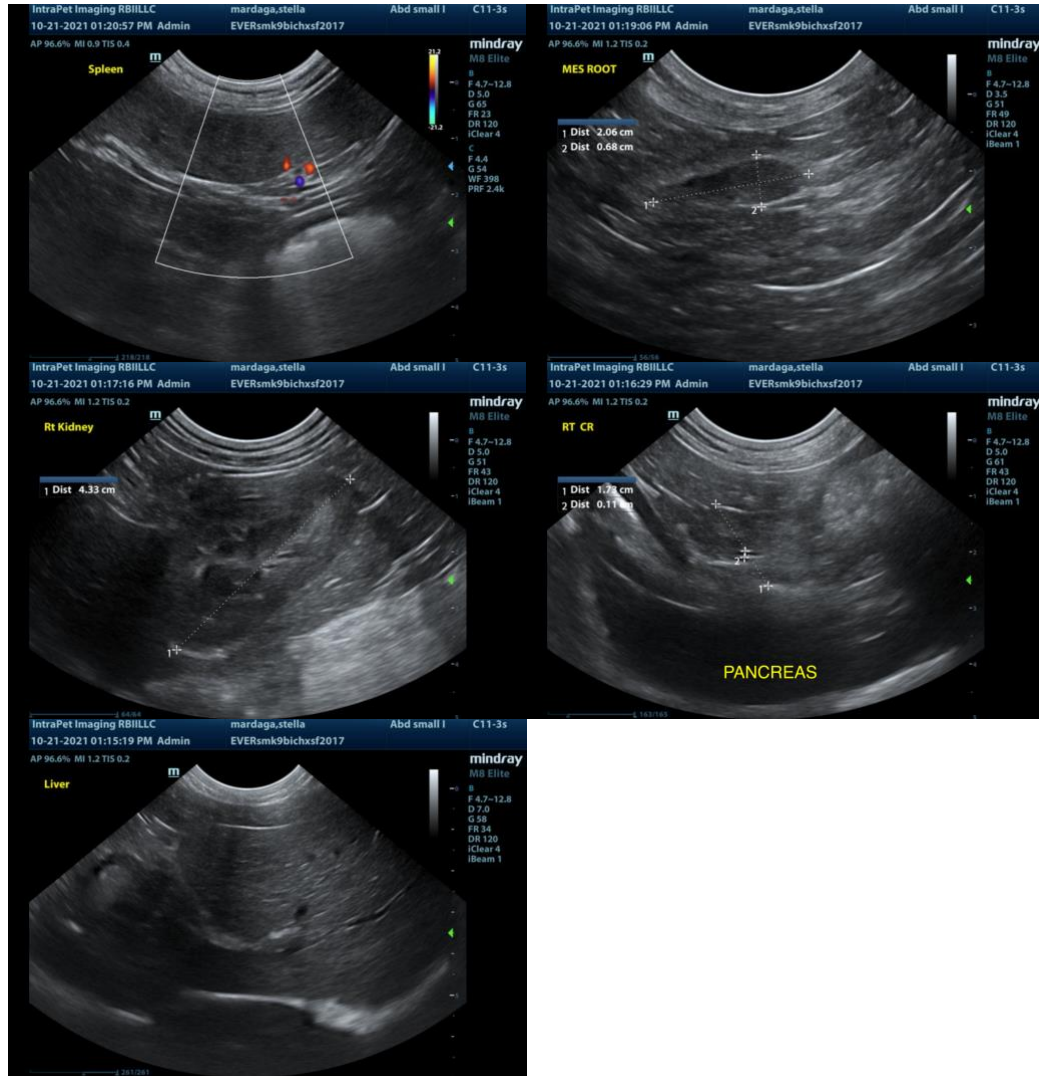
- Mildly heterogeneous liver- If liver enzymes are normal this is likely a normal finding for this individual.
- Mild gallbladder sludge- The significance of the aggregated gallbladder debris is unclear. This could represent an early mucocele, cholestasis, or may be secondary to fasting.

INTERPRETATION OF THE FINDINGS & FURTHER RECOMMENDATIONS

The ultrasonographic lesions visualized were relatively mild and non-specific. Given the history of chronic intermittent diarrhea and vomiting, primary GI disease is suspected. I recommend an ACTH stimulation test to rule out Addison's and baseline blood work to look for any underlying metabolic changes.

- If primary GI disease is suspected consider such differentials as GI parasitism, dietary indiscretion, mild pancreatitis, bacterial dysbiosis, food allergy, IBD and less likely intestinal neoplasia.
- I recommend a diet trial with a novel protein/hydrolyzed prescription diet.
- I recommend a GI panel with a PLI/TLI/cobalamin/folate level (Texas A & M University) to further evaluate the pancreas and small intestine.
- I recommend probiotic therapy
- If symptoms are progressing, consider obtaining GI biopsies.





The information and recommendations provided are based on the images presented by the referring veterinarian. No evaluation can be communicated regarding pathology that was not visible in the image/video clips provided.

Thank you for this referral. If the clinical or image interpretation does not parallel your findings or if I can be of any further assistance please contact me.

Kathleen Sennello DVM,MS, Diplomate ACVIM (Small animal Internal Medicine)
 kathleen.sennello@sonopath.com