

**DATE**

10/21/21

**PRESENTING CLINICAL SIGNS**

Mildly elevated ALT, generally decreased appetite.  
Current Medications: Ondansetron HCL 8 mg, Incurin  
Lab Results: Attached

**PATIENT**

Hunter Hermann

Radiographs: delayed emptying, large volume of food in stomach (does empty with small bolus feedings but p seems to have a harder time now emptying stomach when very full)

Date of Previous IntraPet Ultrasound: No previous

Sedation: not needed

Stat Report: not requested

**SPECIES**

Canine

**BREED**

Labrador Retriever

**SEX**

Spayed Female

**AGE**

2010

**WEIGHT**

62.1 lbs

**ULTRASONOGRAPHIC EXAMINATION OF THE ABDOMEN****Urinary System**

The urinary bladder is moderately distended with anechoic urine. The Bladder wall, trigone, ureteral papillae and visible urethra (to a depth of 2cm) appear normal with no evidence of wall thickening, mucosal irregularities, masses or cystic calculi.

The left kidney has a normal shape and size (6.29 cm). Overall echogenicity is normal with adequate corticomedullary distinction and a typical 1:3 cortex:medulla ratio. There is no evidence of perinephric inflammation or effusion. There is no evidence of pyelectasia, nephroliths, infarcts or hydroureter. Renal vasculature is normal.

The right kidney has a normal shape and size (6.61 cm). Overall echogenicity is normal with adequate corticomedullary distinction and a typical 1:3 cortex:medulla ratio. There is no evidence of perinephric inflammation or effusion. There is no evidence of pyelectasia, nephroliths, infarcts or hydroureter. Renal vasculature is normal.

**INTERPRETED BY**

Kathleen Sennello  
DVM, MS, Diplomate  
ACVIM (Small Animal  
Internal Medicine)

**Adrenal Glands**

The left adrenal gland is normal in size measuring 0.7 cm at the caudal pole It is observed in its normal position cranial to the left renal artery. It is normal in appearance (uniformly hypoechoic) and shape with no evidence of a mass effect.

The right adrenal gland is normal in size measuring 0.76 cm at the caudal pole It is observed in its normal position between the cranial aspect of the right kidney and the caudal vena cava. It is normal in appearance (uniformly hypoechoic) and shape with no evidence of a mass effect.

**HOSPITAL NAME**

Bayside Animal  
Medical Center

**Spleen**

The spleen is subjectively normal in size, echotexture is homogenous, and the splenic capsule is smooth with no irregularities. The blood flow through the hilus and splenic parenchyma appears normal. No focal parenchymal abnormalities are visualized.

**REFERRING VET**

Dr. DeLozier

**INVOICE**

92560

**Liver**

The liver is subjectively normal in size, and echogenicity with smooth peripheral margins. The parenchyma is homogenous echotexture. The visible portions of the vasculature and biliary tract appear normal. No focal nodules or cystic lesions are observed. The gallbladder lumen is moderately distended. The wall of the gallbladder is not thickened and has a smooth mucosal surface. Luminal contents are primarily anechoic. The cystic and common bile ducts are normal/not visible.

### ***Gastrointestinal***

The stomach contains minimal luminal contents. It measures at a normal thickness of <0.7cm with some variability due to the presence of rugal folds. The distinction of the gastric wall layers is adequate and there is no impression of reduced peristaltic activity. No masses or focal lesions were observed.

The visualized areas of duodenum, jejunum and ileum have a relatively uniform diameter with minimal fluid distension. Wall thickness is normal. Bowel loops follow a curvilinear path with distinct wall layering maintaining the typical 1:3 muscularis:mucosa layer ratio. The duodenum measured as normal (0.36 cm) and the jejunum measured as normal. Visualized peristalsis appears appropriate. There were no focal lesions consistent with obstruction or a mass effect observed.

The ileocecal junction was visualized and exhibited normal intact wall layering and is subjectively of normal thickness. Sections of colon are visualized with formed fecal material and gas shadowing distally. There is no observed focal or generalized colon wall thickening or loss of layering.

### ***Pancreas***

The pancreas is normal and isoechoic to surrounding mesentery. There is no evidence of nodules or cystic lesions. There is no evidence of regional mesenteric inflammation or fluid.

### ***Free Abdomen***

Evaluation of the peritoneal cavity did not reveal any evidence of effusion, or subjective lymphadenomegaly. The Medial iliac nodes appear normal and there was no evidence of a caudal aortic thrombus at the bifurcation. The omentum is of normal uniform echogenicity.

## **ULTRASONOGRAPHIC FINDINGS**

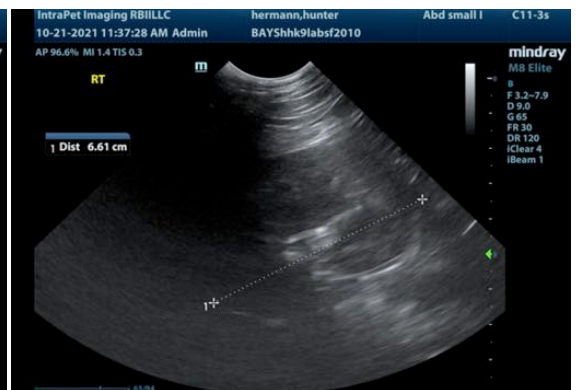
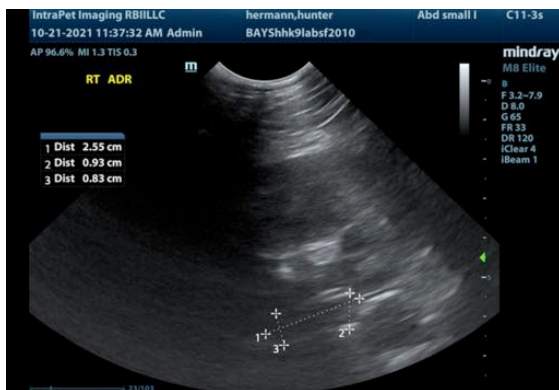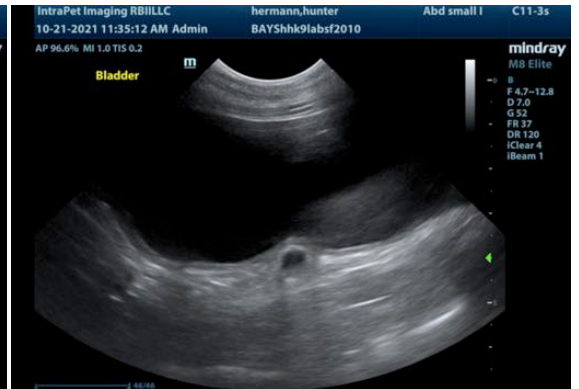
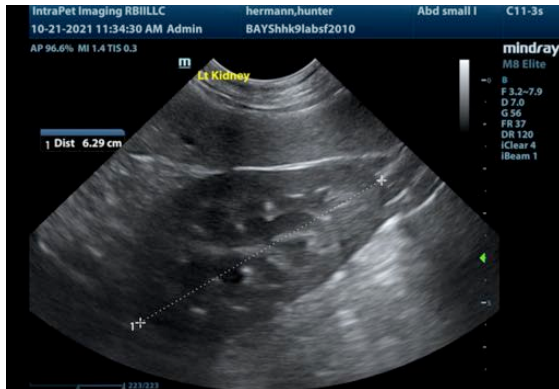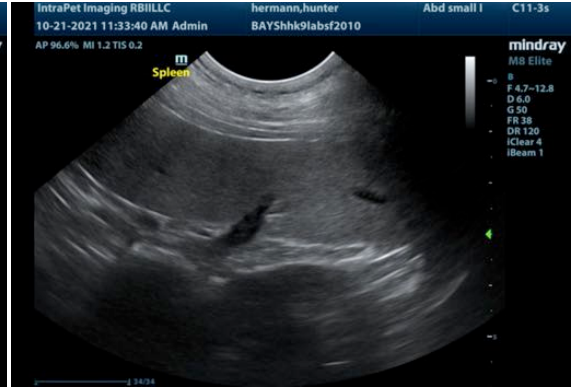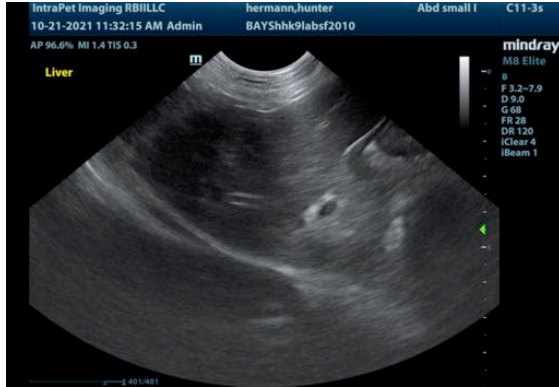### **PRIMARY FINDINGS:**

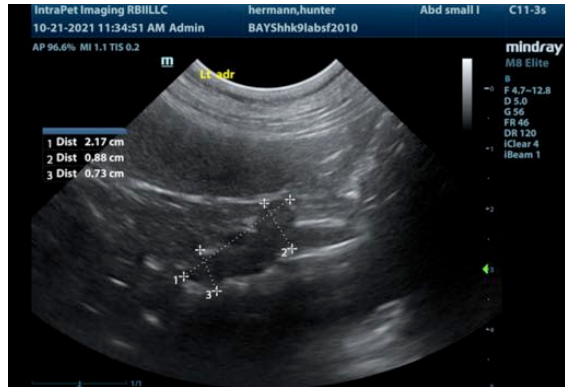
No significant ultrasonographic lesions visualized.

## **INTERPRETATION OF THE FINDINGS & FURTHER RECOMMENDATIONS**

No focal hepatobiliary lesions were identified. Unfortunately ultrasound findings do not always correlate with clinical symptoms or function of the system evaluated. It is possible to still have significant liver disease despite a normal ultrasonographic appearance. Due to the fact that female Labradors have a higher incidence of chronic active hepatitis and this can progress to liver failure I would take this more seriously and I strongly recommend full evaluation.

- Consider close evaluation of history for possible toxic changes examine medications, diet, dietary indiscretion etc...
- Consider PCR on urine/serum for leptospirosis (if not on antibiotics)/serology if recent antibiotic history
- If not already done, consider pre and post prandial bile acids to evaluate liver function
- If the ALP is significantly elevated relative to the ALT and symptoms consistent with Cushing's are present, consider adrenal function testing (ACTH stim)
- Consider Fine needle aspirate if round cell neoplasia is on your differentia list (25 g needle, normal coags)
- If no response to supportive care (Denamarin, fluids, antibiotics,+/- Ursodiol etc...) Consider liver biopsy with samples obtained for histopathology, culture, and copper levels.





The information and recommendations provided are based on the images presented by the referring veterinarian. No evaluation can be communicated regarding pathology that was not visible in the image/video clips provided.

Thank you for this referral. If the clinical or image interpretation does not parallel your findings or if I can be of any further assistance please contact me.

Kathleen Sennello DVM,MS, Diplomate ACVIM (Small animal Internal Medicine)  
kathleen.sennello@sonopath.com