

**DATE PRESENTING CLINICAL SIGNS**

10/21/21

Not Eating &amp; Referral for Continued Care.

**PATIENT**

Graysie Cook

History: Date: 10-20-2021 Notes: Referral for lethargy, not wanting to get up, pale mucus membranes. BW showed PCV 18%, albumin 1.9, low platelets, elevated BUN, melena. Referred for hospitalization, monitoring PCV, possibly IVF, and AUS as soon as available. rDVM

**SPECIES**

Canine

expressed caution to owner about starting IVF since currently stable and we do not want to worsen anemia or cause third spacing. Ate a

**BREED**

Labrador Retriever

horsehoof that appears to have splintered off into numerous pieces - evident on radiographs. Did eat and drink this morning. No vomiting or diarrhea. Lateral chest and abdominal films from rDVM - colon packed with stool. Gave enema - evacuated about 6 inches of stool, no sharp shards, stool formed.

**SEX**

Spayed Female

Current Medications: Metronidazole Tablets 500mg, Omeprazole Capsules 20mg, Amoxicillin Capsules 500mg

**AGE**

2011

Lab Results: PCV 18 % 37 55. TS 4.4 g/dL 5.0 8.0.

Date of Previous IntraPet Ultrasound: 4/30/19 and 6/12/18

Sedation: not needed

Stat Report: not requested

**WEIGHT**

82.4 Pounds

**ULTRASONOGRAPHIC EXAMINATION OF THE ABDOMEN****Urinary System**

The urinary bladder is moderately distended with anechoic urine. The Bladder wall, trigone, ureteral papillae and visible urethra (to a depth of 2cm) appear normal with no evidence of wall thickening, mucosal irregularities, masses or cystic calculi.

**INTERPRETED BY**

Kathleen Sennello DVM,  
MS, Diplomate ACVIM  
(Small Animal Internal  
Medicine)

The left kidney has a normal shape and size (7.71 cm). Overall echogenicity is slightly hyperechoic with poor corticomedullary distinction and a typical 1:3 cortex:medulla ratio. There is no evidence of perinephric inflammation or effusion. There is no evidence of pyelectasia, nephroliths, infarcts or hydroureter. Renal vasculature is normal.

**HOSPITAL NAME**

Animal Emergency  
Hospital

The right kidney has a normal shape and size (7.93 cm). Overall echogenicity is slightly hyperechoic with poor corticomedullary distinction and a typical 1:3 cortex:medulla ratio. There is no evidence of perinephric inflammation or effusion. There is no evidence of pyelectasia, nephroliths, infarcts or hydroureter. Renal vasculature is normal.

**REFERRING VET**

Dr. Alayon

**Adrenal Glands**

The left adrenal gland is large in size measuring 1.53 cm at the caudal pole, 0.88 cm at the cranial pole, and 3.33 cm in length. It is observed in its normal position cranial to the left renal artery. It is irregular in appearance, in that the caudal pole was enlarged and somewhat hyperechoic, creating a nodule effect measuring 1.53 cm x 2.28 cm. There is no evidence of obvious vascular invasion or regional fluid.

**INVOICE**

26583

The right adrenal gland is normal in size measuring 0.67 cm at the caudal pole. It is observed in its normal position between the cranial aspect of the right kidney and the caudal vena cava. It is normal in appearance (uniformly hypoechoic) and shape with no evidence of a mass effect.

**Spleen**

The spleen is subjectively normal in size. The spleen echotexture is heterogenous and mottled, the splenic capsule is smooth with no irregularities. The blood flow through the hilus and splenic parenchyma appears normal. No focal parenchymal abnormalities are visualized.

### ***Liver***

The liver is subjectively normal in size, and echogenicity with smooth peripheral margins. The parenchyma is heterogenous in echotexture with subtle, indistinct focal mottling. The visible portions of the vasculature and biliary tract appear normal. No focal nodules or cystic lesions are observed.

The gallbladder lumen is moderately distended. The wall of the gall bladder is not thickened and has a smooth mucosal surface. Luminal contents are primarily anechoic. The cystic and common bile ducts are normal/not visible.

### ***Gastrointestinal***

The stomach contains minimal luminal contents. It measures at a normal thickness of <0.7cm with some variability due to the presence of rugal folds. The distinction of the gastric wall layers is adequate and there is no impression of reduced peristaltic activity. No masses or focal lesions were observed.

The visualized areas of duodenum, jejunum and ileum have a relatively uniform diameter with minimal fluid distension. Wall thickness is normal. Bowel loops follow a curvilinear path with distinct wall layering maintaining the typical 1:3 muscularis:mucosa layer ratio. Jejunum wall measured 0.36 cm. Visualized peristalsis appears appropriate. There were no focal lesions consistent with obstruction or a mass effect observed.

The ileocecal junction was visualized and exhibited normal intact wall layering and is subjectively of normal thickness. Sections of colon are visualized with a large volume of shadowing, solid fecal material distally. There is no observed focal or generalized colon wall thickening or loss of layering.

### ***Pancreas***

The pancreas is normal and isoechoic to surrounding mesentery. There is no evidence of nodules or cystic lesions. There is no evidence of regional mesenteric inflammation or fluid.

### ***Free Abdomen***

Evaluation of the peritoneal cavity did not reveal any evidence of effusion, or subjective lymphadenomegaly. The Medial iliac nodes appear normal and there was no evidence of a caudal aortic thrombus at the bifurcation. The omentum is generally hyperechoic.

## **PRIMARY FINDINGS**

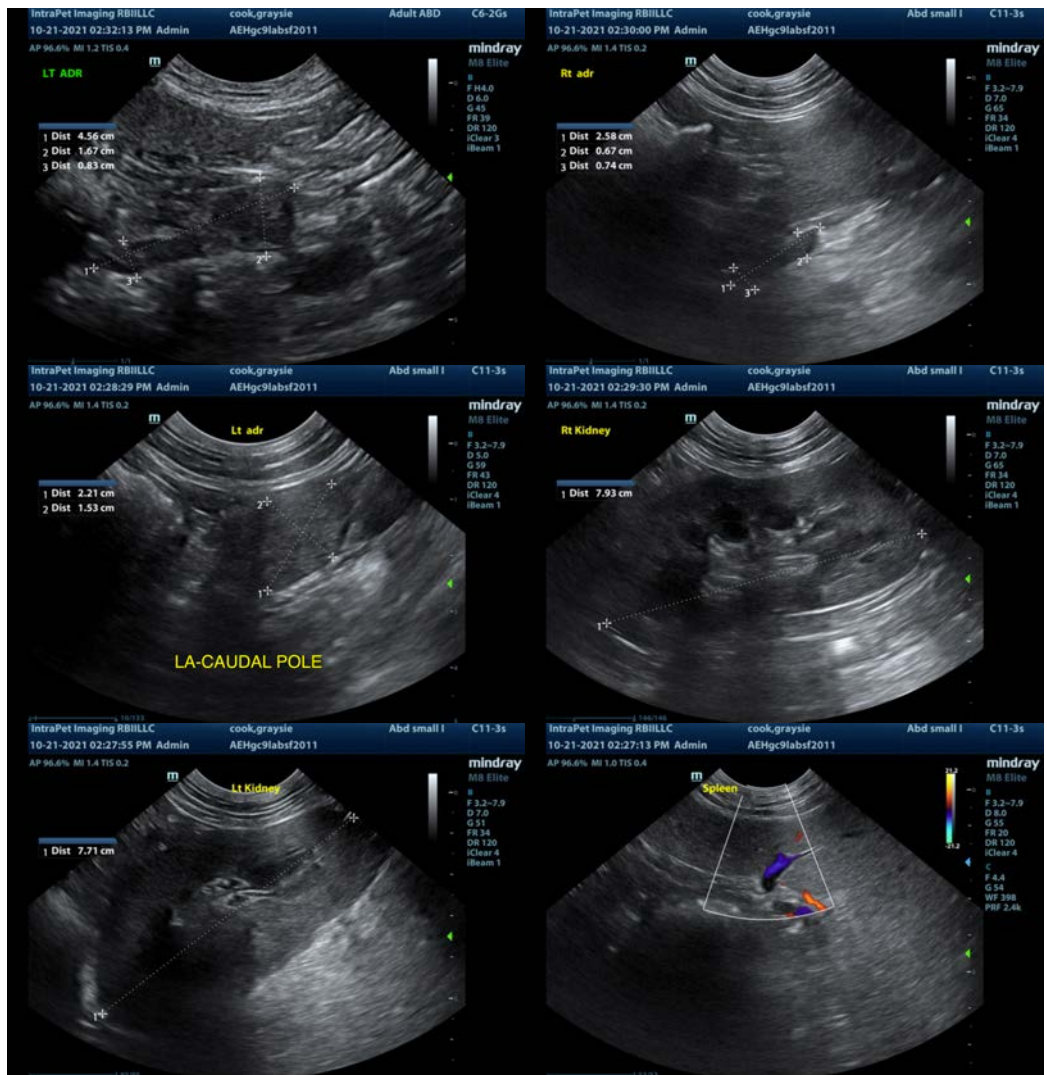
- Mottled spleen – The diffuse splenic changes are non-specific and could be consistent with lymphoid hyperplasia, extramedullary hematopoiesis, infiltrative neoplasia, inflammation, other. Cytology or histopathology would be necessary to get a definitive diagnosis.
- Mass effect in the caudal pole of the left adrenal gland – Left adrenomegaly could be consistent with neoplasia (e.g., adenoma, carcinoma, pheochromocytoma), hyperplasia, inflammation, other.
- Heterogeneous liver – The diffuse hepatic changes are non-specific and could be consistent with vacuolar hepatopathy, nodular hyperplasia, inflammatory/immune-mediated disease, fibrosis, extramedullary hematopoiesis, toxic hepatopathy (e.g., copper), infiltrative neoplasia (less likely) or other hepatopathy.

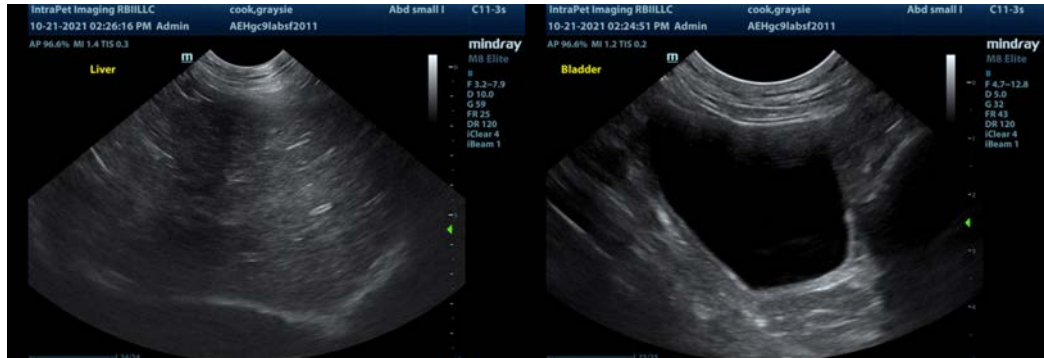
## **SECONDARY FINDINGS**

- Mildly reduced corticomedullary distinction in both kidneys – Mild loss of corticomedullary distinction in both kidneys could be consistent with chronic degenerative disease or interstitial nephrosis.

## INTERPRETATION OF THE FINDINGS & FURTHER RECOMMENDATIONS

It is difficult to link the abnormalities reported in the history with the findings below. These changes are relatively non-specific. There are no large focal abdominal masses. There is no evidence of free fluid in the abdomen, and no focal bowel lesions were observed. The history is suspicious for the possibility of GI blood loss. Correlate with rectal exam findings (is melena present?) Recommend 3-view thoracic radiographs, urine protein/creatinine ratio, liver function test if clinically relevant (to look for a cause of the hypoalbuminemia reported). Recommend a path review on a CBC to look for evidence of regeneration, blood parasites, abnormal cells, etc. to try to determine if this is blood loss, lack of production (primary bone marrow disease), or possible increased destruction/hemolysis of red blood cells.





The information and recommendations provided are based on the images presented by the referring veterinarian. No evaluation can be communicated regarding pathology that was not visible in the image/video clips provided.

Thank you for this referral. If the clinical or image interpretation does not parallel your findings or if I can be of any further assistance please contact me.

Kathleen Sennello DVM,MS, Diplomate ACVIM (Small animal Internal Medicine)  
kathleen.sennello@sonopath.com