

**DATE PRESENTING CLINICAL SIGNS**

10/21/21

Referral for Continued Care.

Pancreatitis.

**PATIENT**

Biscuit Smythers

History: Date: 10-21-2021 Notes: Referral for LE elevation Hx of ruptured corneal ulcer, murmur, on heart meds. Diagnosed previously with pancreatitis and IBS. Liver enzymes persistently elevated. Referral for supportive care and abdominal US.

**SPECIES**

Canine

Assessment: Referral for LE elevation. History of ruptured corneal ulcer, murmur - on heart meds. Diagnosed previously with pancreatitis and IBS. Liver enzymes persistently elevated. Referral for supportive care and abdominal US.

**BREED**

Dachshund

Date of Previous IntraPet Ultrasound: no previous  
Sedation: not needed  
Stat Report: not requested

**SEX**

Spayed Female

**ULTRASONOGRAPHIC EXAMINATION OF THE ABDOMEN****Urinary System**

The urinary bladder is moderately distended with anechoic urine. The Bladder wall, trigone, ureteral papillae and visible urethra (to a depth of 2cm) appear normal with no evidence of wall thickening, mucosal irregularities, masses or cystic calculi.

**AGE**

2011

The left kidney has a normal shape and size (3.81 cm). Overall echogenicity is normal with adequate corticomedullary distinction and a typical 1:3 cortex:medulla ratio. There is no evidence of perinephric inflammation or effusion. There is no evidence of pyelectasia, nephroliths, infarcts or hydroureter. Renal vasculature is normal.

**INTERPRETED BY**

Kathleen Sennello  
DVM, MS, Diplomate  
ACVIM (Small Animal  
Internal Medicine)

The right kidney has a normal shape and size (3.33 cm). Overall echogenicity is normal with adequate corticomedullary distinction and a typical 1:3 cortex:medulla ratio. There is no evidence of perinephric inflammation or effusion. mild pyelectasia was noted and measured 0.11 cm. There is no evidence of nephroliths, infarcts or hydroureter. Renal vasculature is normal.

**HOSPITAL NAME**

Animal Emergency  
Hospital

**Adrenal Glands**

The left adrenal gland is normal in size measuring 0.48 cm at the caudal pole It is observed in its normal position cranial to the left renal artery. It is normal in appearance (uniformly hypoechoic) and shape with no evidence of a mass effect.

**REFERRING VET**

Dr. Ruby

The right adrenal gland is normal in size measuring 0.47 cm at the caudal pole It is observed in its normal position between the cranial aspect of the right kidney and the caudal vena cava. It is normal in appearance (uniformly hypoechoic) and shape with no evidence of a mass effect.

**INVOICE**

92564

**Spleen**

The spleen is subjectively normal in size, echotexture is homogenous, and the splenic capsule is smooth with no irregularities. The blood flow through the hilus and splenic parenchyma appears normal. No focal parenchymal abnormalities are visualized.

### **Liver**

The liver is subjectively normal in size, and echogenicity with smooth peripheral margins. The parenchyma is heterogenous in echotexture with subtle, indistinct focal mottling. The visible portions of the vasculature and biliary tract appear normal. No focal nodules or cystic lesions are observed. The gallbladder lumen is moderately distended. The wall of the gallbladder is not thickened and has a smooth mucosal surface. Luminal contents are primarily anechoic. The cystic and common bile ducts are normal/not visible.

### **Gastrointestinal**

The stomach is moderately dilated with fluid and irregular shadowing material most consistent with normal ingesta and gas. It measures at a normal thickness of <0.7cm with some variability due to the presence of rugal folds. The distinction of the gastric wall layering is adequate and there is no impression of reduced peristaltic activity. No masses or focal lesions were observed.

The visualized areas of duodenum, jejunum and ileum have a relatively uniform diameter with minimal fluid distension. Wall thickness is normal. Bowel loops follow a curvilinear path with distinct wall layering maintaining the typical 1:3 muscularis:mucosa layer ratio. The duodenum measured as normal (0.33 cm) and the jejunum measured as normal (0.23 cm). Visualized peristalsis appears appropriate. There were no focal lesions consistent with obstruction or a mass effect observed.

The ileocecal junction was visualized and exhibited normal intact wall layering and is subjectively of normal thickness. Sections of colon are visualized with formed fecal material and gas shadowing distally. There is no observed focal or generalized colon wall thickening or loss of layering.

### **Pancreas**

The pancreas is prominent and mottled compared to the surrounding isoechoic mesentery. There is no evidence of nodules or cystic lesions. There is no evidence of regional mesenteric inflammation or fluid.

### **Free Abdomen**

Evaluation of the peritoneal cavity did not reveal any evidence of effusion, or subjective lymphadenomegaly. The Medial iliac nodes appear normal and there was no evidence of a caudal aortic thrombus at the bifurcation. The omentum is of normal uniform echogenicity.

## **ULTRASONOGRAPHIC FINDINGS**

### **PRIMARY FINDINGS:**

Large, heterogenous liver. The diffuse hepatic changes are non-specific and could be consistent with vacuolar hepatopathy, nodular hyperplasia, inflammatory/immune-mediated disease, fibrosis, extramedullary hematopoiesis, toxic hepatopathy (e.g., copper), infiltrative neoplasia (less likely) or other hepatopathy.

Prominent, mottled pancreas. The pancreatic changes are most consistent with mild pancreatitis or a recent episode of pancreatic inflammation.

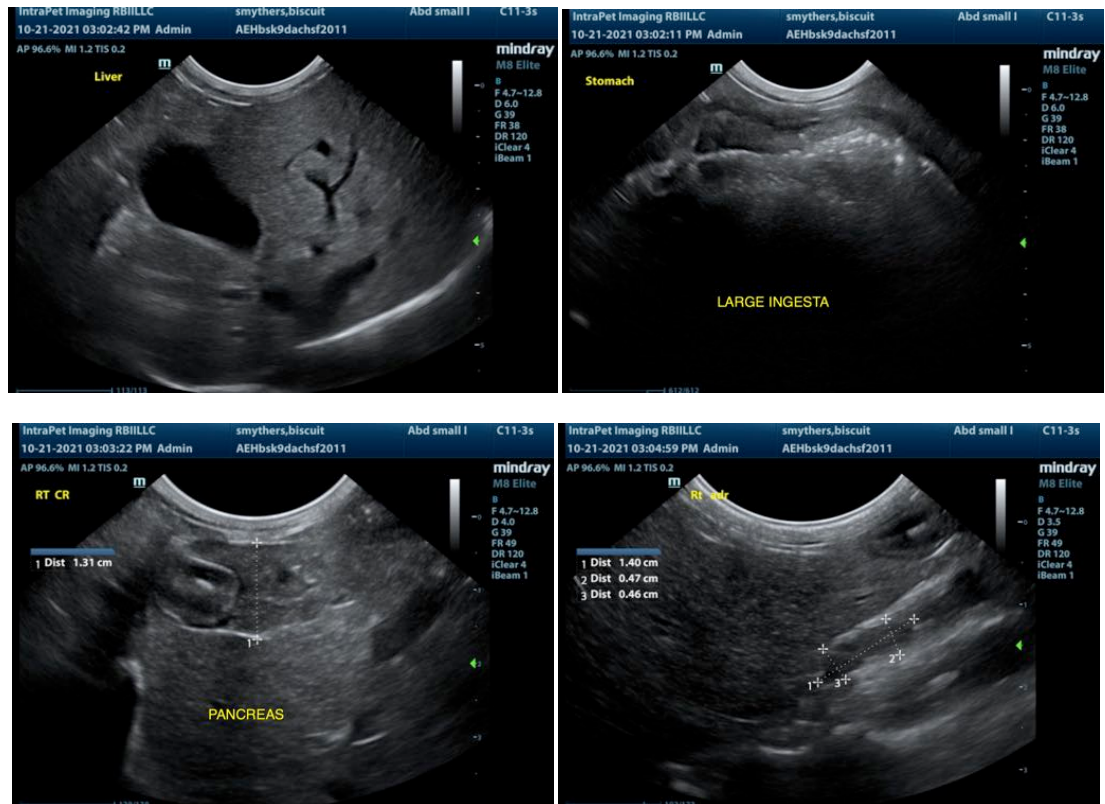
### **SECONDARY FINDINGS:**

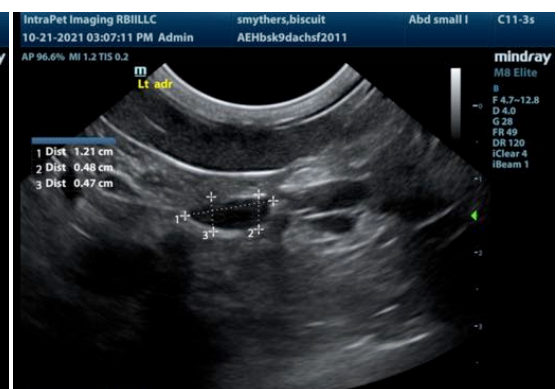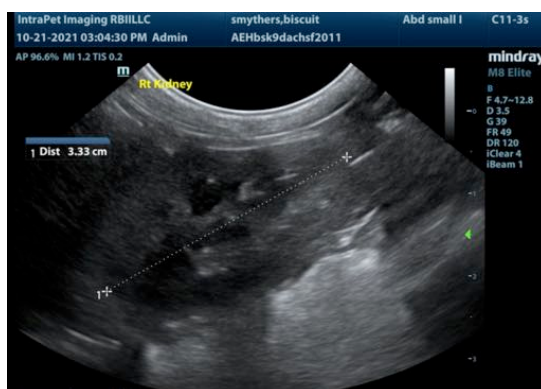
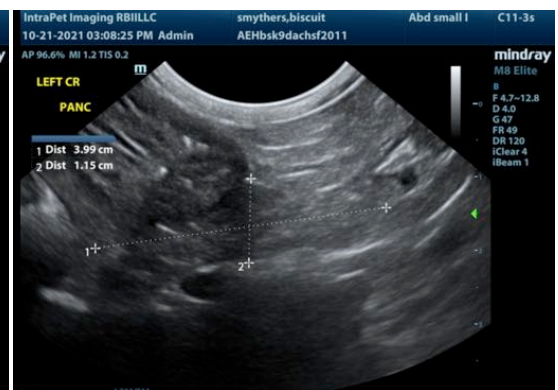
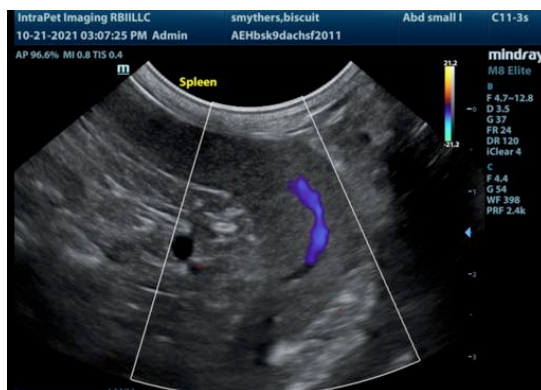
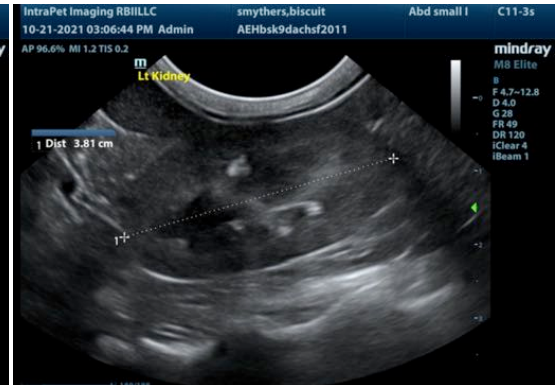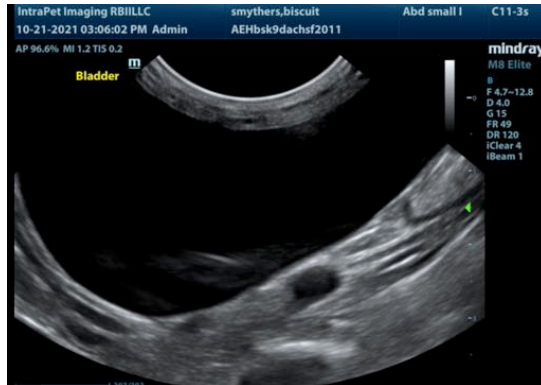Large amount of ingesta in the gastric lumen. Correlate with feeding history. If the patient was not recently fed consider delayed gastric emptying or partial outflow tract obstruction. Ingesta hinders evaluation of the stomach and some cranial abdominal structures.

### INTERPRETATION OF THE FINDINGS & FURTHER RECOMMENDATIONS

No focal lesions were visualized involving the liver or gallbladder so the findings would be consistent with a primary hepatopathy. If the patient is still on Phenobarbital there is a likely correlation here. I recommend a liver function test, Phenobarbital levels and if the patient is not feeling well possible FNA of the liver to look for evidence of round cell neoplasia. If Phenobarb toxicity is present this can progress to liver failure. Ideally transition to a less hepatotoxic seizure medication would be ideal. I recommend consultation with a veterinary neurologist regarding this protocol as you cannot abruptly stop the Phenobarbital without risk of break through seizures.

Additionally the pancreas is prominent. It appears most consistent with either mild inflammation or previous resolving inflammation. Correlate with a GI panel with a quantitative PLI, TLI, cobalamin and folate to get further information on the GI tract and pancreas.





The information and recommendations provided are based on the images presented by the referring veterinarian. No evaluation can be communicated regarding pathology that was not visible in the image/video clips provided.

Thank you for this referral. If the clinical or image interpretation does not parallel your findings or if I can be of any further assistance please contact me.

Kathleen Sennello DVM,MS, Diplomate ACVIM (Small animal Internal Medicine)  
 kathleen.sennello@sonopath.com