



**PATIENT PRESENTING CLINICAL SIGNS**

Anders Syett Anxiety issues, chews feet. Been on Hepatosupport since Sept 2021.  
Abnormal PE/Chem/CBC/UA Results: Sept 9 -ALKP 1500, Oct 2 ALKP over 2000

**SPECIES ULTRASONOGRAPHIC EXAMINATION OF THE ABDOMEN**

Canine

**Urinary System**

**BREED**

Poodle X

The urinary bladder is moderately distended with mild primarily suspended echogenic debris present. The Bladder wall, trigone, ureteral papillae and visible urethra (to a depth of 2cm) appear normal with no evidence of wall thickening, mucosal irregularities, or masses. There is shadowing, mineralized debris dependent in the urinary bladder, which could be consistent with small stones or a pile of sandy debris. Correlate with abdominal radiographs. Recommend urinalysis and culture.

**SEX**

Neutered Male

The prostate is normal in size and shape for this neutered male dog. The parenchyma is homogenous and the external margins are smooth. The prostatic urethra appears normal with no evidence of irregularity, invasion, mass effect or calculi.

**AGE**

9 Years

The left kidney has a normal shape and size (5.18 cm) with pinpoint, non-obstructive nephroliths. Overall echogenicity is slightly hyperechoic with poor corticomedullary distinction and a typical 1:3 cortex:medulla ratio. There is no evidence of perinephric inflammation or effusion. There is no evidence of pyelectasia, infarcts or hydroureter. Renal vasculature is normal.

**WEIGHT**

14.6 kg

The right kidney has a normal shape and size (5.34 cm) with pinpoint non-obstructive nephroliths. Overall echogenicity is slightly hyperechoic with poor corticomedullary distinction and a typical 1:3 cortex:medulla ratio. There is no evidence of perinephric inflammation or effusion. There is no evidence of pyelectasia, infarcts or hydroureter. Renal vasculature is normal.

**INTERPRETED BY**

Kathleen Sennello DVM,  
MS, Diplomate ACVIM  
(Small Animal Internal  
Medicine)

**Adrenal Glands**

The left adrenal gland is normal in size measuring 0.51 cm at the caudal pole. It is observed in its normal position cranial to the left renal artery. It is normal in appearance (uniformly hypoechoic) and shape with no evidence of a mass effect.

**IMAGING PERFORMED BY**

Crystal Hill

The right adrenal gland is normal in size measuring 0.56 cm at the caudal pole. It is observed in its normal position between the cranial aspect of the right kidney and the caudal vena cava. It is normal in appearance (uniformly hypoechoic) and shape with no evidence of a mass effect.

**HOSPITAL NAME**

Queensway AH

**Spleen**

The spleen is subjectively normal in size, echotexture is homogenous, and the splenic capsule is smooth with no irregularities. The blood flow through the hilus and splenic parenchyma appears normal. No focal parenchymal abnormalities are visualized.

**REFERRING VET**

Dr. Hill

**Liver**

The liver is subjectively normal in size and hyperechoic with smooth peripheral margins. The parenchyma is heterogenous in echotexture with subtle, indistinct focal mottling. The visible portions of the vasculature and biliary tract appear normal. There are numerous ill-defined, patchy, hypoechoic nodules within the parenchyma varying in size from 0.25-0.21 cm.

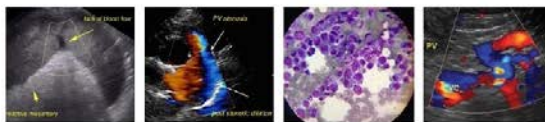
**INVOICE**

26585

**DATE**

10/21/21

The gallbladder lumen is moderately distended. The wall of the gall bladder is not thickened and has a smooth mucosal surface. Luminal contents are primarily anechoic. The cystic and common bile ducts are normal/not visible.



**PATIENT**

***Gastrointestinal***

Anders Syett

The stomach contains minimal luminal contents. It measures at a normal thickness of <0.7cm with some variability due to the presence of rugal folds. The distinction of the gastric wall layers is adequate and there is no impression of reduced peristaltic activity. No masses or focal lesions were observed.

**SPECIES**

Canine

The visualized areas of duodenum, jejunum and ileum have a relatively uniform diameter with minimal fluid distension. Wall thickness is normal. Bowel loops follow a curvilinear path with distinct wall layering maintaining the typical 1:3 muscularis:mucosa layer ratio. Jejunum wall measured 0.28 cm.

**BREED**

Poodle X

Visualized peristalsis appears appropriate. There were no focal lesions consistent with obstruction or a mass effect observed.

**SEX**

Neutered Male

The ileocecal junction was visualized and exhibited normal intact wall layering and is subjectively of normal thickness. Sections of colon are visualized with formed fecal material and gas shadowing distally. There is no observed focal or generalized colon wall thickening or loss of layering.

**AGE**

9 Years

***Pancreas***

The pancreas is normal and isoechoic to surrounding mesentery. There is no evidence of nodules or cystic lesions. There is no evidence of regional mesenteric inflammation or fluid.

**WEIGHT**

14.6 kg

***Free Abdomen***

Evaluation of the peritoneal cavity did not reveal any evidence of effusion, or subjective lymphadenomegaly. The Medial iliac nodes appear normal and there was no evidence of a caudal aortic thrombus at the bifurcation. The omentum is of normal uniform echogenicity.

**PRIMARY FINDINGS**

- Heterogeneous, hyperechoic liver with indistinct hypoechoic nodules – The diffuse hepatic changes are non-specific and could be consistent with vacuolar hepatopathy, nodular hyperplasia, inflammatory/immune-mediated disease, fibrosis, extramedullary hematopoiesis, toxic hepatopathy (e.g., copper), infiltrative neoplasia (less likely) or other hepatopathy.
- Echogenic urine in the urinary bladder with dependent mineralized debris – correlate with abdominal radiographs. This is likely small stone or mineralized, sandy debris.

**SECONDARY FINDINGS**

- Mildly decreased corticomedullary distinction in both kidneys with non-obstructive nephroliths – Mild loss of corticomedullary distinction in both kidneys could be consistent with chronic degenerative disease or interstitial nephrosis. The hyperechoic mineralized foci observed at the corticomedullary junction of the left/right kidney are consistent with small, non-obstructive nephroliths.

**INTERPRETATION OF THE FINDINGS & FURTHER RECOMMENDATIONS**

No significant focal lesions were identified associated with the liver or biliary tract. An elevation in ALP is a common finding. However, in general, these elevations fall into 3 primary categories: induction phenomena, biliary disease (seems unlikely based on ultrasound results), and primary liver disorders.

- Induction phenomena are the most common cause for an elevated ALP. These are systemic illnesses that 'turn on' the liver enzyme. Causes of this include Cushing's disease, dental disease, arthritis, and numerous others. In many cases the exact cause is unclear but as long as ultrasound and bile acids tests are normal most patients do not have progressive changes in their liver. While liver biopsy is not routinely performed, vacuolar hepatopathy, is noted on most biopsies. This is often non-progressive but in rare cases can be more severe and lead to liver failure.

**INTERPRETED BY**

Kathleen Sennello DVM,  
MS, Diplomate ACVIM  
(Small Animal Internal  
Medicine)

**IMAGING PERFORMED BY**

Crystal Hill

**HOSPITAL NAME**

Queensway AH

**REFERRING VET**

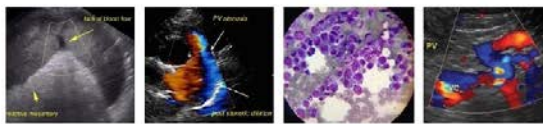
Dr. Hill

**INVOICE**

26585

**DATE**

10/21/21



**PATIENT**

Anders Syett

- If signs of cushings disease are present recommend endocrine function testing to evaluate for cushings disease.

**SPECIES**

Canine

- Consider fine needle aspirate to rule out round cell neoplasia if this is a concern.
- If a cause for the ALP elevation is not identified: I recommend recheck general blood work every 6 months, ultrasound once per year, and bile acids test every 1-2 years based on other results. If the ALP continues to climb a biopsy could be considered.

**BREED**

Poodle X

- Consider long term use of denamarin, and monitoring for the signs of cushings developing.

**SEX**

Neutered Male

- A primary vacuolar hepatopathy can be breed related and is seen in Scottish Terriers, Schnauzers, Cocker spaniels etc..

**AGE**

9 Years

**WEIGHT**

14.6 kg

**INTERPRETED BY**

Kathleen Sennello DVM,  
MS, Diplomate ACVIM  
(Small Animal Internal  
Medicine)

**IMAGING  
PERFORMED BY**

Crystal Hill

**HOSPITAL NAME**

Queensway AH

**REFERRING VET**

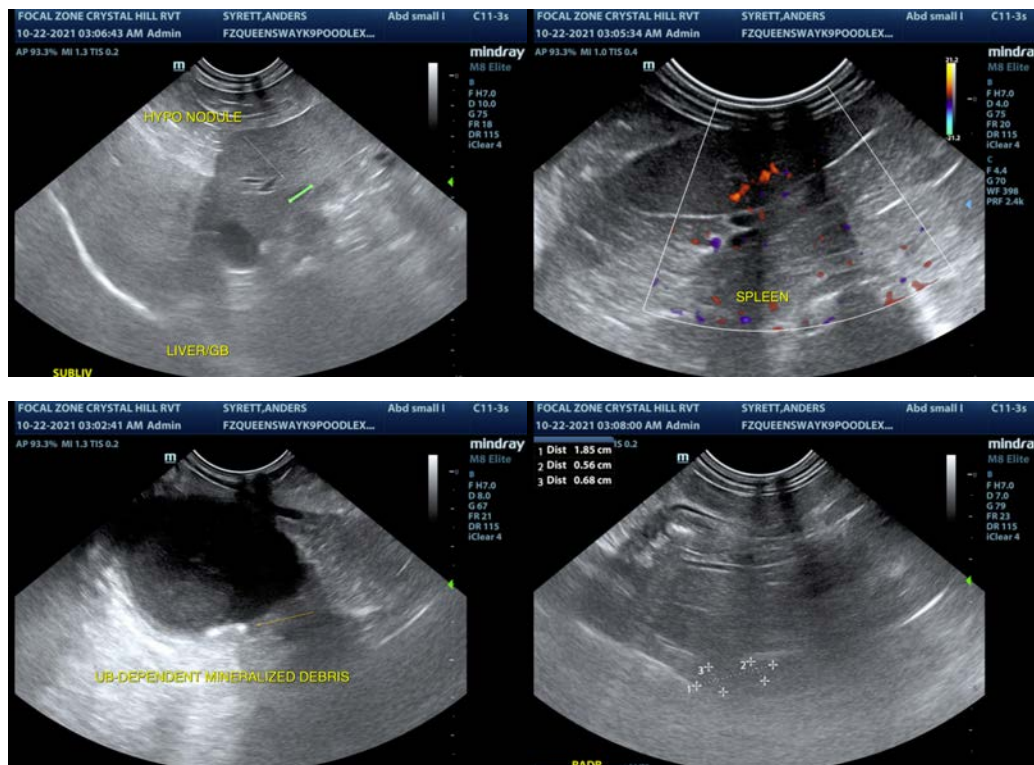
Dr. Hill

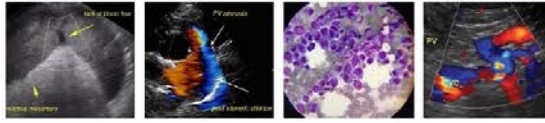
**INVOICE**

26585

**DATE**

10/21/21





**PATIENT**

Anders Syett

**SPECIES**

Canine

**BREED**

Poodle X

**SEX**

Neutered Male

**AGE**

9 Years

**WEIGHT**

14.6 kg

**INTERPRETED BY**

Kathleen Sennello DVM,  
MS, Diplomate ACVIM  
(Small Animal Internal  
Medicine)

**IMAGING  
PERFORMED BY**

Crystal Hill

**HOSPITAL NAME**

Queensway AH

**REFERRING VET**

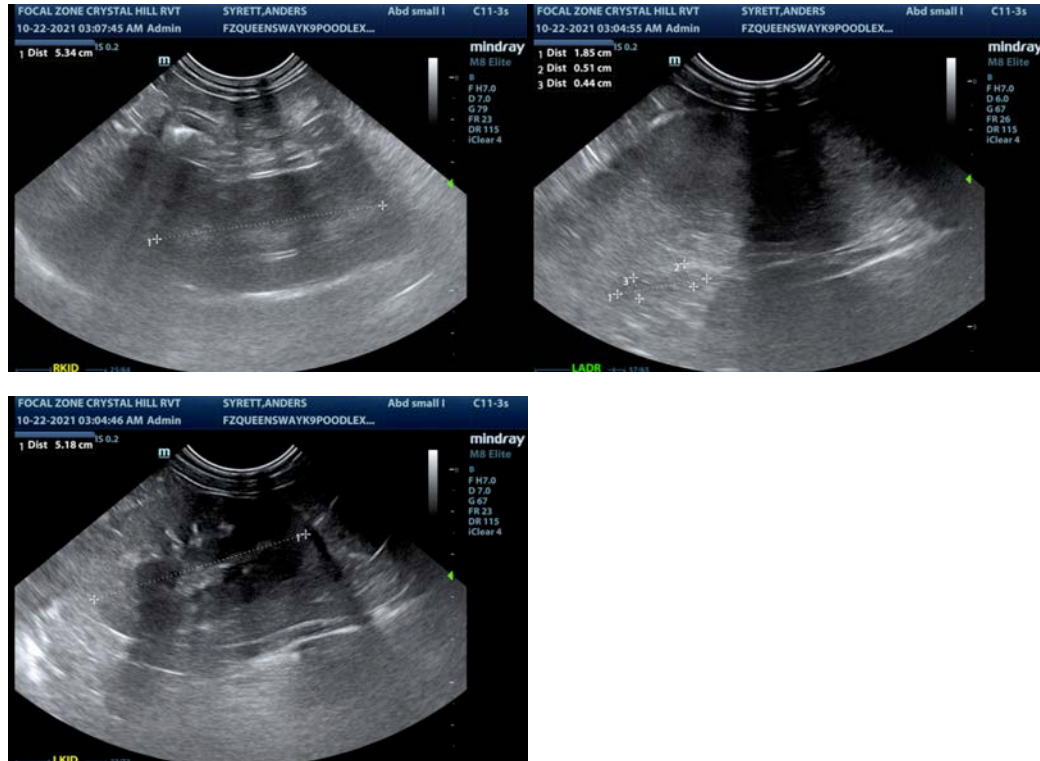
Dr. Hill

**INVOICE**

26585

**DATE**

10/21/21



The information and recommendations provided are based on the images presented by the referring veterinarian. No evaluation can be communicated regarding pathology that was not visible in the image/video clips provided.

Thank you for this referral. If the clinical or image interpretation does not parallel your findings or if I can be of any further assistance please contact me.

Kathleen Sennello DVM,MS, Diplomate ACVIM (Small animal Internal Medicine)

kathleen.sennello@sonopath.com