



PATIENT

Juliet Hendrickson

PRESENTING CLINICAL SIGNS

P has chronic atopy and is obese. P has been on Temaril-P for many years. On presentation back in 4/2022 p was on Temaril-P #3 daily, currently on #1 daily and Atopica 150mg daily. Not able to decrease any further. P has chronic ALP elevation which are not much improved after decreasing Temaril-P.

SPECIES

Canine

BREED

Mix

Abnormal PE/Chem/CBC/UA Results: 4/2022: on Tremaril-P #3 daily CBC: monos: 1040H Chem: ALP: 1801HH, creat: 0.8, choles: 377H, triglyc: 808H, T4: 1.8 6/2022: On Apoquel and Temaril P , prior to starting Atopica CBC: plt ct: 414H Chem; ALP: 555H 7/2022: On atopica but higher Temaril-P dose CBC:NSF Chem: ALP: 1745 8/2022: same Atopica dose, lower Temaril P dose CBC: WNL Chem: ALP: 1049H 10/22: O Atopica 150mg and Temaril-P #1 daily CBC: plt ct: 433H; Chem: ALP: 1448H UA: SG: 1.017, pH: 8.5H, bacteruria

SEX

Spayed Female

ULTRASONOGRAPHIC EXAMINATION OF THE ABDOMEN

Urinary System

The urinary bladder is moderately distended with anechoic urine. The Bladder wall, trigone, ureteral papillae and visible urethra (to a depth of 2cm) appear normal with no evidence of wall thickening, mucosal irregularities, masses or cystic calculi.

AGE

6 Years

The left kidney has a normal shape and size (6.59 cm). Overall echogenicity is normal with adequate corticomedullary distinction and a typical 1:3 cortex:medulla ratio. There is no evidence of focal perinephric inflammation or effusion. There is no evidence of pyelectasia, nephroliths, infarcts or hydroureter. Renal vasculature is normal.

WEIGHT

64.5 Pounds

The right kidney has a normal shape and size (6.61 cm). Overall echogenicity is normal with adequate corticomedullary distinction and a typical 1:3 cortex:medulla ratio. There is no evidence of focal perinephric inflammation or effusion. There is no evidence of pyelectasia, nephroliths, infarcts or hydroureter. Renal vasculature is normal.

INTERPRETED BY

Kathleen Sennello DVM,
MS, Diplomate ACVIM
(Small Animal Internal
Medicine)

Adrenal Glands

The left adrenal gland is normal in size measuring 0.39 cm at the caudal pole. It is observed in its normal position cranial to the left renal artery. It is normal in appearance (uniformly hypoechoic) and shape with no evidence of a mass effect.

IMAGING PERFORMED BY

Dr. Megan Cassels-
Conway

The right adrenal gland is normal in size measuring 0.62 cm at the caudal pole. It is observed in its normal position between the cranial aspect of the right kidney and the caudal vena cava. It is normal in appearance (uniformly hypoechoic) and shape with no evidence of a mass effect.

HOSPITAL NAME

Central Broward AH

Spleen

The spleen is subjectively normal in size, echotexture is homogenous, and the splenic capsule is smooth with no irregularities. The blood flow through the hilus and splenic parenchyma appears normal. No focal parenchymal abnormalities are visualized.

REFERRING VET

Dr. Janeen Lezcano

Liver

The liver is subjectively normal in size, and echogenicity with smooth peripheral margins. The parenchyma is heterogenous in echotexture with subtle, indistinct focal mottling. The visible portions of the vasculature and biliary tract appear normal. No focal nodules or cystic lesions are observed.

INVOICE

42223

DATE

10/20/22



PATIENT

Juliet Hendrickson

The gallbladder lumen is moderately distended. The wall of the gall bladder is not thickened and has a smooth mucosal surface. Luminal contents are mild and primarily anechoic. The cystic and common bile ducts are normal/not visible.

SPECIES

Canine

Gastrointestinal

The stomach contains minimal luminal contents. It measures at a normal thickness of <0.7cm with some variability due to the presence of rugal folds. The distinction of the gastric wall layers is adequate and there is no impression of reduced peristaltic activity. No masses or focal lesions were observed.

BREED

Mix

The visualized areas of duodenum, jejunum and ileum have a relatively uniform diameter with minimal fluid distension. Wall thickness is normal. Bowel loops follow a curvilinear path with distinct wall layering maintaining the typical 1:3 muscularis:mucosa layer ratio. Jejunum wall measures 0.31 cm. Visualized peristalsis appears appropriate. There were no focal lesions consistent with obstruction or a mass effect observed.

SEX

Spayed Female

The ileocecal junction was visualized and exhibited normal intact wall layering and is subjectively of normal thickness. Sections of colon are visualized with formed fecal material and gas shadowing distally. There is no observed focal or generalized colon wall thickening or loss of layering.

AGE

6 Years

Pancreas

The pancreas is normal and isoechoic to surrounding mesentery. There is no evidence of nodules or cystic lesions. There is no evidence of regional mesenteric inflammation or fluid.

WEIGHT

64.5 Pounds

Free Abdomen

Evaluation of the peritoneal cavity did not reveal any evidence of effusion, or subjective lymphadenomegaly. The Medial iliac nodes appear normal and there was no evidence of a caudal aortic thrombus at the bifurcation. The omentum is of normal uniform echogenicity.

INTERPRETED BY

Kathleen Sennello DVM,
MS, Diplomate ACVIM
(Small Animal Internal
Medicine)

ULTRASONOGRAPHIC FINDINGS

- Heterogeneous liver – The diffuse hepatic changes are non-specific and could be consistent with vacuolar hepatopathy, nodular hyperplasia, inflammatory/immune-mediated disease, fibrosis, extramedullary hematopoiesis, toxic hepatopathy (e.g., copper), infiltrative neoplasia (less likely) or other hepatopathy.

IMAGING PERFORMED BY

Dr. Megan Cassels-Conway

INTERPRETATION OF THE FINDINGS & FURTHER RECOMMENDATIONS

No focal lesions are visualized associated with the liver, and the gallbladder appears relatively normal, making the ALP elevation likely to represent a primary hepatopathy. I agree the ALP elevation is unlikely to be 100% due to the Temaril-P, but it is likely contributing. Additionally, both adrenal glands appear somewhat flat, which could represent some adrenal suppression from the Temaril-P. These are my recommendations for further evaluation of a primary ALP elevation:

HOSPITAL NAME

Central Broward AH

REFERRING VET

Dr. Janeen Lezcano

The ultrasonographic changes in the liver were relatively mild. Unfortunately, the sonographic changes do not always reflect the severity or cause of the hepatopathy. The scan today supports a primary hepatopathy as no severe biliary changes were observed.

INVOICE

42223

- Consider close evaluation of history for possible toxic changes examine medications, diet, dietary indiscretion etc...
- Consider PCR on urine/serum for leptospirosis (if not on antibiotics)/serology if recent antibiotic history

DATE

10/20/22



PATIENT

Juliet Hendrickson

SPECIES

Canine

BREED

Mix

SEX

Spayed Female

AGE

6 Years

WEIGHT

64.5 Pounds

INTERPRETED BY

Kathleen Sennello DVM,
MS, Diplomate ACVIM
(Small Animal Internal
Medicine)

**IMAGING
PERFORMED BY**

Dr. Megan Cassels-
Conway

HOSPITAL NAME

Central Broward AH

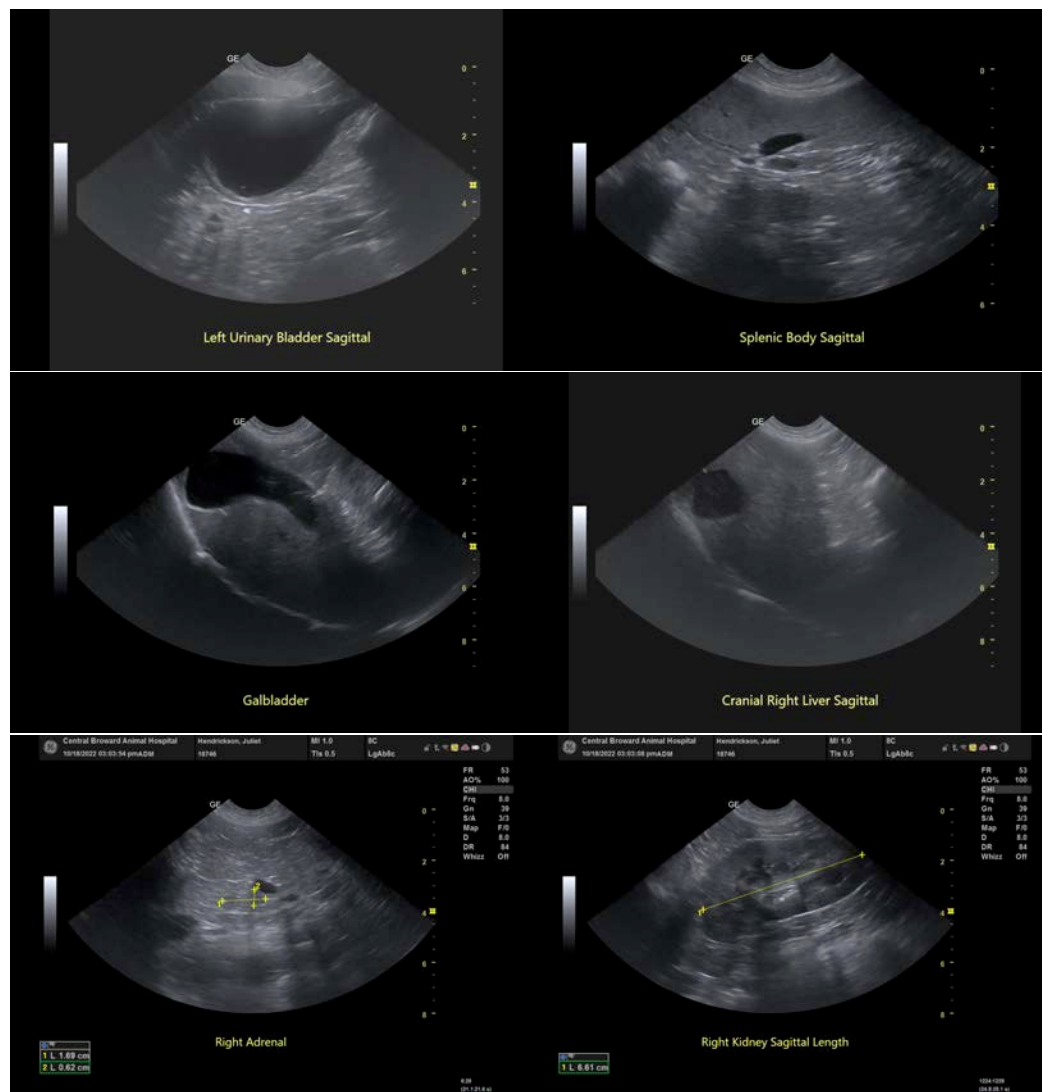
REFERRING VET

Dr. Janeen Lezcano

- If not already done, consider pre and post prandial bile acids to evaluate liver function
- If the ALP is significantly elevated relative to the ALT and symptoms consistent with Cushing's are present, consider adrenal function testing (ACTH stim). Adrenal function testing would not be considered unless this patient was off Tamaril-P for 6-8 weeks.

- Consider Fine needle aspirate if round cell neoplasia is on your differential list (25 g needle, normal coags)

- If no response to supportive care (Denamarin, fluids, antibiotics, +/- ursodiol etc.) Consider liver biopsy with samples obtained for histopathology, culture, and copper levels.



INVOICE

42223

DATE

10/20/22



PATIENT

Juliet Hendrickson

SPECIES

Canine

BREED

Mix

SEX

Spayed Female

AGE

6 Years

WEIGHT

64.5 Pounds

INTERPRETED BY

Kathleen Sennello DVM,
MS, Diplomate ACVIM
(Small Animal Internal
Medicine)

**IMAGING
PERFORMED BY**

Dr. Megan Cassels-
Conway

HOSPITAL NAME

Central Broward AH

REFERRING VET

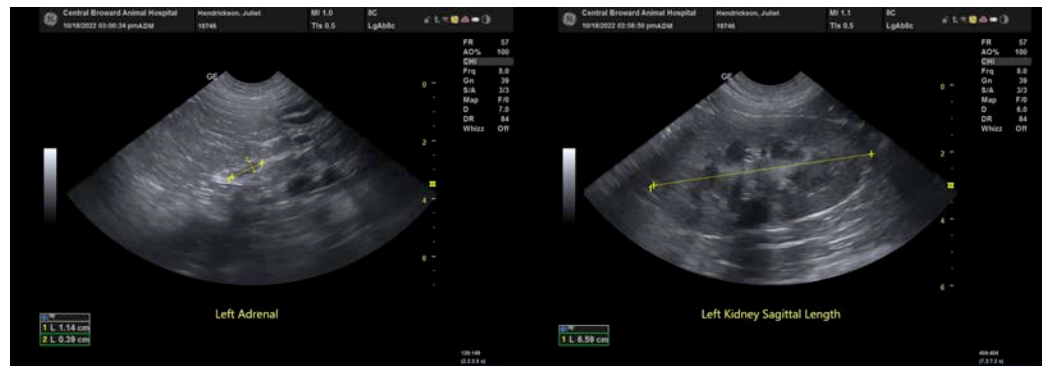
Dr. Janeen Lezcano

INVOICE

42223

DATE

10/20/22



The information and recommendations provided are based on the images presented by the referring veterinarian/sonographer. No evaluation can be communicated regarding pathology that was not visible in the image/video clips provided.

Thank you for this referral. If the clinical or image interpretation does not parallel your findings or if I can be of any further assistance please contact me.

Kathleen Sennello DVM,MS, Diplomate ACVIM (Small animal Internal Medicine)

kathleen.sennello@sonopath.com