

IMAGING PERFORMED BY

IntraPet.com



SonoPath

Clinical Sonography & Telecytology

EDUCATIONAL TELECONSULTATION SERVICES™

1-800-838-4268 info@sonopath.com SonoPath.com

DATE PRESENTING CLINICAL SIGNS

10/20/22 CKD recheck. Anemia / hematuria.

PATIENT Current Medications: Gabapentin 50mg BID, Bravecto q60d.

Buffy Bast Lab Results: Anemia/hematuria.
Date of Previous IntraPet Ultrasound: No previous.

SPECIES Sedation: IM sedation.
Stat Report: STAT requested.

Feline ULTRASONOGRAPHIC EXAMINATION OF THE ABDOMEN

BREED *Urinary System*

DSH The urinary bladder is moderately distended with anechoic urine. The Bladder wall, trigone, ureteral papillae and visible urethra (to a depth of 2cm) appear normal with no evidence of wall thickening, mucosal irregularities, masses or cystic calculi.

SEX The left kidney has a normal shape and size (3.52 cm). Overall echogenicity is slightly hyperechoic with mildly reduced corticomedullary distinction and a typical 1:3 cortex:medulla ratio. There is no evidence of focal perinephric inflammation or effusion. There is no evidence of pyelectasia, nephroliths, infarcts or hydroureter. Renal vasculature is normal.

Spayed Female

AGE The right kidney has a normal shape and size (3.43 cm). Overall echogenicity is slightly hyperechoic with mildly reduced corticomedullary distinction and a typical 1:3 cortex:medulla ratio. There is no evidence of focal perinephric inflammation or effusion. There is no evidence of pyelectasia, nephroliths, infarcts or hydroureter. Renal vasculature is normal.

1/4/18

WEIGHT

8 Pounds

INTERPRETED BY

Kathleen Sennello DVM,
MS, Diplomate ACVIM
(Small Animal Internal
Medicine)

Adrenal Glands

The left adrenal gland is normal in size measuring 0.29 cm at the caudal pole. It is observed in its normal position cranial to the left renal artery. It is normal in appearance (uniformly hypoechoic) and shape with no evidence of a mass effect.

The right adrenal gland is normal in size measuring 0.30 cm at the caudal pole. It is observed in its normal position between the cranial aspect of the right kidney and the caudal vena cava. It is normal in appearance (uniformly hypoechoic) and shape with no evidence of a mass effect.

IMAGING PERFORMED BY

Rachel Brilhart RDMS

Spleen

The spleen is subjectively normal in size, echotexture is homogenous, and the splenic capsule is smooth with no irregularities. The blood flow through the hilus and splenic parenchyma appears normal. No focal parenchymal abnormalities are visualized.

HOSPITAL NAME

Cat Hospital at Towson

Liver

The liver is subjectively normal in size, and echogenicity with smooth peripheral margins. The parenchyma is homogenous echotexture. The visible portions of the vasculature and biliary tract appear normal. No focal nodules or cystic lesions are observed.

REFERRING VET

Dr. Slaughter

INVOICE

42215

The gall bladder lumen is moderately distended. The wall of the gall bladder is not thickened and has a smooth mucosal surface. There is a moderate amount of non-organized echogenic debris. The cystic and common bile ducts are normal/not visible.

Gastrointestinal

The stomach contains minimal luminal contents. It measures at a normal thickness of <0.36cm with some variability due to the presence of rugal folds. The distinction of the gastric wall layers is adequate and there is no impression of reduced peristaltic activity. No masses or focal lesions were observed.

The visualized areas of duodenum, jejunum and ileum have a uniform diameter with minimal fluid distension. Wall thickness is normal to slightly increased. Bowel loops follow a typical curvilinear path with distinct wall layering, but some areas display a prominent muscularis layer which does not display the typical 1:3 muscularis:mucosa layer ratio. Jejunum wall measures 0.30 cm. Visualized peristalsis appears appropriate. There were no focal lesions consistent with obstruction or a mass effect observed.

The ileocecal junction was visualized and exhibited normal intact wall layering and is subjectively of normal thickness. Sections of colon are visualized with formed fecal material and gas shadowing distally. There is no observed focal or generalized colon wall thickening or loss of layering.

Pancreas

The pancreas is prominent and hypoechoic as compared to the surrounding isoechoic mesentery. There is no evidence of nodules or cystic lesions. There is no evidence of regional mesenteric inflammation or fluid. Prominent pancreatic duct noted at 0.20 cm.

Free Abdomen

Evaluation of the peritoneal cavity did not reveal any evidence of effusion. There is a prominent sublumbar lymph node measuring at 0.36 cm in width. The omentum is of normal echogenicity.

ULTRASONOGRAPHIC FINDINGS

- Subjectively very mildly reduced corticomedullary distinction – Mild loss of corticomedullary distinction in both kidneys could be consistent with chronic degenerative disease or interstitial nephrosis. This is a very subtle subjective change and may be within normal limits for this cat.
- Prominent, mottled pancreas with a prominent pancreatic duct – The pancreatic changes are most consistent with age-related parenchymal remodeling, potentially secondary to a prior inflammatory episode, early fibrosis or chronic pancreatitis.
- Moderate gallbladder debris – The significance of the aggregated gallbladder debris is unclear. This could represent an early mucocele, cholestasis, or may be secondary to fasting. Incidental gall bladder debris is less common in cats.
- Prominent muscularis layer to the small intestine – The small intestinal wall changes could be consistent with an underlying inflammatory process. These types of changes can sometimes be seen in normal older cats. Correlate with clinical signs.
- Prominent/visible sublumbar lymph node – The prominent abdominal lymph nodes are most consistent with reactive lymphadenitis or lymphoid hyperplasia. Neoplastic infiltration is considered less likely.

INTERPRETATION OF THE FINDINGS & FURTHER RECOMMENDATIONS

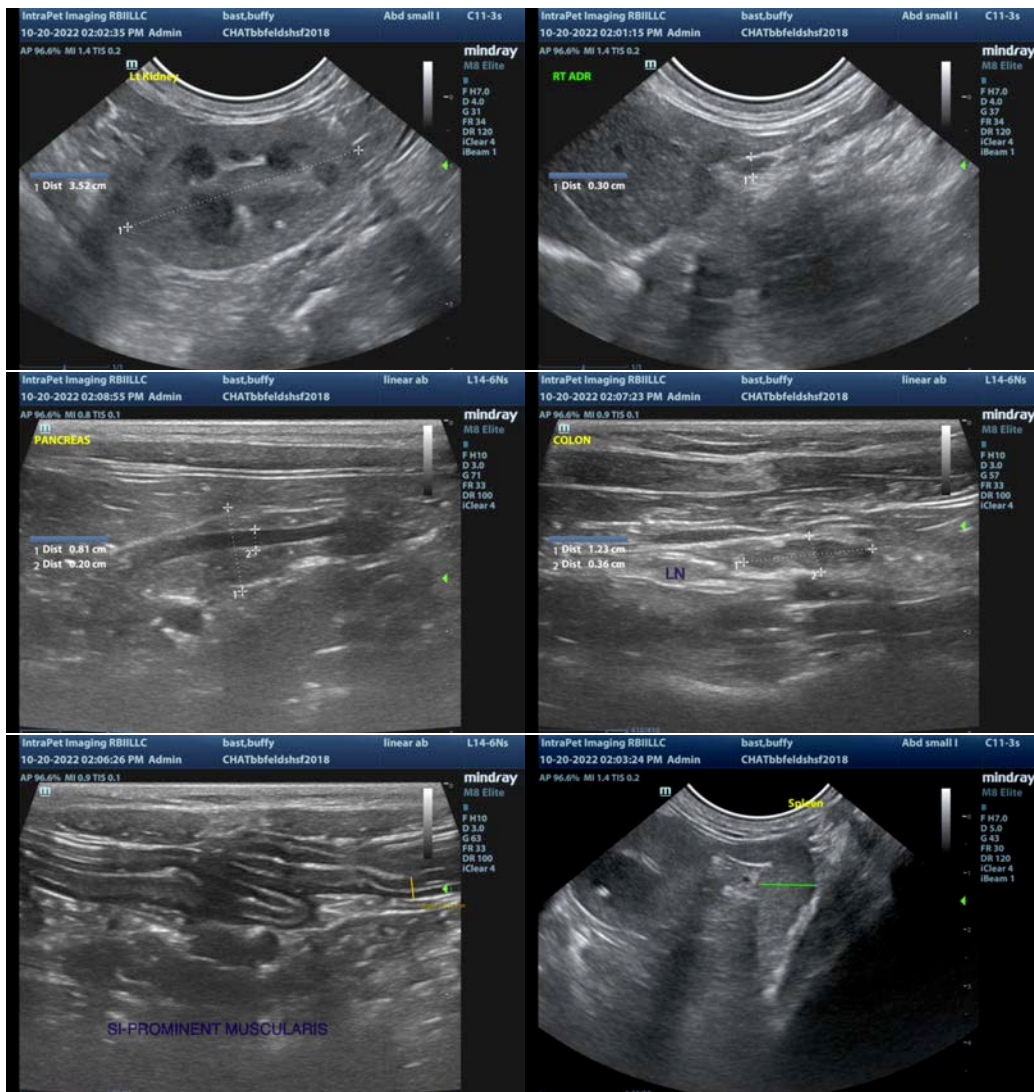
The changes observed on today's scan are mild and somewhat subjective. There is subjectively mildly reduced corticomedullary distinction in the kidneys, but BUN is normal, and SDMA and USG are normal, so significant renal disease is unlikely.

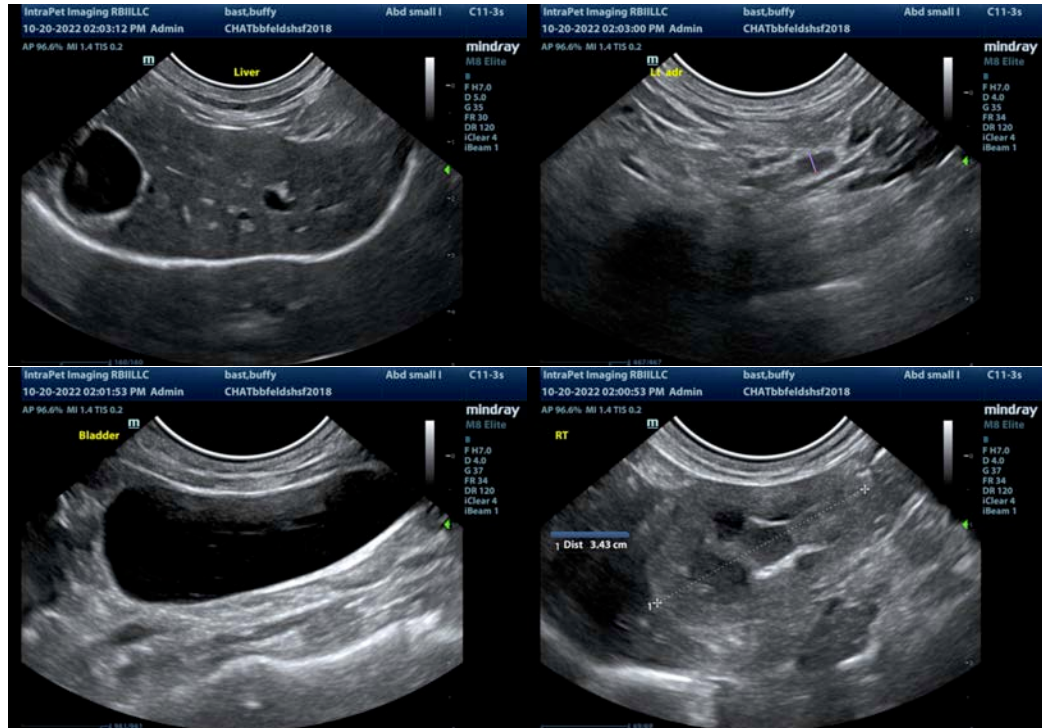
The pancreas is slightly mottled and visible with prominent pancreatic duct. This could represent very mild inflammation or previous episode of pancreatic inflammation.

The muscularis layer of the small intestine is prominent. This can be an indicator of underlying small intestine disease but can also be a normal finding in some older cats. If there is no history of GI symptoms, the significance of this is unclear.

There are no lesions visualized in the urinary tract to explain the hematuria reported. Recommend a urinalysis and culture, and confirmation that this is not iatrogenic hemorrhage from cystocentesis. If there is no evidence of infection, consider possible inflammatory cystitis or recent passing of a bladder stone. The anemia reported is extremely mild. Depending on the clinical status of the patient, I would consider a recheck evaluation to see if the anemia persists.

Recommend three view thoracic radiographs to evaluate for possible concurrent thoracic disease/involvement.





The information and recommendations provided are based on the images presented by the referring veterinarian/sonographer. No evaluation can be communicated regarding pathology that was not visible in the image/video clips provided.

Thank you for this referral. If the clinical or image interpretation does not parallel your findings or if I can be of any further assistance please contact me.

Kathleen Sennello DVM,MS, Diplomate ACVIM (Small animal Internal Medicine)
kathleen.sennello@sonopath.com