



**PATIENT**

Molly Brown

**PRESENTING CLINICAL SIGNS**

Chronic hematuria which owner initially reported as diarrhea. Inappetence, vomiting fever, treated with cephalexin and enrofloxacin which brought her fever down but owners have extreme difficulty getting pills down her so unknown how consistent her treatments were. We started her on liquid amoxi/clav 10/15/21. Still has hematuria, lethargic and seems painful

**SPECIES**

Canine

**ULTRASONOGRAPHIC EXAMINATION OF THE ABDOMEN**

**BREED**

Labradoodle

**Urinary System**

The urinary bladder is moderately distended with a large amount of primarily suspended echogenic debris present. The Bladder wall, trigone, ureteral papillae and visible urethra (to a depth of 2cm) appear normal with no evidence of wall thickening, mucosal irregularities, masses or calculi. Echogenic debris of this type can be associated with small crystals, cellular debris and proteinaceous debris.

**SEX**

Spayed Female

There is a large, hypoechoic and cavitated appearing mass effect measuring approximately 8.4 cm x 7.6 cm in the left cranial abdomen. There is no architecture reminiscent of a kidney in this area, but the left kidney cannot be clearly identified. There is a secondary smaller, more caudal mass effect that appears somewhat related, measuring 4.5 cm and appears hypoechoic and partially cavitated as well. Both mass lesions are surrounded by a small amount of free fluid and hyperechoic omentum.

**AGE**

8 Years

**WEIGHT**

52 Pounds

The right kidney has a normal shape and size (6.8 cm). Overall echogenicity is normal with adequate corticomedullary distinction and a typical 1:3 cortex:medulla ratio. There is no evidence of perinephric inflammation or effusion. There is no evidence of pyelectasia, nephroliths, infarcts or hydroureter. Renal vasculature is normal.

**INTERPRETED BY**

Kathleen Sennello DVM,  
MS, Diplomate ACVIM  
(Small Animal Internal  
Medicine)

**Adrenal Glands**

The left adrenal gland is not clearly visualized. There are two large mass effects in this area likely involving the right kidney and questionably the left adrenal gland (see description under left kidney).

The right adrenal gland is normal in size measuring 0.53 cm at the caudal pole. It is observed in its normal position between the cranial aspect of the right kidney and the caudal vena cava. It is normal in appearance (uniformly hypoechoic) and shape with no evidence of a mass effect.

**IMAGING PERFORMED BY**

Loetitia Saint-Jacques, RVT

**Spleen**

The spleen is subjectively normal in size, echotexture is homogenous, and the splenic capsule is smooth with no irregularities. The blood flow through the hilus and splenic parenchyma appears normal. No focal parenchymal abnormalities are visualized.

**HOSPITAL NAME**

Sierra Animal Wellness

**Liver**

The liver is subjectively normal in size, and echogenicity with smooth peripheral margins. The parenchyma is homogenous echotexture. The visible portions of the vasculature and biliary tract appear normal. No focal nodules or cystic lesions are observed.

**REFERRING VET**

Dr. Peggy Roberts

**INVOICE**

26514

The gallbladder lumen is moderately distended. The wall of the gall bladder is not thickened and has a smooth mucosal surface. Luminal contents are primarily anechoic. The cystic and common bile ducts are normal/not visible.

**DATE**

10/20/21



## PATIENT

Molly Brown

### ***Gastrointestinal***

The stomach contains minimal luminal contents. It measures at a normal thickness of <0.7cm with some variability due to the presence of rugal folds. The distinction of the gastric wall layers is adequate and there is no impression of reduced peristaltic activity. No masses or focal lesions were observed.

## SPECIES

Canine

The visualized areas of duodenum, jejunum and ileum have a relatively uniform diameter with minimal fluid distension. Wall thickness is normal. Bowel loops follow a curvilinear path with distinct wall layering maintaining the typical 1:3 muscularis:mucosa layer ratio. The duodenum measured as normal (between 0.3-0.5cm in wall thickness) and the jejunum measured as normal (between 0.2-0.47cm.)

## BREED

Labradoodle

Visualized peristalsis appears appropriate. There were no focal lesions consistent with obstruction or a mass effect observed.

## SEX

Spayed Female

The ileocecal junction was visualized and exhibited normal intact wall layering and is subjectively of normal thickness. Sections of colon are visualized with formed fecal material and gas shadowing distally. There is no observed focal or generalized colon wall thickening or loss of layering.

## AGE

8 Years

### ***Pancreas***

The pancreas is normal and isoechoic to surrounding mesentery. There is no evidence of nodules or cystic lesions. There is no evidence of regional mesenteric inflammation or fluid.

## WEIGHT

52 Pounds

### ***Free Abdomen***

A small amount of free abdominal fluid is noted, particularly around the left-sided mass effect. No lymphadenomegaly noted. The Medial iliac nodes appear normal and there was no evidence of a caudal aortic thrombus at the bifurcation. The omentum is of increased echogenicity in the area around the abdominal masses.

## INTERPRETED BY

Kathleen Sennello DVM,  
MS, Diplomate ACVIM  
(Small Animal Internal  
Medicine)

### ***Other***

A brief view of the heart was submitted. No significant pericardial effusion was seen.

## IMAGING PERFORMED BY

Loetitia Saint-Jacques, RVT

## HOSPITAL NAME

Sierra Animal Wellness

## REFERRING VET

Dr. Peggy Roberts

## ULTRASONOGRAPHIC FINDINGS

- Two large hypoechoic, somewhat cavitated mass effects in the left cranial abdomen – suspect renal origin, neither the left kidney nor left adrenal gland are visualized. These findings are most concerning for a metastatic neoplasia, although an abscess, benign lesion, etc. cannot be excluded as a possibility.
- Echogenic debris in the urinary bladder – most consistent with the reported blood in the urine. Recommend urinalysis and culture.
- Small amount of free abdominal fluid – consistent with localized peritonitis (likely sterile/or hemorrhage) around the mass lesions.

## INTERPRETATION OF THE FINDINGS & FURTHER RECOMMENDATIONS

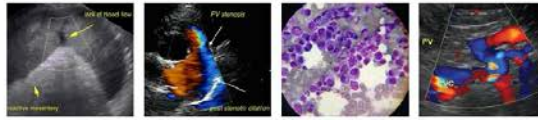
## INVOICE

26514

There are two mass effect in the left cranial abdomen. I suspect this is left kidney in origin, as a normal left kidney is not visualized. The right kidney largely appears normal. Recommend CT scan of the abdomen for surgical planning and possible excision of the abnormal tissue. Recommend 3-view thoracic radiographs and blood pressure evaluation. Concern is high for a neoplastic process.

## DATE

10/20/21



**PATIENT**

Molly Brown

**SPECIES**

Canine

**BREED**

Labradoodle

**SEX**

Spayed Female

**AGE**

8 Years

**WEIGHT**

52 Pounds

**INTERPRETED BY**

Kathleen Sennello DVM,  
MS, Diplomate ACVIM  
(Small Animal Internal  
Medicine)

**IMAGING PERFORMED BY**

Loetitia Saint-Jacques, RVT

**HOSPITAL NAME**

Sierra Animal Wellness

**REFERRING VET**

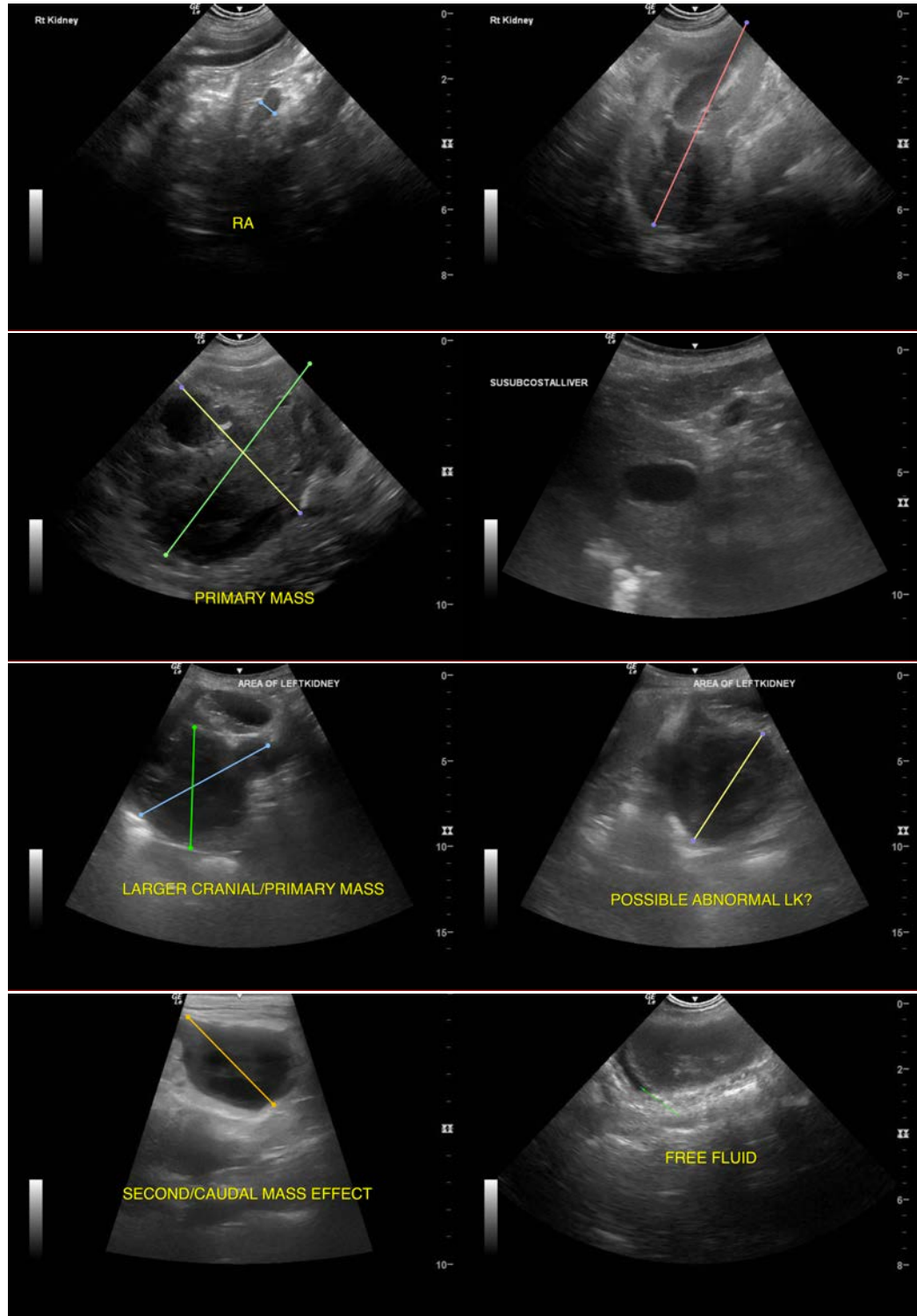
Dr. Peggy Roberts

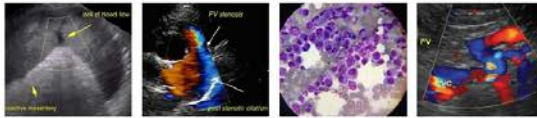
**INVOICE**

26514

**DATE**

10/20/21





**PATIENT**

Molly Brown

**SPECIES**

Canine

**BREED**

Labradoodle

**SEX**

Spayed Female

**AGE**

8 Years

**WEIGHT**

52 Pounds

**INTERPRETED BY**

Kathleen Sennello DVM,  
MS, Diplomate ACVIM  
(Small Animal Internal  
Medicine)

**IMAGING PERFORMED BY**

Loetitia Saint-Jacques, RVT

**HOSPITAL NAME**

Sierra Animal Wellness

**REFERRING VET**

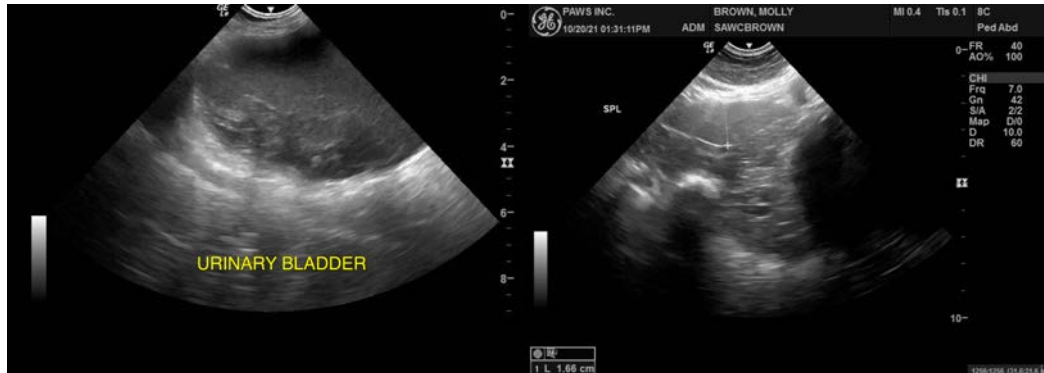
Dr. Peggy Roberts

**INVOICE**

26514

**DATE**

10/20/21



The information and recommendations provided are based on the images presented by the referring veterinarian. No evaluation can be communicated regarding pathology that was not visible in the image/video clips provided.

Thank you for this referral. If the clinical or image interpretation does not parallel your findings or if I can be of any further assistance please contact me.

Kathleen Sennello DVM,MS, Diplomate ACVIM (Small animal Internal Medicine)

kathleen.sennello@sonopath.com