

**DATE PRESENTING CLINICAL SIGNS**

10/20/21 History: Kidney irregular on radiograph per Dr Pierpont. V/D, stumbling around, ADR.

PATIENT

Homer Miller

Current Medications: No current medications.
 Lab Results: ALT =221 / Alk Phos 1264.
 Radiographs: Not provided by the veterinarian.
 Date of Previous IntraPet Ultrasound: No previous IntraPet scans.
 Sedation: Sedation not required for scan.
 Stat Report: STAT report not requested by the veterinarian.

SPECIES

Canine

ULTRASONOGRAPHIC EXAMINATION OF THE ABDOMEN**BREED**

Pit Bull Terrier

Urinary System

The urinary bladder is moderately distended with anechoic urine. The Bladder wall, trigone, ureteral papillae and visible urethra (to a depth of 2cm) appear normal with no evidence of wall thickening, mucosal irregularities, masses or cystic calculi.

SEX

Neutered Male

The prostate is normal in size (0.99 cm) and shape for this neutered male dog. The parenchyma is homogenous and the external margins are smooth. The prostatic urethra appears normal with no evidence of irregularity, invasion, mass effect or calculi.

AGE

10/1/10

The left kidney has a normal shape and size (6.19 cm) with pinpoint non-obstructive nephroliths. Overall echogenicity is normal with adequate corticomedullary distinction and a typical 1:3 cortex:medulla ratio. There is no evidence of perinephric inflammation or effusion. There is no evidence of pyelectasia, infarcts or hydroureter. Renal vasculature is normal.

WEIGHT

44.8 Pounds

The right kidney has a normal shape and size (6.75 cm). Overall echogenicity is normal with adequate corticomedullary distinction and a typical 1:3 cortex:medulla ratio. There is no evidence of perinephric inflammation or effusion. There is no evidence of pyelectasia, nephroliths, infarcts or hydroureter. Renal vasculature is normal.

INTERPRETED BY

Kathleen Sennello DVM,
 MS, Diplomate ACVIM
 (Small Animal Internal
 Medicine)

Adrenal Glands

The left adrenal gland is normal in size measuring 0.9 cm at the cranial pole, 0.83 cm at the caudal pole, and 2.51 cm in length. It is observed in its normal position cranial to the left renal artery. It is somewhat abnormal in appearance in that there is a hyperechoic within the parenchyma of the cranial pole of the adrenal measuring 0.73 cm x 0.54 cm. This does not deform the adrenal. It maintains its normal shape and the general hypoechoic echogenicity in the remaining portion of the adrenal gland.

HOSPITAL NAME

Route 140 Vet Hospital

REFERRING VET

Dr. Pierpont

The right adrenal gland is normal in size measuring 0.8 cm at the caudal pole. It is observed in its normal position between the cranial aspect of the right kidney and the caudal vena cava. It is normal in appearance (uniformly hypoechoic) and shape with no evidence of a mass effect.

INVOICE

26404

Spleen

The spleen is subjectively normal in size and the echotexture is homogenous. The splenic capsule is smooth with no visible irregularities. Rare discrete focal hyperechoic, perivascular parenchymal abnormalities are present. The appearance of these lesions is most consistent with benign splenic myelolipomas. The blood flow through the hilus and splenic parenchyma appears normal. A 0.66 cm hyperechoic nodule was visualized.

Liver

The liver is large in size, and normal in echogenicity with smooth peripheral margins. The parenchyma is mildly heterogenous in echotexture with subtle, indistinct focal mottling. The visible portions of the vasculature and biliary tract appear normal. No focal nodules or cystic lesions are observed.

The gall bladder lumen is moderately distended. The wall of the gall bladder is not thickened and has a smooth mucosal surface. There is a moderate amount of non-organized echogenic debris. The cystic and common bile ducts are normal/not visible.

Gastrointestinal

The stomach contains minimal luminal contents. It measures at a normal thickness of <0.7cm with some variability due to the presence of rugal folds. The distinction of the gastric wall layers is adequate and there is no impression of reduced peristaltic activity. No masses or focal lesions were observed.

The visualized areas of duodenum, jejunum and ileum have a relatively uniform diameter with minimal fluid distension. Wall thickness is normal. Bowel loops follow a curvilinear path with distinct wall layering maintaining the typical 1:3 muscularis:mucosa layer ratio. Jejunum wall measured 0.31 cm. Visualized peristalsis appears appropriate. There were no focal lesions consistent with obstruction or a mass effect observed.

The ileocecal junction was visualized and exhibited normal intact wall layering and is subjectively of normal thickness. Sections of colon are visualized with formed fecal material and gas shadowing distally. There is no observed focal or generalized colon wall thickening or loss of layering.

Pancreas

The pancreas is normal and isoechoic to surrounding mesentery. There is no evidence of nodules or cystic lesions. There is no evidence of regional mesenteric inflammation or fluid.

Free Abdomen

Evaluation of the peritoneal cavity did not reveal any evidence of effusion, or subjective lymphadenomegaly. The Medial iliac nodes appear normal and there was no evidence of a caudal aortic thrombus at the bifurcation. The omentum is of normal uniform echogenicity.

PRIMARY FINDINGS

- Hyperechoic nodule in the cranial pole of the left adrenal gland – Left adrenomegaly could be consistent with neoplasia (e.g., adenoma, carcinoma, pheochromocytoma), hyperplasia, inflammation, other.
- Large, mildly heterogeneous liver – The diffuse hepatic changes are non-specific and could be consistent with vacuolar hepatopathy, nodular hyperplasia, inflammatory/immune-mediated disease, fibrosis, extramedullary hematopoiesis, toxic hepatopathy (e.g., copper), infiltrative neoplasia (less likely) or other hepatopathy.
- Moderate gallbladder debris – The gastric distension and hypomotility could be consistent with focal ileus or a proximal duodenal obstruction.

SECONDARY FINDINGS

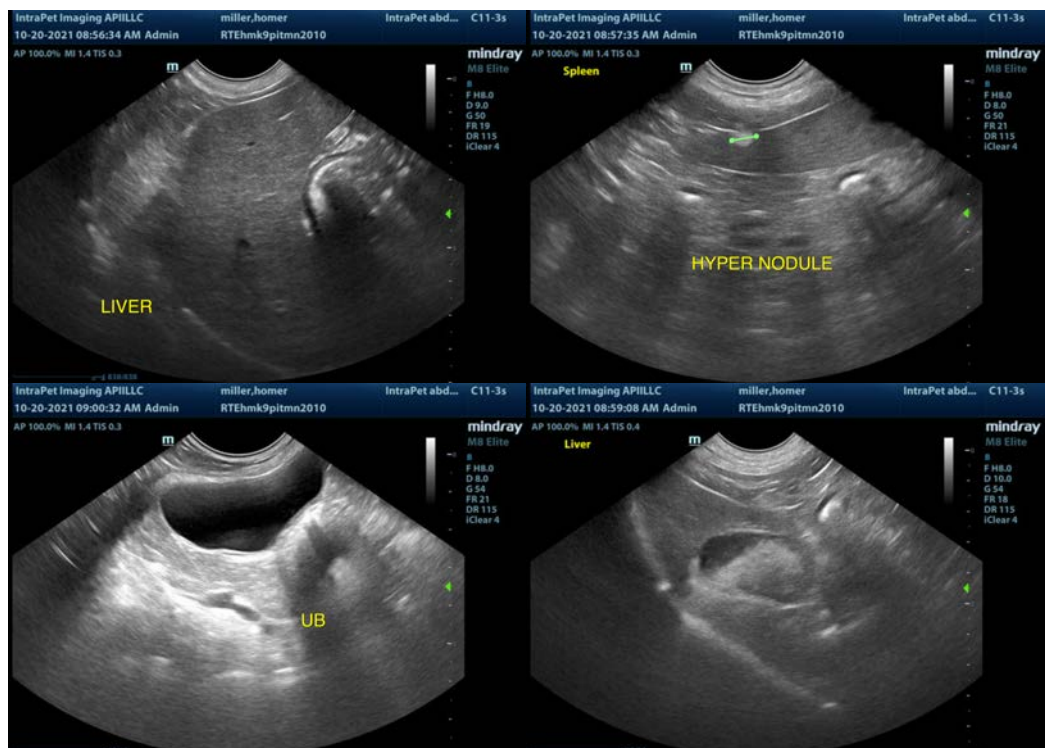
- Rare pinpoint non-obstructive nephroliths in both kidneys – The hyperechoic mineralized foci observed at the corticomedullary junction of the left/right kidney are consistent with small, non-obstructive nephroliths.

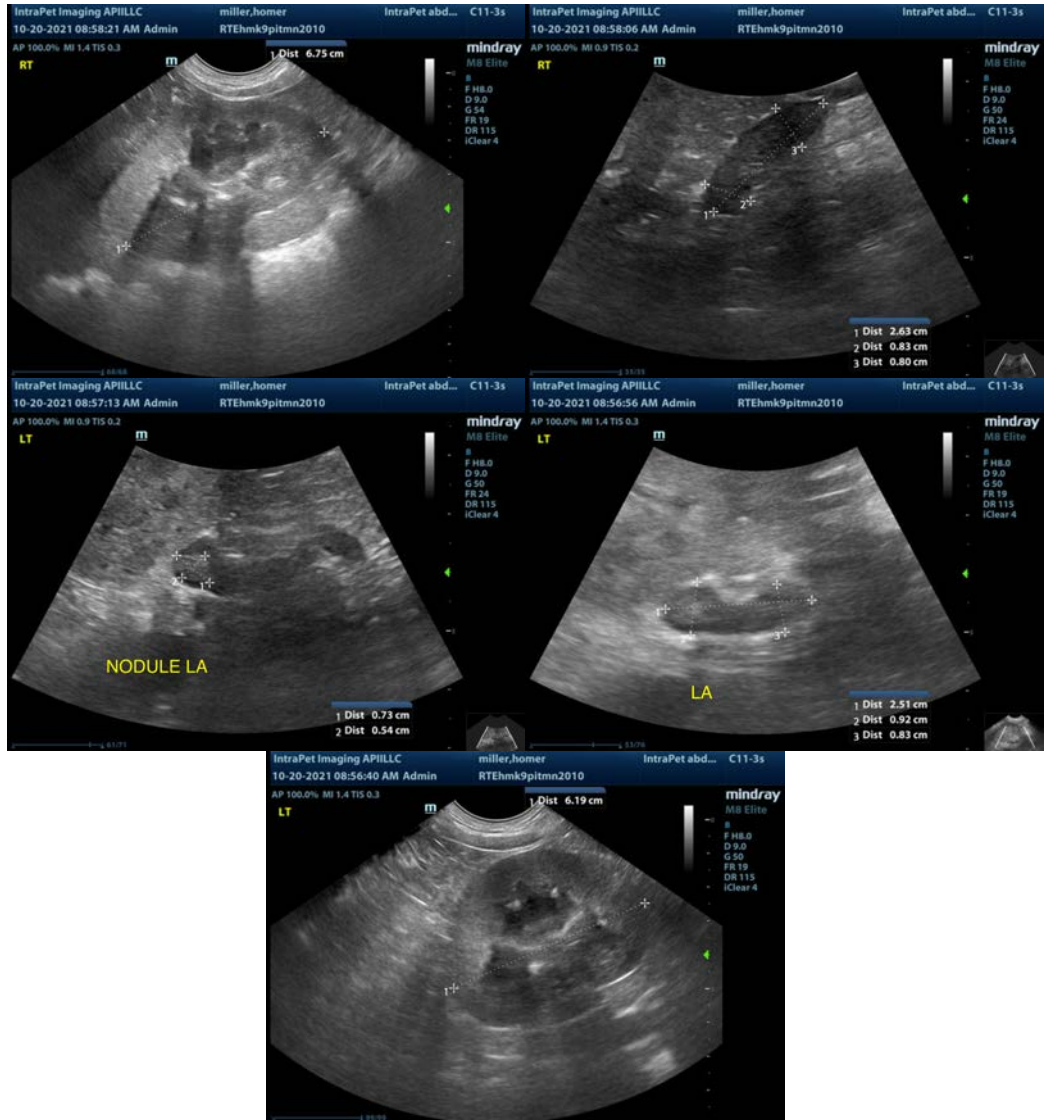
INTERPRETATION OF THE FINDINGS & FURTHER RECOMMENDATIONS

There is nodule present on the left adrenal gland. This nodule is relatively small and is not deforming the adrenal gland significantly and doesn't appear to have any evidence of vascular invasion. These nodules can be benign or malignant and can secrete hormones or be non-active. Options moving forward include:

- If signs of Cushing's are present, consider adrenal function testing. I prefer an ACTH stimulation test combined with an adrenal panel to the University of Tennessee's endocrine lab to look for atypical adrenal hormones as well as cortisol. (other testing can suffice)
- If adrenal dependent Cushing's is suspected and supported by adrenal function testing consider medical therapy with lisdexamfetamine or trilostane or consider surgical removal (recommend referral to a board certified veterinary surgeon and possible pre op CT)
- Recommend blood pressure evaluation-if hypertensive consider testing catecholamine levels for a possible pheochromocytoma
- If no symptoms of Cushing's are present, consider either referral for surgery or continued monitoring with ultrasound (in 3-4 months).
- Many of these nodules can be benign and incidental in nature, unfortunately that is difficult to determine with a single ultrasound.

The changes observed in the liver are mild and relatively non-specific. They could be consistent with Cushing's disease or a vacuolar hepatopathy. Consider fine needle aspirate if there is concern for possible lymphoma. I don't see an obvious lesion responsible for the symptoms provided. Correlate with metabolic testing and possible neurologic evaluation (?). Recommend blood pressure and 3-view thoracic radiographs.





The information and recommendations provided are based on the images presented by the referring veterinarian. No evaluation can be communicated regarding pathology that was not visible in the image/video clips provided.

Thank you for this referral. If the clinical or image interpretation does not parallel your findings or if I can be of any further assistance please contact me.

Kathleen Sennello DVM,MS, Diplomate ACVIM (Small animal Internal Medicine)
 kathleen.sennello@sonopath.com