

PATIENT

Sequoia Koppe

SPECIES

Canine

BREED

Lab Retriever

SEX

Neutered Male

AGE

4 Years

WEIGHT

61 Pounds

INTERPRETED BY

Kathleen Sennello DVM,
MS, Diplomate ACVIM
(Small Animal Internal
Medicine)

IMAGING PERFORMED BY

Loetitia Saint-Jacques, RVT

HOSPITAL NAME

Donner Truckee VH

REFERRING VET

Dr. Vannini

INVOICE

26043

DATE

10/2/21

PRESENTING CLINICAL SIGNS

Pertinent Case Information* Vomiting for 3 days. Owner noticed foreign material in the vomit with the first episode 3 nights ago. After further examination of the vomitus the next morning, the foreign material was actually determined to be bread and tomato. Seen by the regular vet 2 days ago and a bland diet was started. Seemed improved initially, but started vomiting again last night. He is eating grass and then vomiting. He did have some mild loose stools and tenesmus, but his stool is no normal. He did eat chicken and rice this morning and has since held it down. No C/S. Hx bilateral elbow dysplasia and had bilateral ostectomy with complete recovery. On Adequan. No other historical problems/current medications reported, except flea/tick/heartworm prevention. Up to date on vaccines per owner. PE: BAR, ~3-5% dehydrated, PK MM, CV/resp auscult WNL, GI/GU palpate possible intestinal FB vs feces in mid to caudal abdomen. Differential Diagnosis* . Findings: Abdominal radiographs (6 projections): - The stomach contains a small volume of gas and minimal heterogeneous soft tissue opaque material. Some segments of the small intestine located in the cranial abdomen appear bunched, best seen on the right lateral projection. The descending colon is moderately distended with heterogeneous soft tissue opaque feces. Within the cranial aspect of the descending colon, there are a few, round, mineral opaque foci, measuring up to 1 cm in diameter, best seen on the ventral dorsal projection. The transverse colon contains a moderate volume of heterogeneous soft tissue opaque feces and gas. - The liver and spleen are normal in size and margination. - The urinary bladder is normal. The kidneys cannot be completely evaluated due to the superimposition of the gastrointestinal tract. - The peritoneal and retroperitoneal serosal detail is normal. - The extra-abdominal structures are normal. - The included portions of the pelvis and coxal joints are normal. . Assessment: The appearance of the small intestine in the cranial abdomen on the right lateral projection may represent a linear foreign body or enteritis. Mild gastric undigested food, lucent foreign material, or fluid. For further evaluation, an abdominal ultrasound is recommended. The material within the colon may represent feces or foreign material secondary to the possibility of dietary indiscretion. 10/2/2021: passed rocks this morning and no vomiting since yesterday. Was hospitalized and on IVF all day yesterday

Abnormal PE/Chem/CBC/UA Results: RADS ATTACHED AS SUPPLEMENTAL READING- A SET FROM YESTERDAY (REPORT IN HISTORY) AND TODAY(NOT SUBMITTED)- sent in DICOM and JPEG

ULTRASONOGRAPHIC EXAMINATION OF THE ABDOMEN

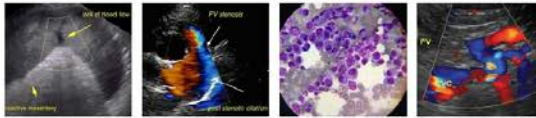
Urinary System

The urinary bladder is moderately distended with mild primarily suspended echogenic debris present. The Bladder wall, trigone, ureteral papillae and visible urethra (to a depth of 2cm) appear normal with no evidence of wall thickening, mucosal irregularities, masses or calculi. Echogenic debris of this type can be associated with small crystals, cellular debris and proteinaceous debris.

The visualized areas of prostate and surrounding tissue appear normal. Unfortunately, the prostate is not fully visualized likely due to its intrapelvic location. Correlate with rectal exam findings.

The left kidney has a normal shape and size (4.8 cm). Overall echogenicity is normal with adequate corticomedullary distinction and a typical 1:3 cortex:medulla ratio. There is no evidence of perinephric inflammation or effusion. There is no evidence of pyelectasia, nephroliths, infarcts or hydroureter. Renal vasculature is normal.

The right kidney has a normal shape and size (5.44 cm). Overall echogenicity is normal with adequate corticomedullary distinction and a typical 1:3 cortex:medulla ratio. There is no evidence of perinephric inflammation or effusion. There is no evidence of pyelectasia, nephroliths, infarcts or hydroureter. Renal vasculature is normal.



PATIENT

Sequoia Koppe

Adrenal Glands

The left adrenal gland is normal in size measuring 0.49 cm at the caudal pole. It is observed in its normal position cranial to the left renal artery. It is normal in appearance (uniformly hypoechoic) and shape with no evidence of a mass effect.

SPECIES

Canine

The right adrenal gland is normal in size measuring 0.39 cm at the caudal pole. It is observed in its normal position between the cranial aspect of the right kidney and the caudal vena cava. It is normal in appearance (uniformly hypoechoic) and shape with no evidence of a mass effect.

BREED

Lab Retriever

Spleen

The spleen is subjectively normal in size, echotexture is homogenous, and the splenic capsule is smooth with no irregularities. The blood flow through the hilus and splenic parenchyma appears normal. No focal parenchymal abnormalities are visualized.

SEX

Neutered Male

Liver

AGE

4 Years

The liver is subjectively normal in size, and echogenicity with smooth peripheral margins. The parenchyma is homogenous echotexture. The visible portions of the vasculature and biliary tract appear normal. No focal nodules or cystic lesions are observed.

WEIGHT

61 Pounds

The gallbladder lumen is moderately distended. The wall of the gall bladder is not thickened and has a smooth mucosal surface. Luminal contents are primarily anechoic. The cystic and common bile ducts are normal/not visible.

Gastrointestinal

INTERPRETED BY

Kathleen Sennello DVM,
MS, Diplomate ACVIM
(Small Animal Internal
Medicine)

The stomach is mildly dilated with fluid and irregular shadowing material, most consistent with fluid and gas +/- a small amount of ingesta. It measures at a normal thickness of <0.7cm with some variability due to the presence of rugal folds. The distinction of the gastric wall layers is adequate. Back and forth motion of fluid and ingesta is visualized with a lack of progressive motility, which could indicate some evidence of stasis. No masses or focal lesions observed.

IMAGING PERFORMED BY

Loetitia Saint-Jacques, RVT

Some of the visualized areas of duodenum, jejunum and ileum have a relatively uniform diameter with minimal fluid distension. Wall thickness is normal. The duodenum measures normal at 0.36 cm. The jejunum measures normal at 0.22 cm. The ileum is slightly fluid dilated with some evident stasis, measuring 0.32 cm. No focal lesions consistent with an obstruction or mass effect are observed, but there is evidence of fluid dilation and some stasis.

HOSPITAL NAME

Donner Truckee VH

The ileocecal junction was visualized and exhibited normal intact wall layering and is subjectively of normal thickness. Sections of colon are visualized with formed fecal material and gas shadowing distally. There is no observed focal or generalized colon wall thickening or loss of layering.

REFERRING VET

Dr. Vannini

Pancreas

The pancreas is normal and isoechoic to surrounding mesentery. There is no evidence of nodules or cystic lesions. There is no evidence of regional mesenteric inflammation or fluid.

INVOICE

26043

Free Abdomen

Scant anechoic free fluid is present. Mild mesenteric lymphadenopathy is noted at 0.5 cm. The Medial iliac nodes appear normal and there was no evidence of a caudal aortic thrombus at the bifurcation. The omentum is of normal uniform echogenicity.

DATE

10/2/21



PATIENT

Sequoia Koppe

SPECIES

Canine

BREED

Lab Retriever

SEX

Neutered Male

AGE

4 Years

WEIGHT

61 Pounds

ULTRASONOGRAPHIC FINDINGS

- Mildly fluid dilated stomach with evidence of fluid stasis. I cannot rule out the possibility of a gastric foreign material, but none is observed or appears to be causing an obvious obstruction.
- Occasional areas of fluid dilated bowel with some evident stasis. No focal lesions are observed. I suspect this finding is consistent with gastroenteritis, but partial obstruction or a linear object cannot be ruled out.
- Echogenic debris in the urinary bladder – The echogenic debris in the bladder lumen could be consistent with cells, crystals, and/or mucus.
- Mild mesenteric lymphadenopathy – The prominent abdominal lymph nodes are most consistent with reactive lymphadenitis or lymphoid hyperplasia. Neoplastic infiltration is considered less likely.

INTERPRETATION OF THE FINDINGS & FURTHER RECOMMENDATIONS

An obvious obstructive process is not observed, although there some areas of fluid dilation including the stomach and small intestine where there is a lack of progressive motility apparent. I feel a complete obstruction is fairly unlikely, but partial obstruction or linear object cannot be ruled out. If patient is improving with current clinical therapy, I would recommend continued therapy and close monitoring with serial radiographs and ultrasound. If there is a decline or lack of improvement, consider exploratory.

INTERPRETED BY

Kathleen Sennello DVM,
MS, Diplomate ACVIM
(Small Animal Internal
Medicine)

IMAGING PERFORMED BY

Loetitia Saint-Jacques, RVT

HOSPITAL NAME

Donner Truckee VH

REFERRING VET

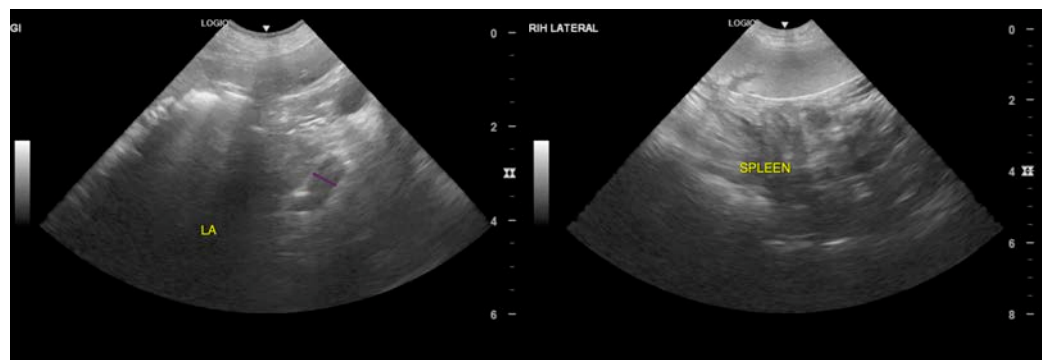
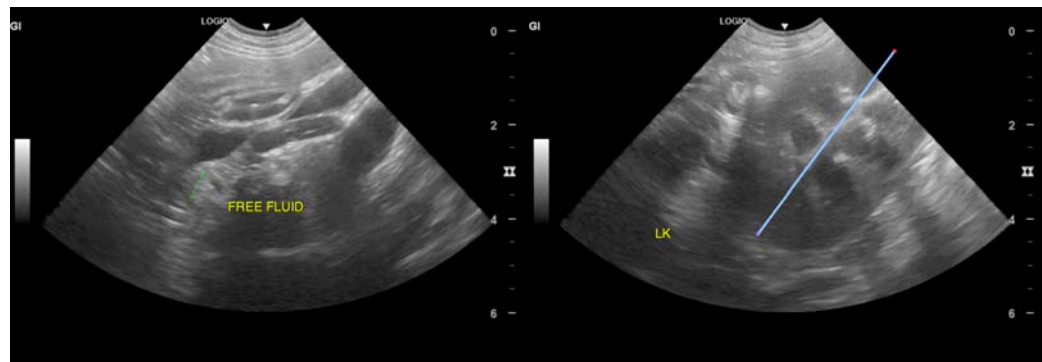
Dr. Vannini

INVOICE

26043

DATE

10/2/21





PATIENT

Sequoia Koppe

SPECIES

Canine

BREED

Lab Retriever

SEX

Neutered Male

AGE

4 Years

WEIGHT

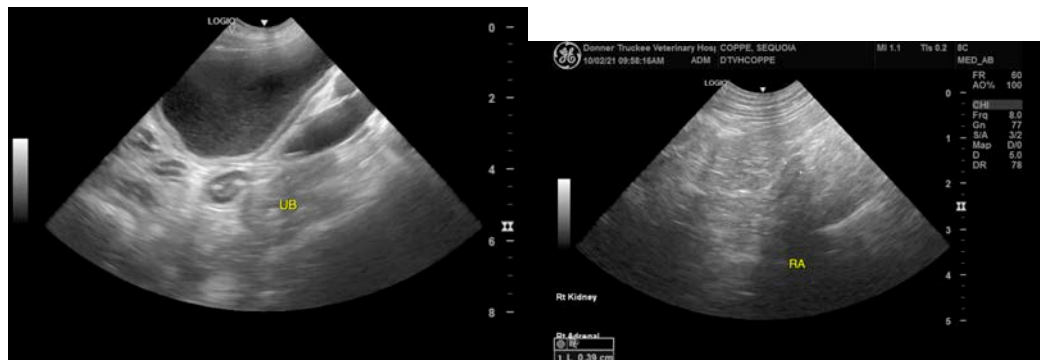
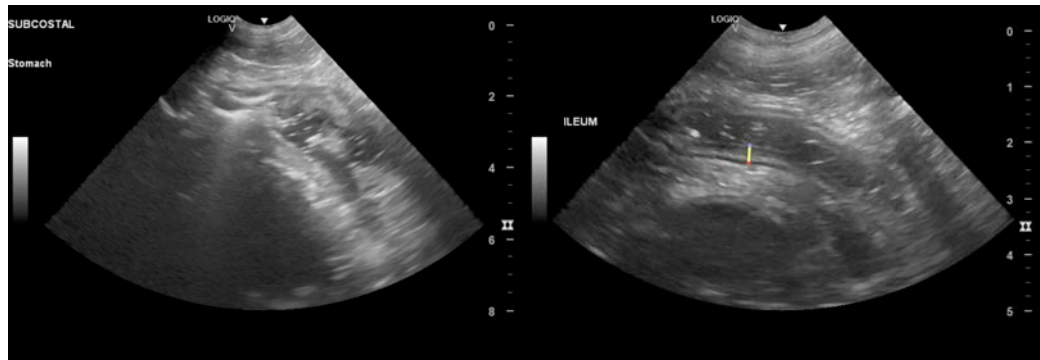
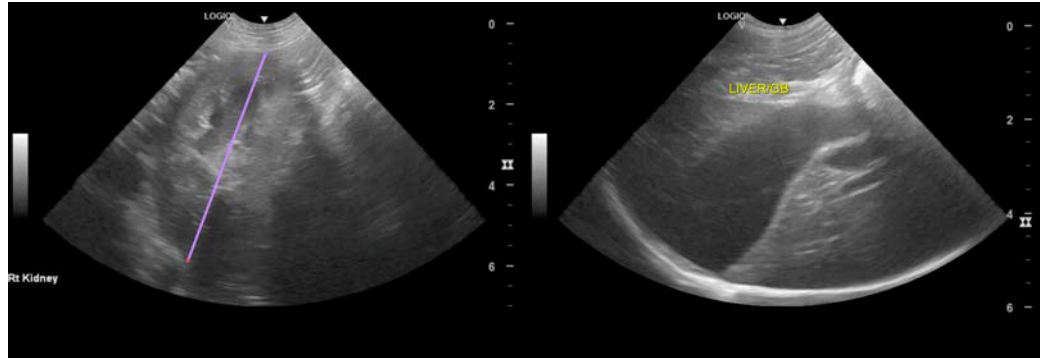
61 Pounds

INTERPRETED BY

Kathleen Sennello DVM,
MS, Diplomate ACVIM
(Small Animal Internal
Medicine)

IMAGING PERFORMED BY

Loetitia Saint-Jacques, RVT



HOSPITAL NAME

Donner Truckee VH

REFERRING VET

Dr. Vannini

The information and recommendations provided are based on the images presented by the referring veterinarian. No evaluation can be communicated regarding pathology that was not visible in the image/video clips provided.

Thank you for this referral. If the clinical or image interpretation does not parallel your findings or if I can be of any further assistance please contact me.

Kathleen Sennello DVM,MS, Diplomate ACVIM (Small animal Internal Medicine)

kathleen.sennello@sonopath.com

INVOICE

26043

DATE

10/2/21