

**DATE PRESENTING CLINICAL SIGNS**

10/19/22

Presented on 10/10/22 for being lethargic/not herself. Soft stool.
 BW normal--mild lymphocytosis and monocytosis. Normal fPL

PATIENT

Hx asthma--not treated currently. Rads taken 10/10 showed mild bronchial pattern, non-obstructive GIT.

Lomasi Wilkinson

Current Medications: Cerenia injection in hospital, Buprenex and proviable at home.
 Lab Results: Lymphs: 6.81k, Monos: 0.578 k.

SPECIES

Date of Previous IntraPet Ultrasound: No previous.

Feline

Sedation: Not required to complete full diagnostic ultrasound.
 Stat Report: Not requested.

BREED**ULTRASONOGRAPHIC EXAMINATION OF THE ABDOMEN**

DSH

Urinary System

The urinary bladder is moderately distended with anechoic urine. The Bladder wall, trigone, ureteral papillae and visible urethra (to a depth of 2cm) appear normal with no evidence of wall thickening, mucosal irregularities, masses or cystic calculi.

SEX

Spayed Female

The left kidney has a normal shape and size (3.48 cm) with very mild pyelectasia at 0.12 cm. Overall echogenicity is normal with adequate corticomedullary distinction and a typical 1:3 cortex:medulla ratio. There is no evidence of focal perinephric inflammation or effusion. There is no evidence of pyelectasia, nephroliths, infarcts or hydroureter. Renal vasculature is normal.

AGE

4/1/17

WEIGHT

10.8 Pounds

The right kidney has a normal shape and size (3.62 cm) with mild pyelectasia at 0.12 cm. Overall echogenicity is normal with adequate corticomedullary distinction and a typical 1:3 cortex:medulla ratio. There is no evidence of focal perinephric inflammation or effusion. There is no evidence of pyelectasia, nephroliths, infarcts or hydroureter. Renal vasculature is normal.

INTERPRETED BY

Kathleen Sennello DVM,
 MS, Diplomate ACVIM
 (Small Animal Internal
 Medicine)

Adrenal Glands

The left adrenal gland is normal in size measuring 0.49 cm at the caudal pole. It is observed in its normal position cranial to the left renal artery. It is normal in appearance (uniformly hypoechoic) and shape with no evidence of a mass effect.

IMAGING PERFORMED BY

Rachel Brilhart RDMS

The right adrenal gland is normal in size measuring 0.47 cm at the caudal pole. It is observed in its normal position between the cranial aspect of the right kidney and the caudal vena cava. It is normal in appearance (uniformly hypoechoic) and shape with no evidence of a mass effect.

HOSPITAL NAME

Paradise AH

Spleen

The spleen is subjectively normal in size (0.95 cm in width at the level of the hilus), echotexture is homogenous, and the splenic capsule is smooth with no irregularities. The blood flow through the hilus and splenic parenchyma appears normal. No focal parenchymal abnormalities are visualized.

REFERRING VET

Dr. Twardzik

Liver

The liver is subjectively normal in size, and echogenicity with smooth peripheral margins. The parenchyma is homogenous echotexture. The visible portions of the vasculature and biliary tract appear normal. No focal nodules or cystic lesions are observed.

INVOICE

42178

The gallbladder lumen is moderately distended. The wall of the gall bladder is not thickened and has a smooth mucosal surface. Luminal contents are mild and primarily anechoic. The cystic and common bile ducts are normal/not visible.

Gastrointestinal

The stomach contains minimal luminal contents. It measures at a normal thickness of <0.36cm with some variability due to the presence of rugal folds. The distinction of the gastric wall layers is adequate and there is no impression of reduced peristaltic activity. No masses or focal lesions were observed.

The visualized areas of duodenum, jejunum and ileum have a relatively uniform diameter with minimal fluid distension. Wall thickness is normal. Bowel loops follow a curvilinear path with distinct wall layering maintaining the typical 1:3 muscularis:mucosa layer ratio. Jejunum wall measures 0.21 cm. Visualized peristalsis appears appropriate. There were no focal lesions consistent with obstruction or a mass effect observed.

The ileocecal junction was visualized and exhibited normal intact wall layering and is subjectively of normal thickness. Sections of colon are visualized with formed fecal material and gas shadowing distally. There is no observed focal or generalized colon wall thickening or loss of layering.

Pancreas

The pancreas is prominent and mottled compared to the surrounding isoechoic mesentery. There is no evidence of nodules or cystic lesions. There is no evidence of regional mesenteric inflammation or fluid. Prominent pancreatic duct noted at 0.18 cm.

Free Abdomen

Evaluation of the peritoneal cavity did not reveal any evidence of effusion. There is a prominent lymph node visualized at the ileocecal junction measuring 0.43 cm. The omentum is of normal echogenicity.

ULTRASONOGRAPHIC FINDINGS

- Very mild pyelectasia in both kidneys – Pyelectasia of the kidney(s) could be consistent with pyelonephritis, chronic renal disease, secondary to PU/PD or fluid therapy (if applicable), other.
- Prominent, mottled pancreas – The pancreatic changes are most consistent with mild pancreatitis or a recent episode of pancreatic inflammation.
- Mildly enlarged lymph node at the ileocecal junction – The prominent abdominal lymph nodes are most consistent with reactive lymphadenitis or lymphoid hyperplasia. Neoplastic infiltration is considered less likely.

INTERPRETATION OF THE FINDINGS & FURTHER RECOMMENDATIONS

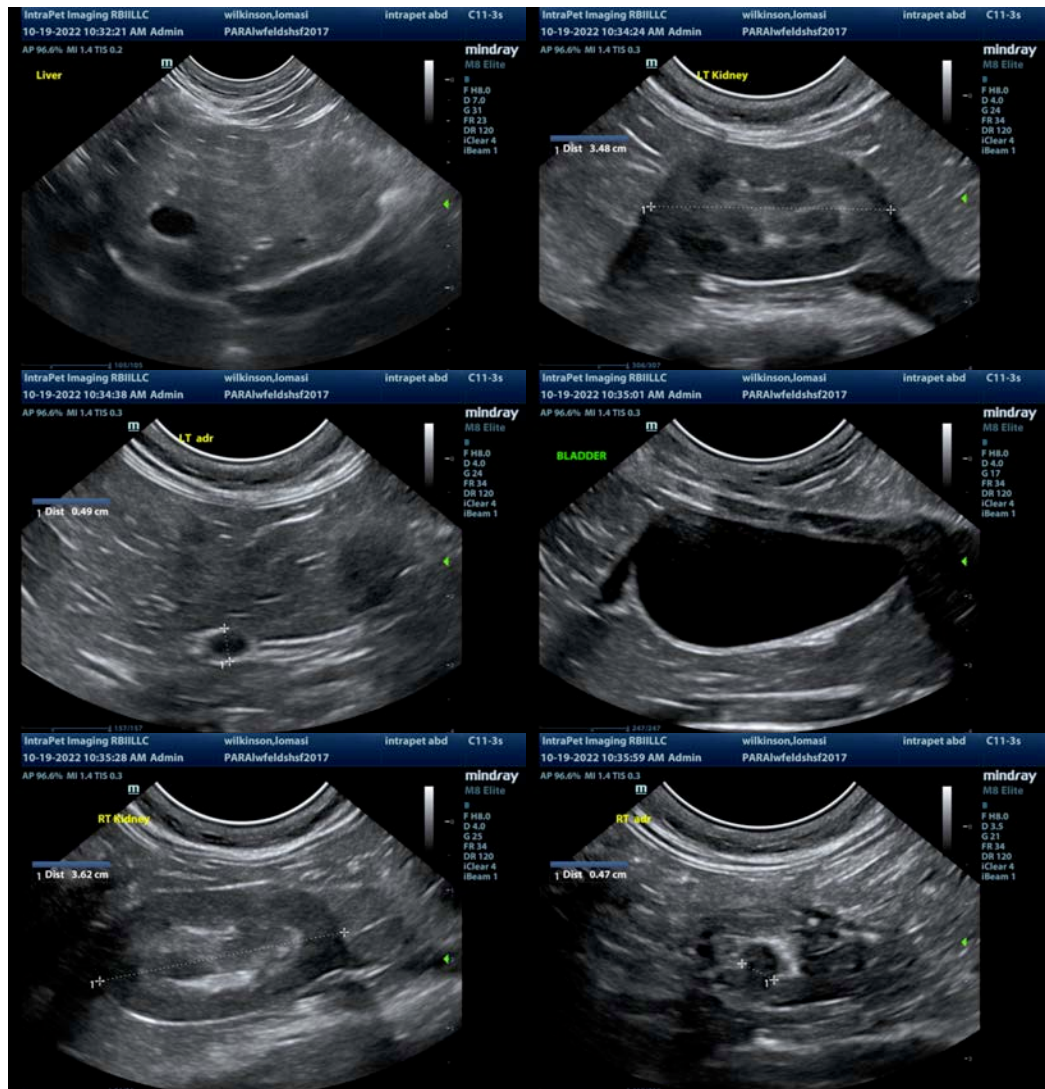
No focal lesions are visualized associated with the GI tract on today's scan. In some areas, the bowel appears somewhat "ropey", but all measurements are normal. Additionally, there is a prominent lymph node at the ileocecal junction. This is most likely a reactive lymph node, but continued monitoring is warranted if this patient is not improving.

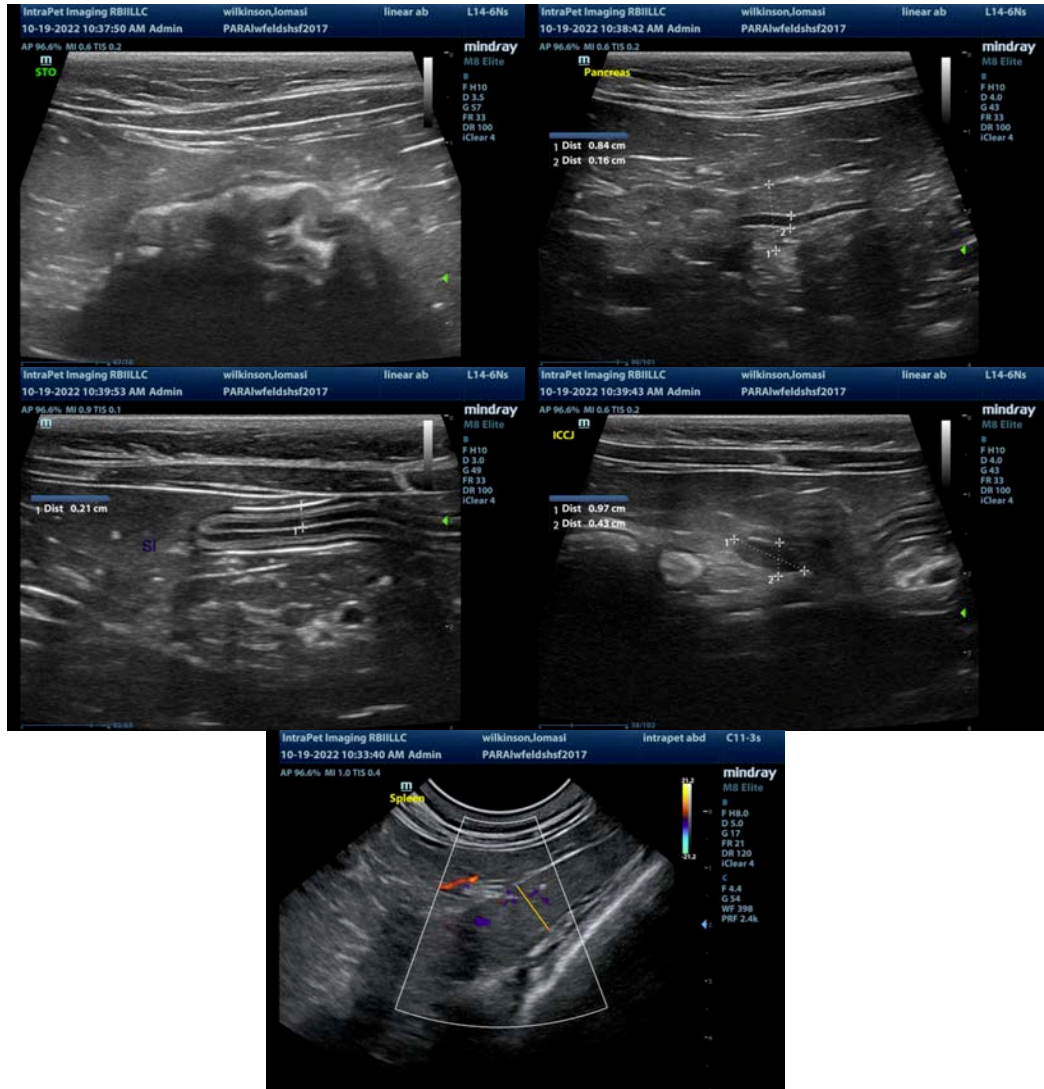
The pancreas is mildly prominent. There is no significant surrounding inflammation, so the significance is unclear. This could be consistent with mild current pancreatic inflammation or previous episodes of pancreatic inflammation.

There is very mild pyelectasia visualized in both kidneys. This is likely an incidental finding but consider a urinalysis and culture.

A definitive cause for the lethargy and soft stool is not observed. For now, consider symptomatic therapy:

- Consider a novel protein/hydrolyzed protein diet (exclusively at least 4-6 weeks)
- Consider a GI panel to Texas A&M for evaluation of B12 levels, folate, PLI/TLI etc.. to further evaluate for pancreatic/small intestinal disease.
- Recommend chronic probiotic therapy.
- If symptoms persist despite taking these measures or get worse, you could consider obtaining GI biopsies.
- Recommend empirical deworming (if not already done)





The information and recommendations provided are based on the images presented by the referring veterinarian/sonographer. No evaluation can be communicated regarding pathology that was not visible in the image/video clips provided.

Thank you for this referral. If the clinical or image interpretation does not parallel your findings or if I can be of any further assistance please contact me.

Kathleen Sennello DVM,MS, Diplomate ACVIM (Small animal Internal Medicine)
 kathleen.sennello@sonopath.com