**DATE PRESENTING CLINICAL SIGNS**

10/15/21 History: Testicular swelling.

PATIENT

Hermes Worthington

Current Medications: Augmentin 500/250 BID for 10 days.

Lab Results: Not provided by the veterinarian.

Radiographs: Not provided by the veterinarian.

Date of Previous IntraPet Ultrasound: No previous IntraPet scans.

Sedation: Telazol, Butorphanol, and Dexdomitor administered prior to scan.

Stat Report: STAT report not requested by the veterinarian.

SPECIES

Canine

BREED

German Shepherd

SEX

Intact Male

AGE

2/21/16

WEIGHT

92 Pounds

INTERPRETED BYKathleen Sennello DVM,
MS, Diplomate ACVIM
(Small Animal Internal
Medicine)**HOSPITAL NAME**

Northeast AH

REFERRING VET

Dr. Twardis

INVOICE

13783

ULTRASONOGRAPHIC EXAMINATION OF THE ABDOMEN**Urinary System**

The urinary bladder is moderately distended with anechoic urine. The Bladder wall, trigone, ureteral papillae and visible urethra (to a depth of 2.0 cm) appear normal with no evidence of wall thickening, mucosal irregularities, masses or cystic calculi.

The prostate is large and hyperechoic (4.29 cm) but has a regular shape with smooth external margins. The parenchyma is heterogenous, but no discrete focal lesions are present. The prostatic urethra appears normal with no evidence of irregularity, invasion, mass effect or calculi.

The left kidney has a normal shape and size (7.53 cm). Overall echogenicity is normal with adequate corticomedullary distinction and a typical 1:3 cortex:medulla ratio. There is no evidence of perinephric inflammation or effusion. There is no evidence of pyelectasia, infarcts or hydroureter. Renal vasculature is normal. Pinpoint non-obstructive shadowing nephroliths noted.

The right kidney has a normal shape and size (6.59 cm). Overall echogenicity is normal with adequate corticomedullary distinction and a typical 1:3 cortex:medulla ratio. There is no evidence of perinephric inflammation or effusion. There is no evidence of pyelectasia, infarcts or hydroureter. Renal vasculature is normal. Rare pinpoint non-obstructive shadowing nephroliths noted.

Adrenal Glands

The left adrenal gland is normal in size measuring 0.51 cm. It is observed in its normal position cranial to the left renal artery. It is normal in appearance (uniformly hypoechoic) and shape with no evidence of a mass effect.

The right adrenal gland is normal in size measuring 0.58 cm. It is observed in its normal position between the cranial aspect of the right kidney and the caudal vena cava. It is normal in appearance (uniformly hypoechoic) and shape with no evidence of a mass effect.

Spleen

The spleen is subjectively normal in size, echotexture is homogenous, and the splenic capsule is smooth with no irregularities. The blood flow through the hilus and splenic parenchyma appears normal. No focal parenchymal abnormalities are visualized.

Liver

The liver is subjectively normal in size, and echogenicity with smooth peripheral margins. The parenchyma is homogenous echotexture. The visible portions of the vasculature and biliary tract appear normal. No focal nodules or cystic lesions are observed. The gall bladder lumen is moderately distended. The wall of the gall

bladder is not thickened and has a smooth mucosal surface. Luminal contents are primarily anechoic. The cystic and common bile ducts are normal/not visible.

Gastrointestinal

The stomach contains minimal luminal contents. It measures at a normal thickness of <0.7cm with some variability due to the presence of rugal folds. The distinction of the gastric wall layers is adequate and there is no impression of reduced peristaltic activity. No masses or focal lesions were observed.

The visualized areas of duodenum, jejunum and ileum have a relatively uniform diameter with minimal fluid distension. Wall thickness is normal. Bowel loops follow a curvilinear path with distinct wall layering maintaining the typical 1:3 muscularis:mucosa layer ratio. The duodenum measured as normal (between 0.3-0.5 cm in wall thickness) and the jejunum measured as normal (between 0.2-0.47 cm.) Visualized peristalsis appears appropriate. There were no focal lesions consistent with obstruction or a mass effect observed.

The ileocecal junction was visualized and exhibited normal intact wall layering and is subjectively of normal thickness. Sections of colon are visualized with formed fecal material and gas shadowing distally. There is no observed focal or generalized colon wall thickening or loss of layering.

Pancreas

The (pancreas/region of the pancreas) is normal and isoechoic to surrounding mesentery. There is no evidence of nodules or cystic lesions. There is no evidence of regional mesenteric inflammation or fluid.

Free Abdomen

Evaluation of the peritoneal cavity did not reveal any evidence of effusion, or subjective lymphadenomegally. The Medial iliac nodes appear normal and there was no evidence of a caudal aortic thrombus at the bifurcation. The omentum is of normal uniform echogenicity.

Other

Both the left and right testicles are visualized, and no significant lesions are observed.

ULTRASONOGRAPHIC FINDINGS

Primary Findings

- Large hyperechoic prostate- Prostatic changes are most consistent with benign prostatic hyperplasia. Other differentials include bacterial prostatitis and prostatic neoplasia. However, given the lack of lower urinary tract symptoms, these differentials are considered less likely in this patient.

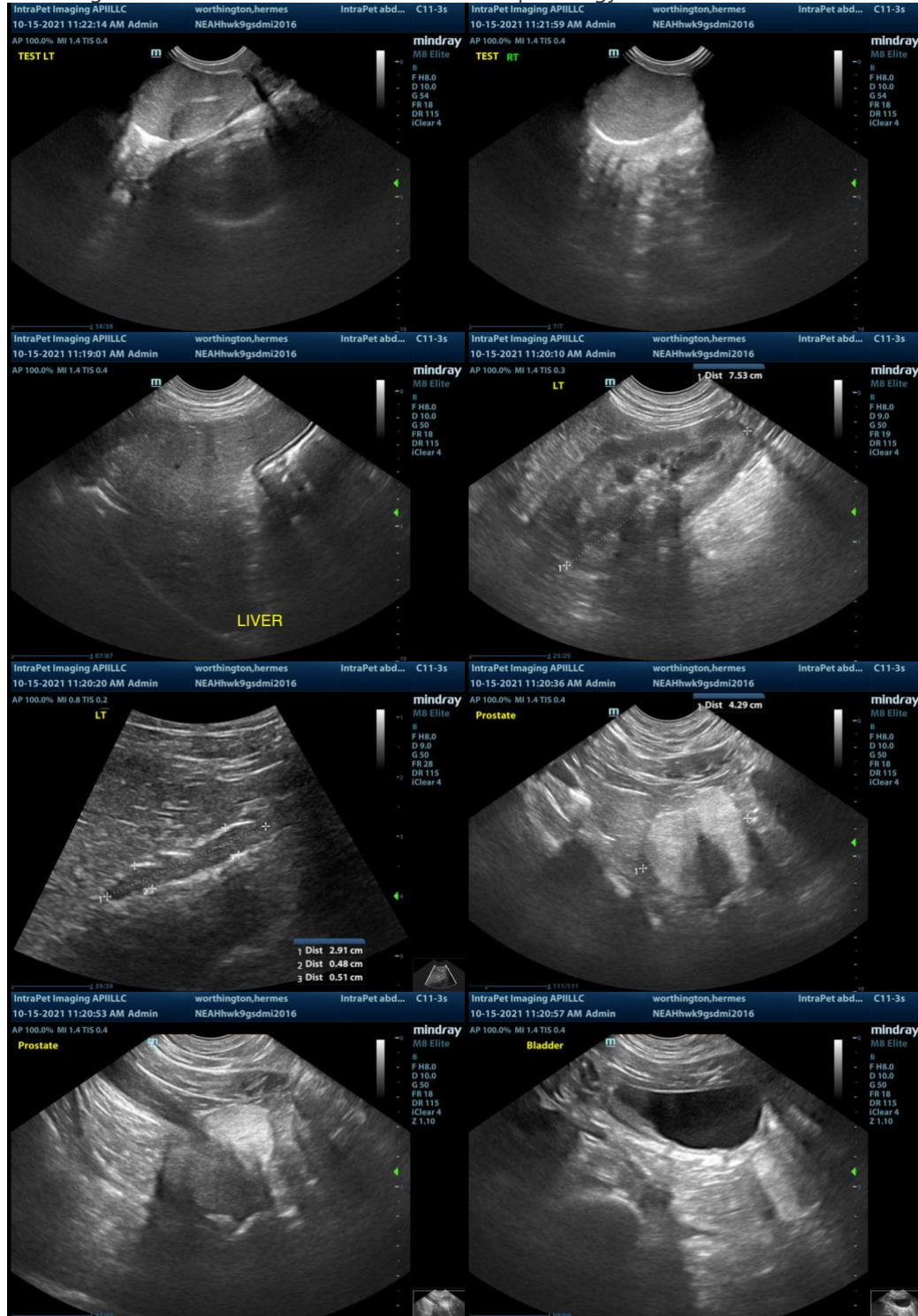
Secondary Findings

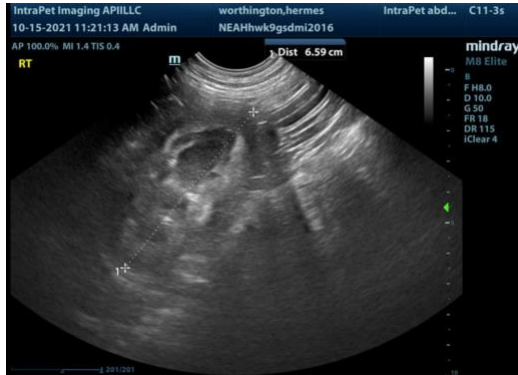- Pinpoint non-obstructive nephroliths in both kidneys- The hyperechoic mineralized foci observed at the corticomedullary junction of the left/right kidney are consistent with small, non-obstructive nephroliths.

INTERPRETATION OF THE FINDINGS & FURTHER RECOMMENDATIONS

The prostate is large and bright. No focal lesions are observed. These findings are most consistent with benign prostatic hypertrophy, although prostatitis cannot be ruled out. The history reports testicular

swelling. This was not noted on today's scan but may be difficult to determine by ultrasound alone. I recommend urinalysis and culture, brucella testing if concerned about scrotal swelling and recommend neutering with submission of both testicles for histopathology and culture.





The information and recommendations provided are based on the images presented by the referring veterinarian. No evaluation can be communicated regarding pathology that was not visible in the image/video clips provided.

Thank you for this referral. If the clinical or image interpretation does not parallel your findings or if I can be of any further assistance please contact me.

Kathleen Sennello DVM,MS, Diplomate ACVIM (Small animal Internal Medicine)
kathleen.sennello@sonopath.com