



PATIENT PRESENTING CLINICAL SIGNS

Mickey Morrison

vomiting, lethargy, soft opacity in caudal abd on rads, confirmed on abd palpation, difficulty urinating and defecating.

SPECIES

Abnormal PE/Chem/CBC/UA Results: Please see attached labs and rads

Feline

ULTRASONOGRAPHIC EXAMINATION OF THE ABDOMEN

BREED

Urinary System

DMH

The urinary bladder is moderately distended with mild primarily suspended echogenic debris present. The Bladder wall, trigone, ureteral papillae and visible urethra (to a depth of 2cm) appear normal with no evidence of wall thickening, mucosal irregularities, masses or calculi. Echogenic debris of this type can be associated with small crystals, cellular debris and proteinaceous debris.

SEX

Neutered Male

The left kidney has a normal shape and size (4.13 cm). Overall echogenicity is normal with adequate corticomedullary distinction and a typical 1:3 cortex:medulla ratio. There is no evidence of focal perinephric inflammation or effusion. There is no evidence of pyelectasia, nephroliths, infarcts or hydroureter. Renal vasculature is normal.

AGE

7 Years

The right kidney has a normal shape and size (4.25 cm). Overall echogenicity is normal with adequate corticomedullary distinction and a typical 1:3 cortex:medulla ratio. There is no evidence of focal perinephric inflammation or effusion. There is no evidence of pyelectasia, nephroliths, infarcts or hydroureter. Renal vasculature is normal.

WEIGHT

14.4 kg

Adrenal Glands

INTERPRETED BY

Kathleen Sennello DVM,
MS, Diplomate ACVIM
(Small Animal Internal
Medicine)

The left adrenal gland is normal in size measuring 0.28 cm at the caudal pole. It is observed in its normal position cranial to the left renal artery. It is normal in appearance (uniformly hypoechoic) and shape with no evidence of a mass effect.

The right adrenal gland is normal in size measuring 0.27 cm at the caudal pole. It is observed in its normal position between the cranial aspect of the right kidney and the caudal vena cava. It is normal in appearance (uniformly hypoechoic) and shape with no evidence of a mass effect.

IMAGING PERFORMED BY

Kelly Reschny

Spleen

HOSPITAL NAME

Dog & Cat Clinic of
Niagara

The spleen is subjectively normal in size (0.98 cm in width at the level of the hilus), echotexture is homogenous, and the splenic capsule is smooth with no irregularities. The blood flow through the hilus and splenic parenchyma appears normal. No focal parenchymal abnormalities are visualized.

Liver

REFERRING VET

Dr. Haidy

The liver is subjectively normal in size, and echogenicity with smooth peripheral margins. The parenchyma is homogenous echotexture. The visible portions of the vasculature and biliary tract appear normal. No focal nodules or cystic lesions are observed.

INVOICE

42069

The gallbladder lumen is moderately distended. The wall of the gall bladder is not thickened and has a smooth mucosal surface. Luminal contents are mild and primarily anechoic. The cystic and common bile ducts are normal/not visible.

DATE

10/13/22



PATIENT

Gastrointestinal

Mickey Morrison

The stomach contains minimal luminal contents. It measures at a normal thickness of <0.36cm with some variability due to the presence of rugal folds. The distinction of the gastric wall layers is adequate and there is no impression of reduced peristaltic activity. No masses or focal lesions were observed.

SPECIES

Feline

The visualized areas of duodenum, jejunum and ileum have a uniform diameter with minimal fluid distension. Wall thickness is normal to slightly increased. Bowel loops follow a typical curvilinear path with distinct wall layering, but some areas display a prominent muscularis layer which does not display the typical 1:3 muscularis:mucosa layer ratio. Jejunum wall measures 0.27 cm. Visualized peristalsis appears appropriate. There is a focal section of small intestine that appears prominent. There is still intact layering, but there is hyperechoic mesentery surrounding this loop of bowel and it is increased in thickness, measuring at 0.37 cm.

BREED

DMH

SEX

Neutered Male

The ileocecal junction was visualized and exhibited normal intact wall layering and is subjectively of normal thickness. Sections of colon are visualized with formed fecal material and gas shadowing distally. There is no observed focal or generalized colon wall thickening or loss of layering.

AGE

7 Years

Pancreas

The pancreas is normal and isoechoic to surrounding mesentery. There is no evidence of nodules or cystic lesions. There is no evidence of regional mesenteric inflammation or fluid.

WEIGHT

14.4 kg

Free Abdomen

Evaluation of the peritoneal cavity did not reveal any evidence of effusion. There is a large hypoechoic, irregular, solid mass effect visualized caudoventral to the urinary bladder, measuring 1.65 cm x 3.52 cm, most consistent with an intrapelvic mass/lymph node. The omentum is hyperechoic around the caudal abdominal mass and the thickened loop of bowel.

INTERPRETED BY

Kathleen Sennello DVM,
MS, Diplomate ACVIM
(Small Animal Internal
Medicine)

ULTRASONOGRAPHIC FINDINGS

- Echogenic debris in the urinary bladder – The echogenic debris in the bladder lumen could be consistent with cells, crystals, and/or mucus.
- Focal area of thickened small intestine with intact wall layering and a prominent muscularis layer – The bowel wall thickening could be consistent with inflammation, edema, or infiltrative neoplasia. A reduction in the detail of wall layering favors either severe intestinal disease or neoplastic infiltration. Biopsy is recommended.
- Large caudal abdominal/intrapelvic mass effect/lymph node – The appearance of this lesion is most consistent with a lymph node. Recommend a fine needle aspirate and a rectal exam.

IMAGING PERFORMED BY

Kelly Reschny

HOSPITAL NAME

Dog & Cat Clinic of
Niagara

INTERPRETATION OF THE FINDINGS & FURTHER RECOMMENDATIONS

REFERRING VET

Dr. Haidy

There is a large hypoechoic mass effect visualized caudoventral to the urinary bladder, which appears to be somewhat intrapelvic in location. It is surrounded by hyperechoic mesentery. This has an appearance most consistent with a lymph node. Recommend a fine needle aspirate of this lesion and rectal palpation to try to determine if it is intimately associated with the colon at all.

INVOICE

42069

Additionally, there is a focal section of small intestine that appears somewhat thickened with diminished detail of wall layering, but wall layering is intact and the muscularis layer is more pronounced. This could be a focal area of enteritis, IBD, or could be an early neoplastic lesion. If a diagnosis cannot be obtained based on a fine needle aspirate of this mass lesion, you could consider a contrast CT scan of the abdomen, or surgery to try to obtain biopsies.

DATE

10/13/22



PATIENT

Mickey Morrison

Recommend three view thoracic radiographs to evaluate for possible concurrent thoracic disease/involvement.

Recommend a stool softener for palliative care (Miralax).

SPECIES

Feline

BREED

DMH

SEX

Neutered Male

AGE

7 Years

WEIGHT

14.4 kg

INTERPRETED BY

Kathleen Sennello DVM,
MS, Diplomate ACVIM
(Small Animal Internal
Medicine)

**IMAGING
PERFORMED BY**

Kelly Reschny

HOSPITAL NAME

Dog & Cat Clinic of
Niagara

REFERRING VET

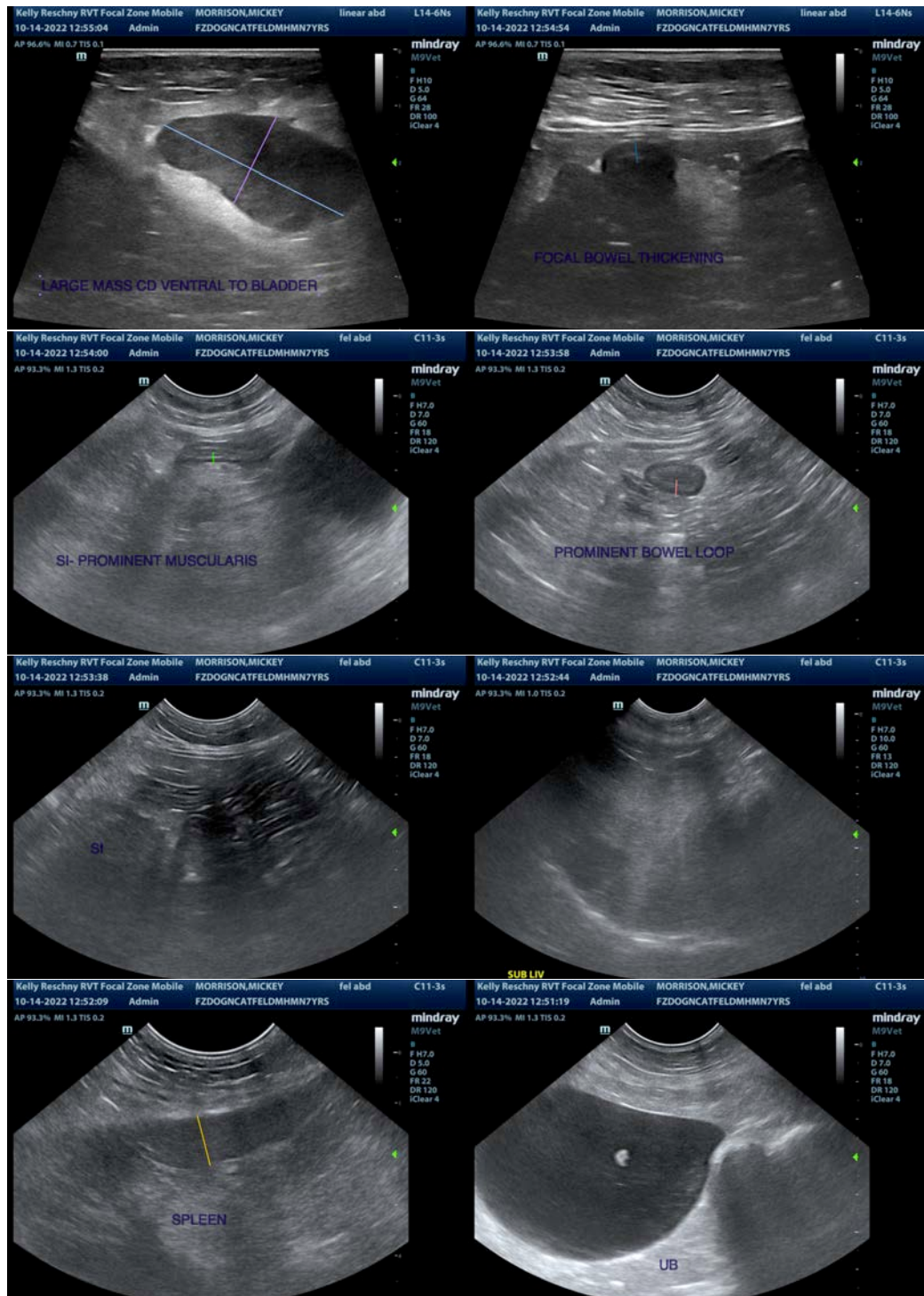
Dr. Haidy

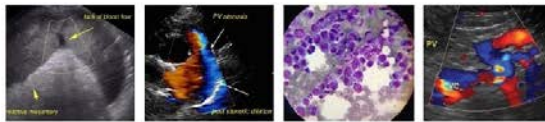
INVOICE

42069

DATE

10/13/22





PATIENT

Mickey Morrison

SPECIES

Feline

BREED

DMH

SEX

Neutered Male

AGE

7 Years

WEIGHT

14.4 kg

INTERPRETED BY

Kathleen Sennello DVM,
MS, Diplomate ACVIM
(Small Animal Internal
Medicine)

**IMAGING
PERFORMED BY**

Kelly Reschny

HOSPITAL NAME

Dog & Cat Clinic of
Niagara

REFERRING VET

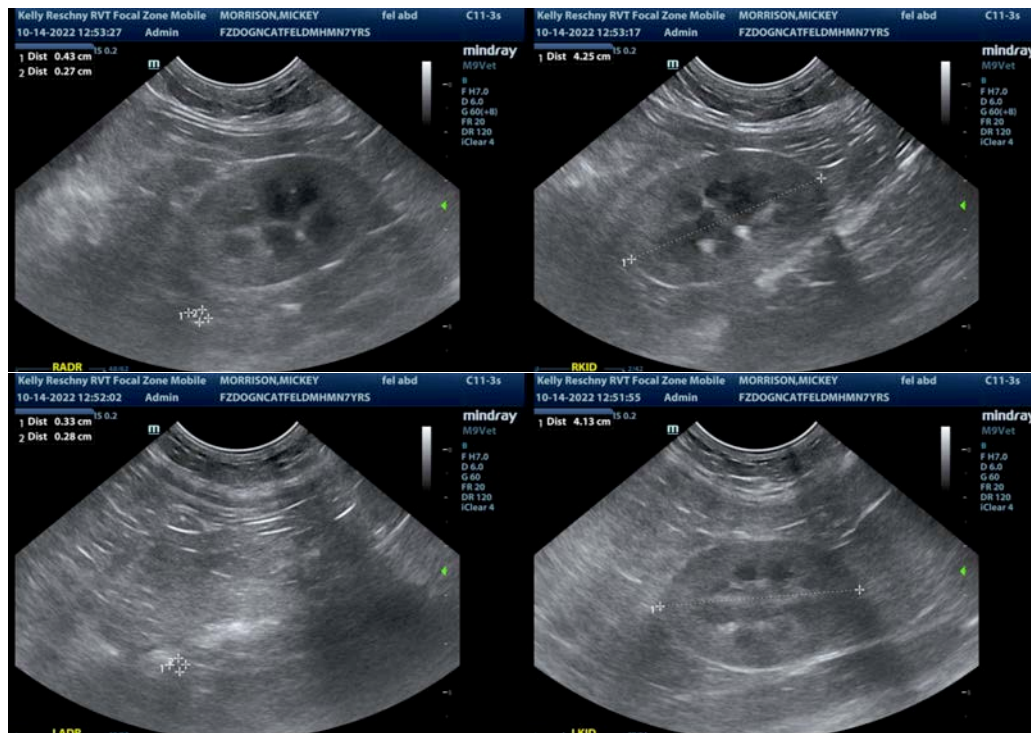
Dr. Haidy

INVOICE

42069

DATE

10/13/22



The information and recommendations provided are based on the images presented by the referring veterinarian/sonographer. No evaluation can be communicated regarding pathology that was not visible in the image/video clips provided.

Thank you for this referral. If the clinical or image interpretation does not parallel your findings or if I can be of any further assistance please contact me.

Kathleen Sennello DVM,MS, Diplomate ACVIM (Small animal Internal Medicine)

kathleen.sennello@sonopath.com