

**DATE PRESENTING CLINICAL SIGNS**

10/14/22

v/d, not eating or drinking ATO in room: - blood in urine last week, only lasted for 2 days - vomited twice yesterday - soft stool - wont go to sleep just lays with head up - looks like hes in pain - lethargic today, wouldn't let O's walk him - not interested in food this am Medical HX: - UTI- saw RDVM last week and urinalysis was NSF besides slightly elevated protein - itchy skin Meds: - hills urinary diet CD? - apoquel (began a week ago)

PATIENTMichael Jackson
Livingston**SPECIES**

Canine

Current Medications: Clavamox, Omeprazole, Gabapentin, Cerenia.

Radiographs: Gas dilated stomach and colon. Mild gassy changes to intestines. Suspicious area in intestines vs colon: material vs feces. Mild patchy changes to the lungs. Multifocal area of spondylosis at the thoracolumbar spine. Disc space narrowing T11-T12 and T12-T13. Repeat X-ray: Stomach empty. Gassy changes improved.

BREED

Pomeranian

Date of Previous IntraPet Ultrasound: No previous.

Sedation: Not required to complete full diagnostic ultrasound.

Stat Report: Not requested.

SEX

Intact Male

ULTRASONOGRAPHIC EXAMINATION OF THE ABDOMEN**AGE**

10/12/11

Urinary System

The urinary bladder is moderately distended with anechoic urine. The Bladder wall, trigone, ureteral papillae and visible urethra (to a depth of 2cm) appear normal with no evidence of wall thickening, mucosal irregularities, or masses. In the dependent portion of the urinary bladder including the trigone and proximal urethra, there are numerous hyperechoic shadowing small stones. I suspect some of these are clumped. One structure measures 0.60 cm. The small stones extend into the urethra and the prostatic urethra.

WEIGHT

19.4 Pounds

The prostate is large in size (2.48 cm in height in the sagittal view) but has a regular shape with smooth external margins. The parenchyma is heterogenous but no discrete focal lesions are present. The prostatic urethra appears normal with no evidence of irregularity, invasion, or masses. There are numerous small hyperechoic shadowing structures within the prostatic urethra, most consistent with sandy debris/small stones.

INTERPRETED BYKathleen Sennello DVM,
MS, Diplomate ACVIM
(Small Animal Internal
Medicine)

The left kidney has a normal shape and size (4.97 cm) with numerous no-obstructive nephroliths. One nephrolith measures 0.32 cm. Overall echogenicity is slightly hyperechoic with poor corticomedullary distinction and a typical 1:3 cortex:medulla ratio. There is no evidence of focal perinephric inflammation or effusion. There is no evidence of pyelectasia, infarcts or hydroureter. Renal vasculature is normal.

IMAGING PERFORMED BY

Rachel Brillhart RDMS

HOSPITAL NAMEAnimal Emergency
Hospital

The right kidney has a normal shape and size (4.42 cm) with numerous non-obstructive nephroliths, one of which measures 0.74 cm. There is mild pyelectasia at 0.20 cm. Overall echogenicity is slightly hyperechoic with poor corticomedullary distinction and a typical 1:3 cortex:medulla ratio. There is no evidence of focal perinephric inflammation or effusion. There is no evidence of infarcts or hydroureter. Renal vasculature is normal.

REFERRING VET

Dr. Nacke-Horney

Adrenal Glands

The left adrenal gland is normal in size measuring 0.77 cm at the cranial pole, 1.25 cm at the caudal pole, and 2.37 cm in length. It is observed in its normal position cranial to the left renal artery. It is abnormal in appearance in that the caudal pole is enlarged. There is no evidence of vascular invasion visualized. Findings are most consistent with a caudal adrenal nodule.

INVOICE

42113

The right adrenal gland is normal in size measuring 0.54 cm at the caudal pole. It is observed in its normal position between the cranial aspect of the right kidney and the caudal vena cava. It is normal in appearance (uniformly hypoechoic) and shape with no evidence of a mass effect.

Spleen

The spleen is subjectively normal in size, echotexture is homogenous, and the splenic capsule is smooth with no irregularities. The blood flow through the hilus and splenic parenchyma appears normal. No focal parenchymal abnormalities are visualized.

Liver

The liver is large in size, and normal in echogenicity with smooth peripheral margins. The parenchyma is heterogenous in echotexture with subtle, indistinct focal mottling. The visible portions of the vasculature and biliary tract appear normal. No focal nodules or cystic lesions are observed.

The gall bladder lumen is significantly distended. Some areas of the wall appear mildly thickened with adherent debris. There is a large amount of primarily non-organized echogenic debris. There is no evidence of bile duct dilation.

Gastrointestinal

The stomach contains minimal luminal contents. It measures at a normal thickness of <0.7cm with some variability due to the presence of rugal folds. The distinction of the gastric wall layers is adequate and there is no impression of reduced peristaltic activity. No masses or focal lesions were observed.

The visualized areas of duodenum, jejunum and ileum have a relatively uniform diameter with minimal fluid distension. Wall thickness is normal. Bowel loops follow a curvilinear path with distinct wall layering maintaining the typical 1:3 muscularis:mucosa layer ratio. Duodenum wall measures 0.47 cm. Jejunum wall measures 0.36 cm. Visualized peristalsis appears appropriate. There were no focal lesions consistent with obstruction or a mass effect observed.

The ileocecal junction was visualized and exhibited normal intact wall layering and is subjectively of normal thickness. Sections of colon are visualized with formed fecal material and gas shadowing distally. There is no observed focal or generalized colon wall thickening or loss of layering.

Pancreas

The pancreas is normal and isoechoic to surrounding mesentery. There is no evidence of nodules or cystic lesions. There is no evidence of regional mesenteric inflammation or fluid.

Free Abdomen

There is scant free abdominal fluid. There is no lymphadenopathy noted. The omentum is mildly hyperechoic within the region of the pelvis.

Other

Both testicles are evaluated. The left testicle appears to be visualized within the inguinal region (undescended testicle) and appears somewhat small and hypoechoic, measuring 1.57 cm x 2.06 cm. The right testicle is located within the scrotum. It is large, measuring 3.8 cm x 2.3 cm with a large mixed echogenic nodule/mass effect measuring 1.98 cm x 3.0 cm.

Ringdown artifact is visualized at the level of the diaphragm. This can be seen with pulmonary parenchymal disease. Recommend 3-view thoracic radiographs.

There is a hypoechoic, somewhat tubular appearing structure visualized in the intrapelvic region where a uterus would typically be visualized. There is some hyperechoic tissue surrounding this lesion. Consider the possibility of a uterus or some other atypical structure.

ULTRASONOGRAPHIC FINDINGS

- Numerous bladder stones extending into the urethra and prostatic urethra – Correlate with abdominal radiographs. Recommend urinalysis and culture.
- Large, heterogeneous prostate – Most consistent with benign prostatic hypertrophy +/- prostatitis.
- Enlarged caudal pole of the left adrenal gland – Left adrenomegaly could be consistent with neoplasia (e.g., adenoma, carcinoma, pheochromocytoma), hyperplasia, inflammation, other.
- Decreased corticomedullary distinction in both kidneys with non-obstructive nephroliths and mild right-sided pyelectasia – Most consistent with age related renal changes and stones. No obstruction is visualized.
- Large, heterogeneous liver – The diffuse hepatic changes are non-specific and could be consistent with vacuolar hepatopathy, nodular hyperplasia, inflammatory/immune-mediated disease, fibrosis, extramedullary hematopoiesis, toxic hepatopathy (e.g., copper), infiltrative neoplasia (less likely) or other hepatopathy.
- Large gallbladder debris – A large amount of debris is evident in the gall bladder with no evidence of a mucocele or associated inflammation at this time. This could represent an early mucocele or cholestasis, with minimal evidence of associated inflammation at this time. Continued monitoring of labwork and ultrasound are warranted for progression of this lesion. Ursodiol therapy could be considered.
- Small inguinal left testicle – This is consistent with a cryptorchid testicle.
- Mixed echogenic mass effect in the right testicle – There is a nodule visualized in the testicle. Consider such differentials as benign or neoplastic lesions such as Leydig cell tumor, Sertoli cell tumor, seminoma, granuloma, etc. Recommend neuter with histopathology (as treatment of choice), or cytology.
- Scant free abdominal fluid
- Hypoechoic tubular structure visualized within the pelvic region – This could be consistent with a uterus, possibly intersex/hermaphrodite.

INTERPRETATION OF THE FINDINGS & FURTHER RECOMMENDATIONS

There are many lesions described on today's scan. Many of these lesions likely represent longstanding conditions and are unlikely to cause the acute signs reported.

The stones visualized in the urinary bladder, urethra, and prostatic urethra could be causing pain and discomfort. Recommend a urine culture. The urinary bladder is not large, so an active obstruction is not suspected. Recommend radiographs to look for distal urethral calculi, etc. possibly with the ability to flush the calculi back into the urinary bladder. If calculi can be seen on radiographs, there would be the possibility of surgical removal, but I am not definitively sure if this is causing the symptoms described.

There is a mass effect in the left adrenal gland. I suspect this is an incidental finding at this time. It could be benign or malignant and could be secreting hormone or be non-active. If this pet is feeling better and you want to pursue additional diagnostics in the future, these would be my recommendations:

- If signs of cushings are present, consider adrenal function testing. I prefer an ACTH stimulation test combined with an adrenal panel to the University of Tennessee's endocrine lab to look for atypical adrenal hormones as well as cortisol. (other testing can suffice)
- If adrenal dependent cushings is suspected and supported by adrenal function testing consider medical therapy with lysodren or trilostane or consider surgical removal (recommend referral to a board certified veterinary surgeon and possible pre op CT)
- Recommend blood pressure evaluation-if hypertensive consider testing catecholamine levels for a possible pheochromocytoma
- If no symptoms of cushings are present, consider either referral for surgery or continued monitoring with ultrasound (in 3-4 months).
- Many of these nodules can be benign and incidental in nature, unfortunately that is difficult to determine with a single ultrasound.

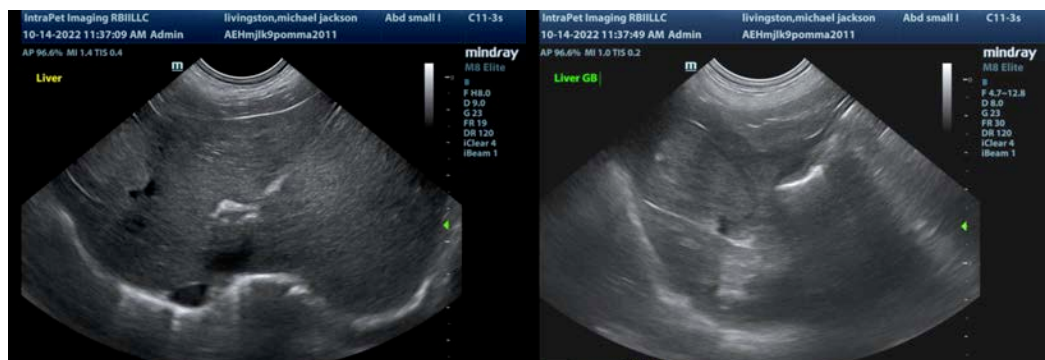
The changes observed with the kidneys likely represent chronic progressive age related disease. Consider a blood pressure, urinalysis and culture. The gallbladder has a large amount of debris, but no surrounding inflammation. Consider continued monitoring and Ursodiol therapy.

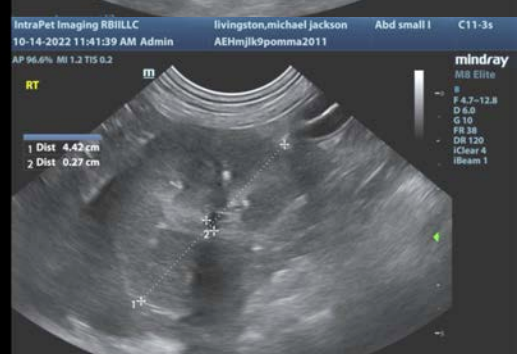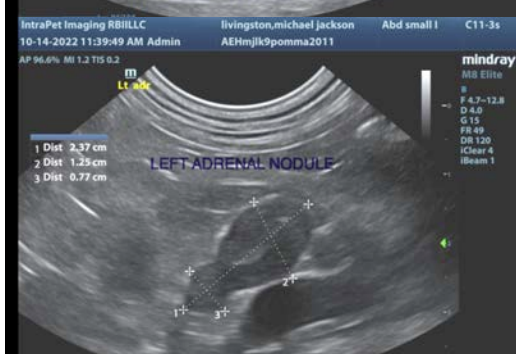
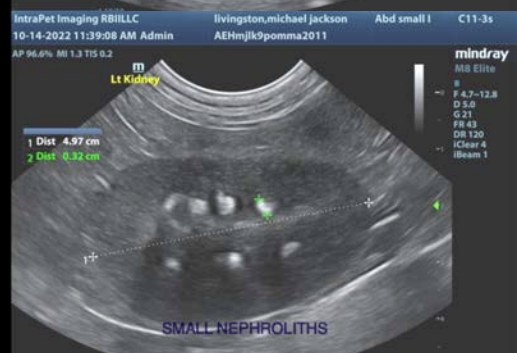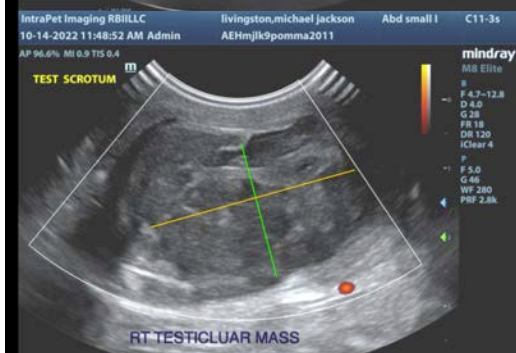
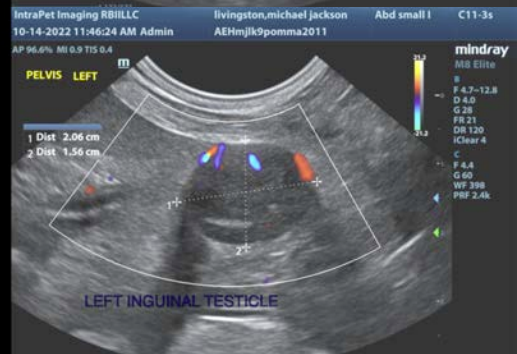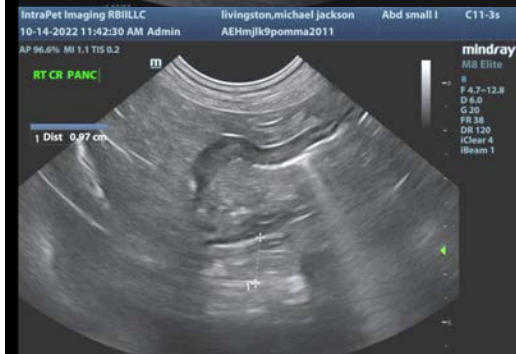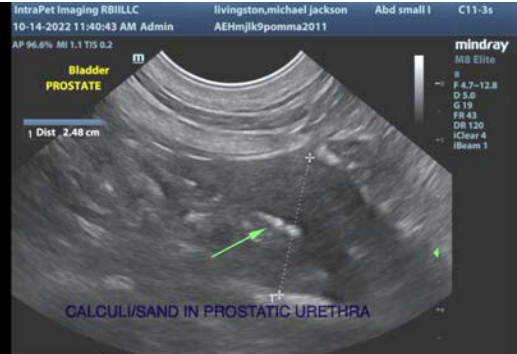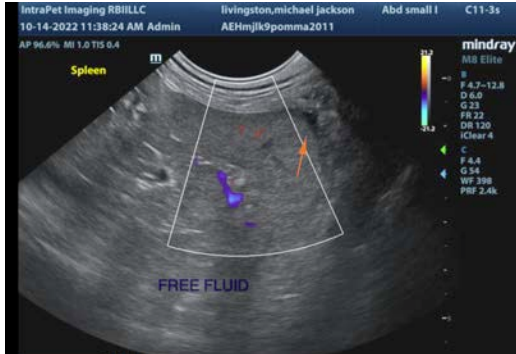
The left testicle is undescended. The right descended testicle appears to have a mass lesion. Neutering is recommended with histopathology. This also has the potential to help the enlarged prostate.

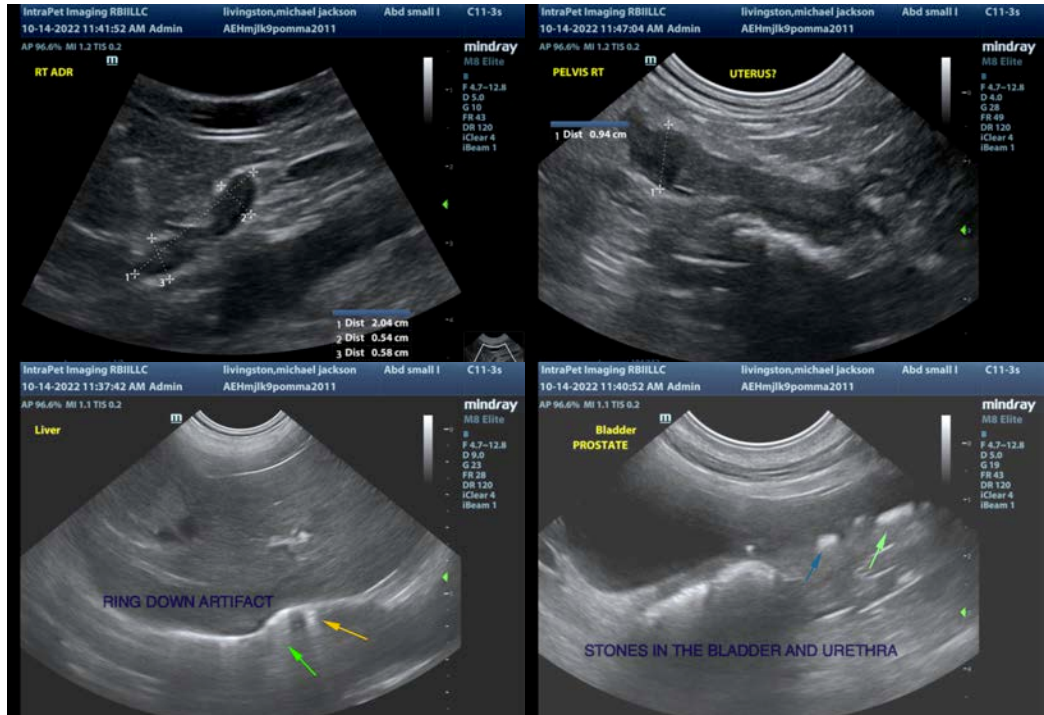
There is a tubular, possibly inflamed structure visualized within the pelvis. The identity of this structure is 100% clear. This would be the typical location of a uterus, so consider the possibility of an intersex/hermaphrodite patient. To further evaluate, you could consider a CT scan of the pelvis or evaluation of this region if a cystotomy is performed.

As stated earlier, it is unclear if these lesions are causing the current symptoms described. Additionally, consider the possibility of neck or back pain. Correlate these findings with clinical information and physical exam to try to make a treatment plan.

Recommend three view thoracic radiographs to evaluate for possible concurrent thoracic disease/involvement.







The information and recommendations provided are based on the images presented by the referring veterinarian/sonographer. No evaluation can be communicated regarding pathology that was not visible in the image/video clips provided.

Thank you for this referral. If the clinical or image interpretation does not parallel your findings or if I can be of any further assistance please contact me.

Kathleen Sennello DVM,MS, Diplomate ACVIM (Small animal Internal Medicine)
 kathleen.sennello@sonopath.com