

**DATE PRESENTING CLINICAL SIGNS**

10/14/22

Dx with ITP yesterday owner declined coags, US, and inpt returned b/c bleeding from nose today. Reviewed ITP-- discussed again life threatening, can bleed into brain/heart/lungs other. Discussed need time for meds to work, but despite meds some never respond. Discussed we often hospitalize to monitor hct/ts, if drops, consider transfusion to buy time.

PATIENT

Leah Huffer

SPECIES

Canine

Current Medications: Cerenia, Melatonin, Doxycycline, Prednisone, Famotidine, Mycophenolate.

Lab Results: See attached.

Date of Previous IntraPet Ultrasound: No previous.

Sedation: Not required to complete full diagnostic ultrasound.

Stat Report: Not requested.

BREED

Shih Tzu X

ULTRASONOGRAPHIC EXAMINATION OF THE ABDOMEN**SEX**

Spayed Female

Urinary System

The urinary bladder is moderately distended with anechoic urine. The Bladder wall, trigone, ureteral papillae and visible urethra (to a depth of 2cm) appear normal with no evidence of wall thickening, mucosal irregularities, masses or cystic calculi.

AGE

6/23/18

The left kidney has a normal shape and size (4.77 cm). Overall echogenicity is normal with adequate corticomedullary distinction and a typical 1:3 cortex:medulla ratio. There is no evidence of focal perinephric inflammation or effusion. There is no evidence of pyelectasia, nephroliths, infarcts or hydroureter. Renal vasculature is normal.

WEIGHT

26.1 Pounds

The right kidney has a normal shape and size (4.97 cm) with mild pyelectasia at 0.24 cm. Overall echogenicity is normal with adequate corticomedullary distinction and a typical 1:3 cortex:medulla ratio. There is no evidence of focal perinephric inflammation or effusion. There is no evidence of nephroliths, infarcts or hydroureter. Renal vasculature is normal.

INTERPRETED BY

Kathleen Sennello DVM,
MS, Diplomate ACVIM
(Small Animal Internal
Medicine)

Adrenal Glands

The left adrenal gland is normal in size measuring 0.52 cm at the caudal pole. It is observed in its normal position cranial to the left renal artery. It is normal in appearance (uniformly hypoechoic) and shape with no evidence of a mass effect.

IMAGING PERFORMED BY

Rachel Brilhart RDMS

The right adrenal gland is normal in size measuring 0.54 cm at the caudal pole. It is observed in its normal position between the cranial aspect of the right kidney and the caudal vena cava. It is normal in appearance (uniformly hypoechoic) and shape with no evidence of a mass effect.

HOSPITAL NAME

Animal Emergency
Hospital

Spleen

The spleen is subjectively normal in size, echotexture is homogenous, and the splenic capsule is smooth with no irregularities. The blood flow through the hilus and splenic parenchyma appears normal. There is a small intraparenchymal hypoechoic nodule measuring 0.74 cm visualized.

REFERRING VET

Dr. King

Liver

The liver is subjectively normal in size, and echogenicity with smooth peripheral margins. The parenchyma is homogenous echotexture. The visible portions of the vasculature and biliary tract appear normal. No focal nodules or cystic lesions are observed.

INVOICE

42103

The gallbladder lumen is moderately distended. The wall of the gall bladder is not thickened and has a smooth mucosal surface. Luminal contents are mild and primarily anechoic. The cystic and common bile ducts are normal/not visible.

Gastrointestinal

The stomach is mildly dilated with fluid and irregular shadowing material most consistent with normal ingesta and gas. It measures at a normal thickness of <0.7cm with some variability due to the presence of rugal folds. The distinction of the gastric wall layering is adequate and there is no impression of reduced peristaltic activity. No masses or focal lesions were observed.

The visualized areas of duodenum, jejunum and ileum have a relatively uniform diameter with minimal fluid distension. Wall thickness is normal. Bowel loops follow a curvilinear path with distinct wall layering maintaining the typical 1:3 muscularis:mucosa layer ratio. The duodenum measured as normal (between 0.3-0.5cm in wall thickness) and the jejunum measured as normal (between 0.2-0.47cm.) Visualized peristalsis appears appropriate. There were no focal lesions consistent with obstruction or a mass effect observed.

The ileocecal junction was visualized and exhibited normal intact wall layering and is subjectively of normal thickness. Sections of colon are visualized with formed fecal material and gas shadowing distally. There is no observed focal or generalized colon wall thickening or loss of layering.

Pancreas

The pancreas is prominent and mottled compared to the surrounding isoechoic mesentery. There is no evidence of nodules or cystic lesions. There is no evidence of regional mesenteric inflammation or fluid.

Free Abdomen

Evaluation of the peritoneal cavity did not reveal any evidence of effusion, or subjective lymphadenomegaly. The Medial iliac nodes appear normal and there was no evidence of a caudal aortic thrombus at the bifurcation. The omentum is of normal uniform echogenicity.

Other

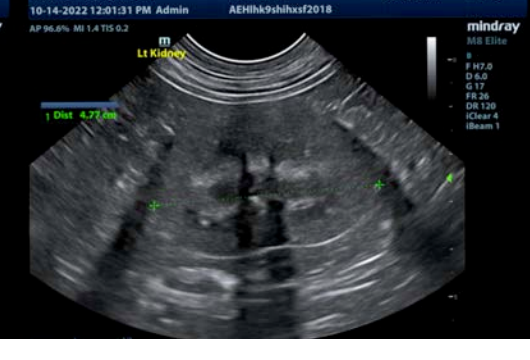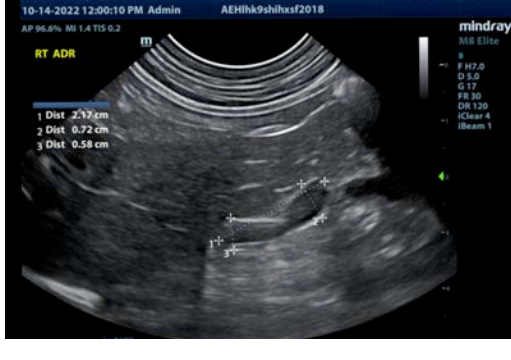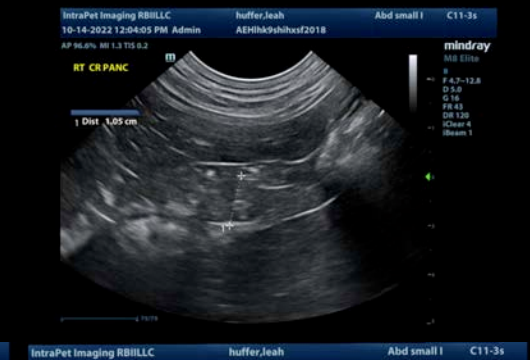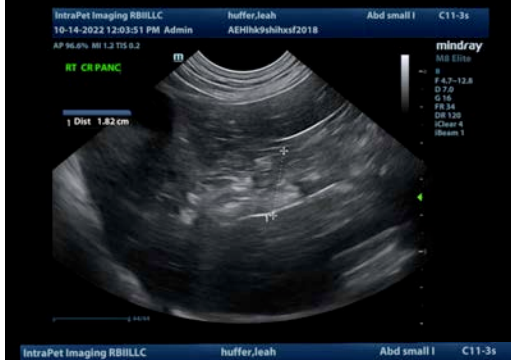
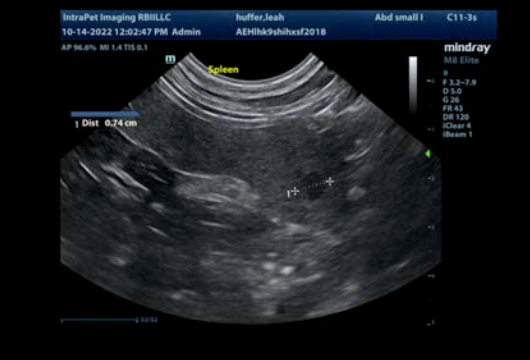
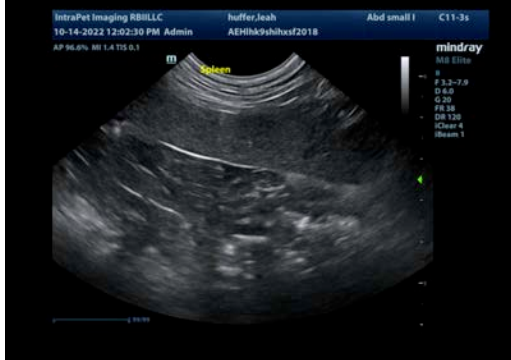
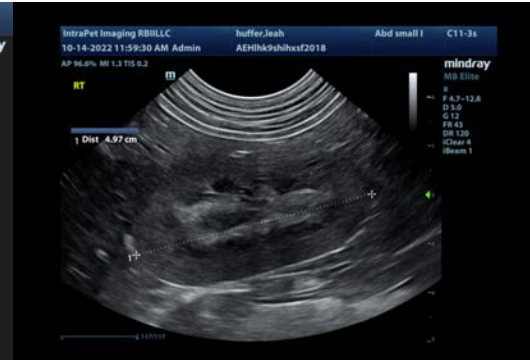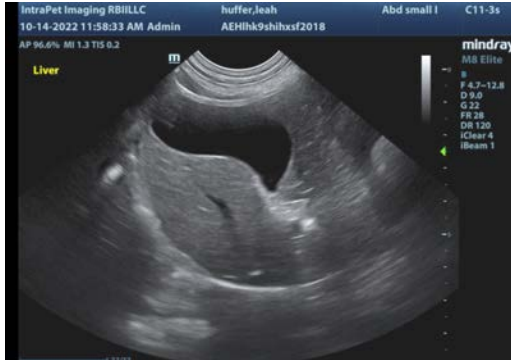A brief view of the heart was submitted. No significant pericardial effusion was seen.

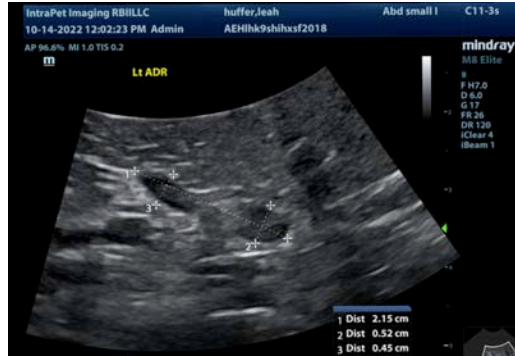
ULTRASONOGRAPHIC FINDINGS

- Hypoechoic nodule visualized in the spleen – There is a non-cavitated, hypoechoic splenic nodule visualized. Differentials include lymphoid hyperplasia, extramedullary hematopoiesis, infiltrative neoplasia, inflammation, other. Cytology or histopathology would be necessary to get a definitive diagnosis.
- Mildly mottled pancreas – The pancreatic changes are most consistent with age-related parenchymal remodeling, potentially secondary to a prior inflammatory episode, early fibrosis or chronic pancreatitis.
- Mild pyelectasia of the right kidney – Pyelectasia of the kidney(s) could be consistent with pyelonephritis, chronic renal disease, secondary to PU/PD or fluid therapy (if applicable), other.

INTERPRETATION OF THE FINDINGS & FURTHER RECOMMENDATIONS

The findings on today's scan are relatively mild. The pancreatic changes are likely incidental. There is a small hypoechoic nodule in the spleen. I suspect this would be challenging to aspirate at this point due to its small size but recommend continued monitoring (recheck ultrasound in 8-12 weeks). Additionally, there is a small amount of pyelectasia in the right kidney with no obvious obstruction visualized. This could be a normal variation, but given the likelihood of immunosuppression in this patient, recommend a urinalysis and culture.





The information and recommendations provided are based on the images presented by the referring veterinarian/sonographer. No evaluation can be communicated regarding pathology that was not visible in the image/video clips provided.

Thank you for this referral. If the clinical or image interpretation does not parallel your findings or if I can be of any further assistance please contact me.

Kathleen Sennello DVM,MS, Diplomate ACVIM (Small animal Internal Medicine)
kathleen.sennello@sonopath.com