

**DATE PRESENTING CLINICAL SIGNS**

10/14/22 V/D. concern for severe gas distention of stomach went over possible GI FB vs functional ileus.

PATIENT Current Medications: Ondansetron, Metronidazole.

Lab Results: See attached.

Katara Naujokas Radiographs: Repeat lat abdomen- still significantly fluid dilated stomach, concern for radiolucent pyloric outflow obstruction

SPECIES Date of Previous IntraPet Ultrasound: No previous.

Sedation: Not required to complete full diagnostic ultrasound.

Canine

Stat Report: Not requested.

BREED ULTRASONOGRAPHIC EXAMINATION OF THE ABDOMEN

Rottweiler X

Urinary System

The urinary bladder is moderately distended with anechoic urine. The Bladder wall, trigone, ureteral papillae and visible urethra (to a depth of 2cm) appear normal with no evidence of wall thickening, mucosal irregularities, masses or cystic calculi.

SEX

Spayed Female

The left kidney has a normal shape and size (7.92 cm). Overall echogenicity is normal with adequate corticomedullary distinction and a typical 1:3 cortex:medulla ratio. There is no evidence of focal perinephric inflammation or effusion. There is no evidence of pyelectasia, nephroliths, infarcts or hydroureter. Renal vasculature is normal.

AGE

9/25/20

WEIGHT

94 Pounds

The right kidney has a normal shape and size (7.63 cm). Overall echogenicity is normal with adequate corticomedullary distinction and a typical 1:3 cortex:medulla ratio. There is no evidence of focal perinephric inflammation or effusion. There is no evidence of pyelectasia, nephroliths, infarcts or hydroureter. Renal vasculature is normal.

INTERPRETED BY

Kathleen Sennello DVM,
MS, Diplomate ACVIM
(Small Animal Internal
Medicine)

Adrenal Glands

The left adrenal gland is normal in size measuring 0.52 cm at the caudal pole. It is observed in its normal position cranial to the left renal artery. It is normal in appearance (uniformly hypoechoic) and shape with no evidence of a mass effect.

IMAGING PERFORMED BY

Rachel Brilhart RDMS

The right adrenal gland is normal in size measuring 0.72 cm at the caudal pole. It is observed in its normal position between the cranial aspect of the right kidney and the caudal vena cava. It is normal in appearance (uniformly hypoechoic) and shape with no evidence of a mass effect.

HOSPITAL NAME

Animal Emergency
Hospital

Spleen

The spleen is subjectively normal in size, echotexture is homogenous, and the splenic capsule is smooth with no irregularities. The blood flow through the hilus and splenic parenchyma appears normal. No focal parenchymal abnormalities are visualized.

REFERRING VET

Dr. Thompson

Liver

The liver is subjectively normal in size, and echogenicity with smooth peripheral margins. The parenchyma is homogenous echotexture. The visible portions of the vasculature and biliary tract appear normal. No focal nodules or cystic lesions are observed.

INVOICE

42101

The gallbladder lumen is moderately distended. The wall of the gall bladder is not thickened and has a smooth mucosal surface. Luminal contents are mild and primarily anechoic. The cystic and common bile ducts are normal/not visible.

Gastrointestinal

The stomach is severely dilated with fluid and some occasional linear shadowing material, most consistent with ingesta, gas, and fluid. The stomach measures 12.98 cm x 11.08 cm. The gastric wall measures at a normal thickness of <0.7cm with some variability due to the presence of rugal folds. The distinction of the gastric wall layers is adequate. Fluid dilation extends into the pyloric region, which appears somewhat plicated with the suggestion of linear material and a possible linear foreign body. No mass lesions are observed.

The visualized areas of duodenum, jejunum and ileum have a relatively uniform diameter with minimal to moderate fluid distension. Wall thickness is normal. Bowel loops follow a curvilinear path with distinct wall layering maintaining the typical 1:3 muscularis:mucosa layer ratio. Wall thickness measures 0.26 cm. Visualized peristalsis appears appropriate. There are some areas of small bowel that have mild to moderate fluid distention, but no shadowing foreign material is observed.

The ileocecal junction was visualized and exhibited normal intact wall layering and is subjectively of normal thickness. Sections of colon are visualized with formed fecal material and gas shadowing distally. There is no observed focal or generalized colon wall thickening or loss of layering.

Pancreas

The area of the pancreas is normal and isoechoic to surrounding mesentery. There is no evidence of nodules or cystic lesions. There is no evidence of regional mesenteric inflammation or fluid.

Free Abdomen

Evaluation of the peritoneal cavity did not reveal any evidence of effusion. There is a prominent mesenteric lymph node visualized near the spleen measuring 3.4 cm x 1.86 cm. The omentum is hyperechoic in the region of the pylorus.

Other

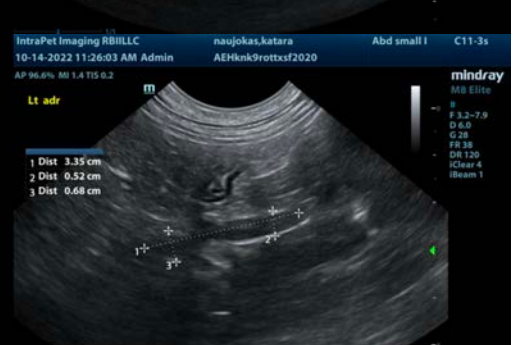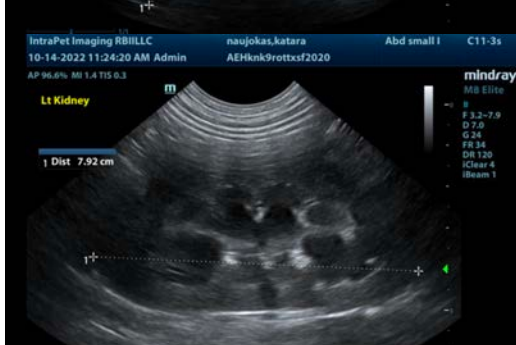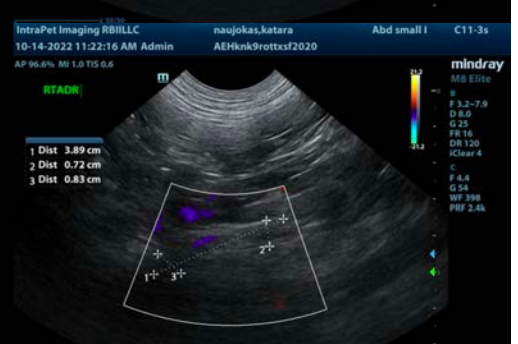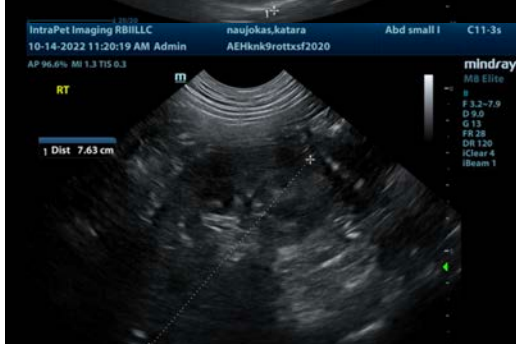
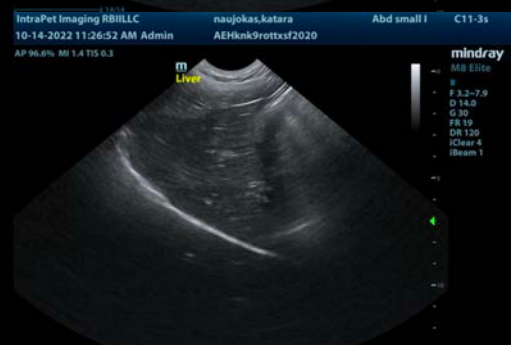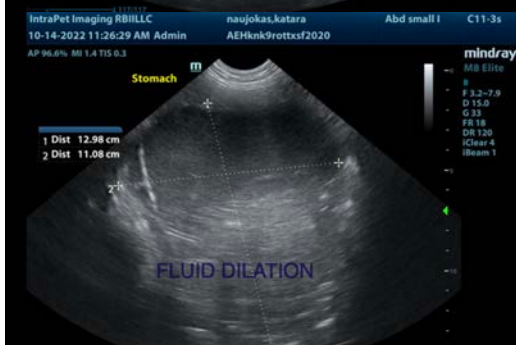
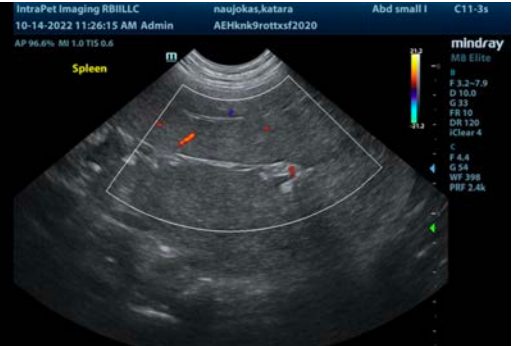
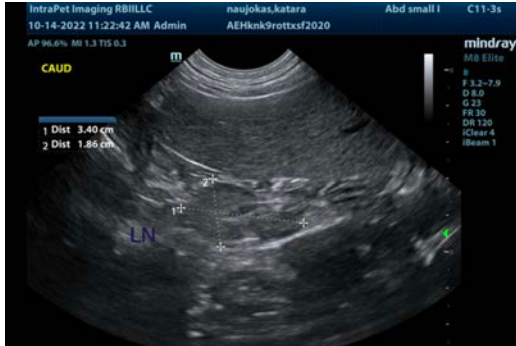A brief view of the heart was submitted. No significant pericardial effusion was seen.

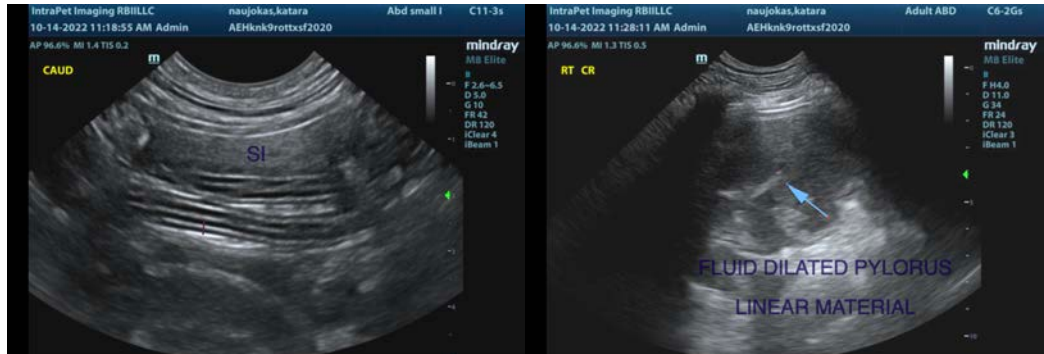
ULTRASONOGRAPHIC FINDINGS

- Severely fluid dilated stomach with a slightly corrugated/plicated pylorus and intraluminal linear material – findings are concerning for a possible linear foreign body/partial pyloric outflow tract obstruction.
- Prominent splenic lymph node – Differentials include inflammation, infection, and neoplastic disease.

INTERPRETATION OF THE FINDINGS & FURTHER RECOMMENDATIONS

The stomach is severely distended with fluid and some striated linear material. No large shadowing foreign material is observed and no mass lesions are observed. The pyloric region appears severely fluid dilated but somewhat corrugated and there is the hint of possible linear material, suggestive of a possible linear foreign body. There is hyperechoic tissue surrounding this region and there is no evidence of an obstructive pattern distally or shadowing material observed. Options moving forward would include hospitalization and continued monitoring with serial radiographs, or exploratory to decompress the stomach, obtain GI biopsies, and determine if there is a foreign body present.





The information and recommendations provided are based on the images presented by the referring veterinarian/sonographer. No evaluation can be communicated regarding pathology that was not visible in the image/video clips provided.

Thank you for this referral. If the clinical or image interpretation does not parallel your findings or if I can be of any further assistance please contact me.

Kathleen Sennello DVM,MS, Diplomate ACVIM (Small animal Internal Medicine)
kathleen.sennello@sonopath.com