

**DATE PRESENTING CLINICAL SIGNS**

10/14/22

Patient presented for 4 day history of diarrhea, with increased urgency/frequency, and small amount of blood. No recent change in diet, no new treats or tablefood. Decreased appetite x 1 day. Physical exam: mm pink, moist, crt 2 sec. H/L auscult NSF. Abd - large cranial abdominal mass palpated on physical exam. Radiographs showed mass present in cranial abdomen (likely spleen).

**PATIENT**

Bentley Fischer

**SPECIES**

Canine

Current Medications: Cerenia 20 mg SQ, Metronidazole 250 mg PO, Provable Forte started today

Lab Results: ALT increased 148 U/L All else WNL. Hct 47.5%

Date of Previous IntraPet Ultrasound: No previous.

Sedation: Not required to complete full diagnostic ultrasound.

Stat Report: STAT Requested.

**BREED**

Labrador

**ULTRASONOGRAPHIC EXAMINATION OF THE ABDOMEN****Urinary System****SEX**

Neutered Male

The urinary bladder is moderately distended with anechoic urine. The Bladder wall, trigone, ureteral papillae and visible urethra (to a depth of 2cm) appear normal with no evidence of wall thickening, mucosal irregularities, masses or cystic calculi.

**AGE**

5/14/09

The prostate is normal in size (1.25 cm) and shape for this neutered male dog. The parenchyma is homogenous and the external margins are smooth. The prostatic urethra appears normal with no evidence of irregularity, invasion, mass effect or calculi.

**WEIGHT**

47.6 Pounds

The left kidney has a normal shape and size (6.6 cm). Overall echogenicity is normal with adequate corticomedullary distinction and a typical 1:3 cortex:medulla ratio. There is no evidence of focal perinephric inflammation or effusion. There is no evidence of pyelectasia, nephroliths, infarcts or hydroureter. Renal vasculature is normal.

**INTERPRETED BY**

Kathleen Sennello DVM,  
MS, Diplomate ACVIM  
(Small Animal Internal  
Medicine)

The right kidney has a normal shape and size (5.24 cm). Overall echogenicity is normal with adequate corticomedullary distinction and a typical 1:3 cortex:medulla ratio. There is no evidence of focal perinephric inflammation or effusion. There is no evidence of pyelectasia, nephroliths, infarcts or hydroureter. Renal vasculature is normal.

**IMAGING PERFORMED BY**

Rachel Brilhart RDMS

**Adrenal Glands**

The left adrenal gland is normal in size measuring 0.72 cm at the caudal pole. It is observed in its normal position cranial to the left renal artery. It is normal in appearance (uniformly hypoechoic) and shape with no evidence of a mass effect.

**HOSPITAL NAME**

Hickory Vet Hospital

The right adrenal gland is normal in size measuring 0.82 cm at the caudal pole. It is observed in its normal position between the cranial aspect of the right kidney and the caudal vena cava. It is normal in appearance (uniformly hypoechoic) and shape with no evidence of a mass effect.

**REFERRING VET**

Dr. McNesby

**Spleen**

The spleen is subjectively normal in size, echotexture is homogenous, and the splenic capsule is smooth with no irregularities. The blood flow through the hilus and splenic parenchyma appears normal. No focal parenchymal abnormalities are visualized.

**INVOICE**

42053

**Liver**

The liver is large in size, and normal in echogenicity with smooth peripheral margins. The parenchyma is heterogenous in echotexture with subtle, indistinct focal mottling. The visible portions of the vasculature and biliary tract appear normal. There is an extremely large cystic structure visualized on the left side of the liver

with somewhat echogenic fluid. This cystic structure measures 14.4 cm x 11.5 cm. Additionally there is a 1.26 cm diameter hyperechoic nodule in the caudate lobe of the liver.

The gallbladder lumen is moderately distended. The wall of the gall bladder is not thickened and has a smooth mucosal surface. Luminal contents are mild and primarily anechoic. The cystic and common bile ducts are normal/not visible.

### ***Gastrointestinal***

The stomach contains minimal luminal contents. It measures at a normal thickness of <0.7cm with some variability due to the presence of rugal folds. The distinction of the gastric wall layers is adequate and there is no impression of reduced peristaltic activity. No masses or focal lesions were observed.

The visualized areas of duodenum, jejunum and ileum have a relatively uniform diameter with minimal fluid distension. Wall thickness is normal. Bowel loops follow a curvilinear path with distinct wall layering maintaining the typical 1:3 muscularis:mucosa layer ratio. The duodenum measured as normal (between 0.3-0.5cm in wall thickness) and the jejunum measured as normal (between 0.2-0.47cm.) Visualized peristalsis appears appropriate. There were no focal lesions consistent with obstruction or a mass effect observed.

The ileocecal junction was visualized and exhibited normal intact wall layering and is subjectively of normal thickness. Sections of colon are visualized with formed fecal material and gas shadowing distally. There is no observed focal or generalized colon wall thickening or loss of layering.

### ***Pancreas***

The pancreas is normal and isoechoic to surrounding mesentery. There is no evidence of nodules or cystic lesions. There is no evidence of regional mesenteric inflammation or fluid.

### ***Free Abdomen***

Evaluation of the peritoneal cavity did not reveal any evidence of effusion, or subjective lymphadenomegaly. The Medial iliac nodes appear normal and there was no evidence of a caudal aortic thrombus at the bifurcation. The omentum is of normal uniform echogenicity.

### ***Other***

A brief view of the heart was submitted. No significant pericardial effusion was seen.

## **ULTRASONOGRAPHIC FINDINGS**

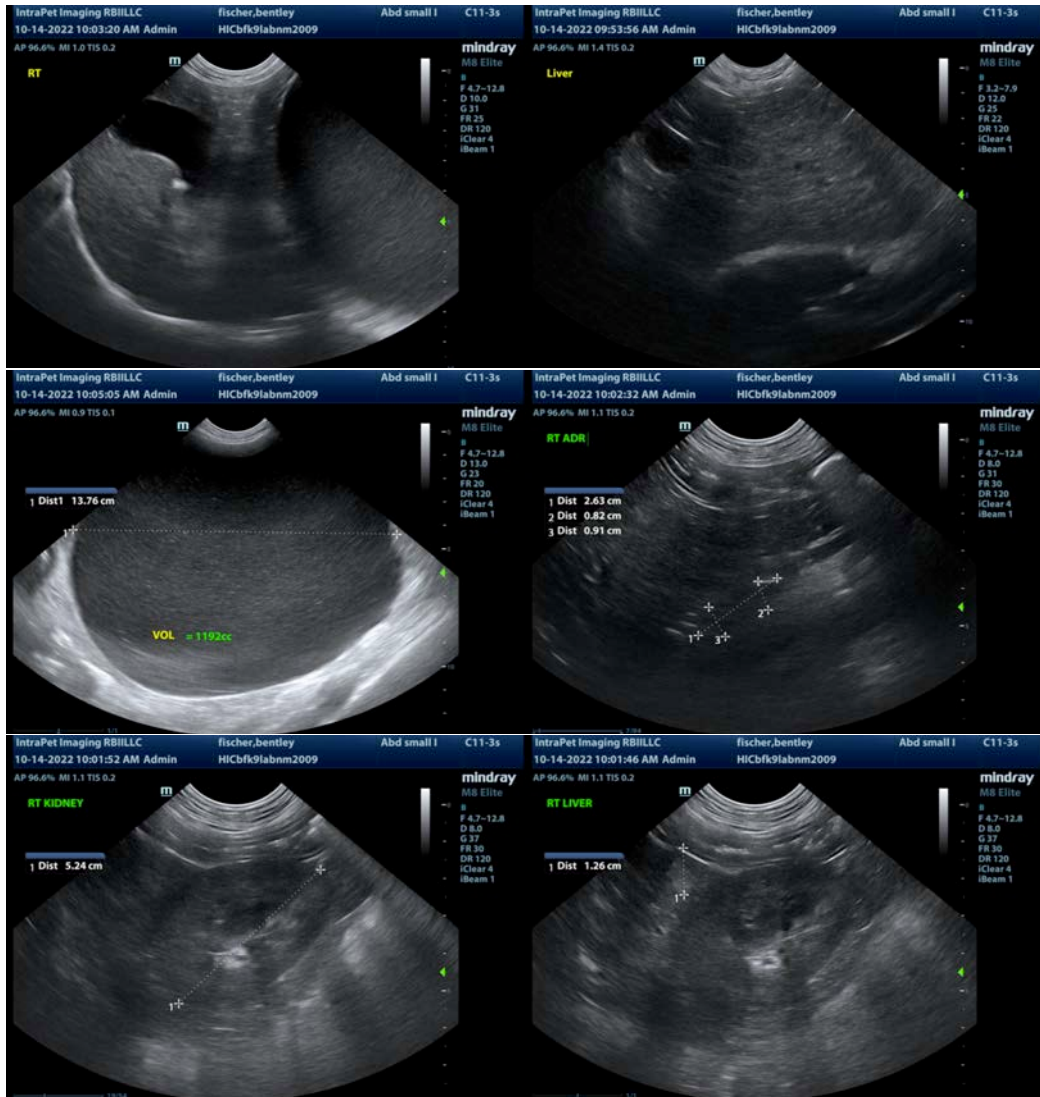
- Large, echogenic cystic structure visualized associated with the liver – Findings are most consistent with a benign hepatic cyst, although an abscess or origination with another structure is possible (but less likely).
- Small hyperechoic nodule in caudate lobe of the liver - The appearance off this nodule is most consistent with a benign nodule. Recommend continued monitoring as a neoplastic lesion cannot be ruled out.

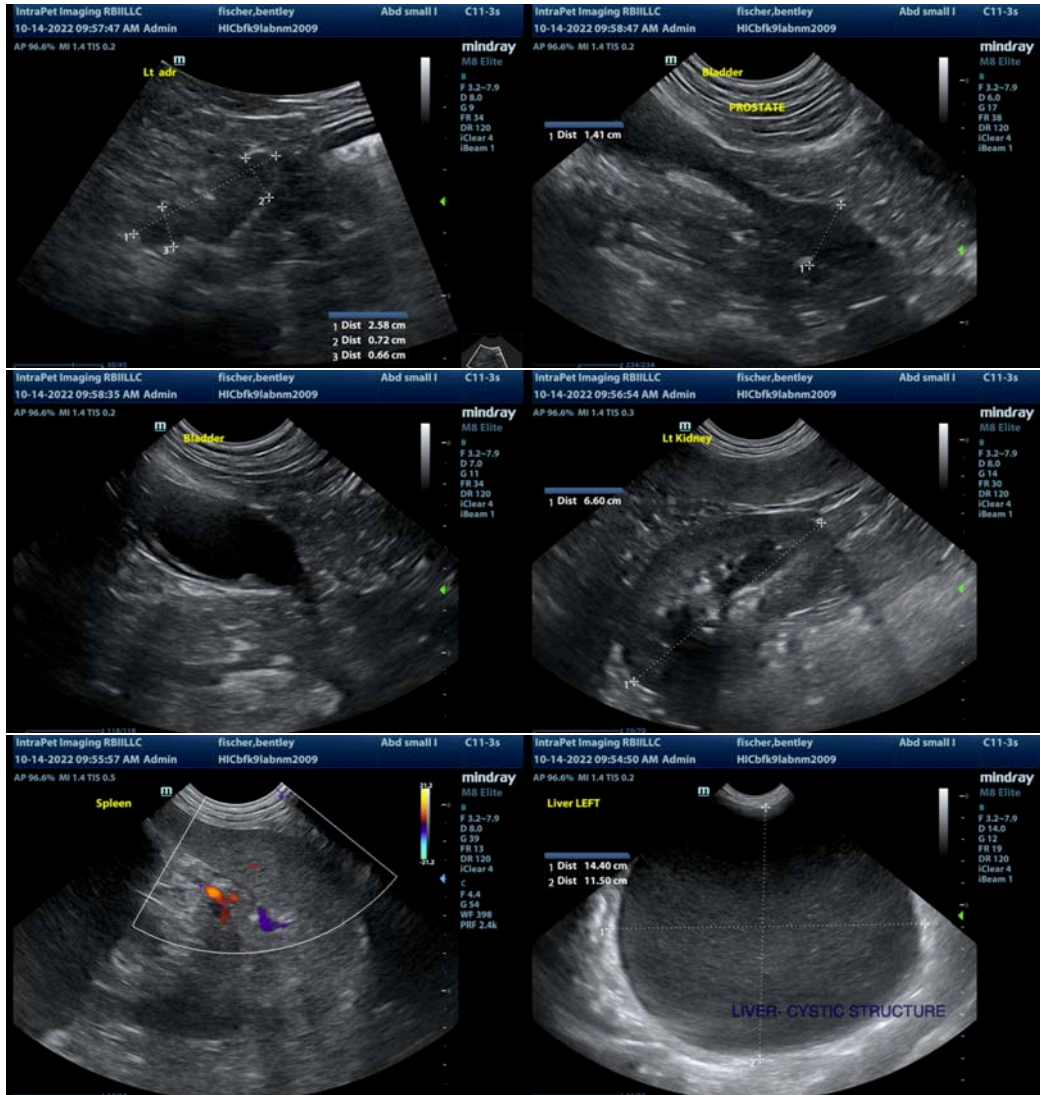
## **INTERPRETATION OF THE FINDINGS & FURTHER RECOMMENDATIONS**

The mass effect seen on radiographs is likely the large cystic structure visualized on ultrasound. This contains somewhat echogenic fluid and is most consistent with an echogenic benign hepatic cyst, although an abscess or origination with another structure is possible. Options moving forward would include drainage of this cystic structure percutaneously. If this is done, ideally the needle should pass through hepatic parenchyma prior to entering the cystic structure to try and prevent backflow of the fluid into the free abdomen. The fluid should be submitted for fluid analysis and cytology +/- aerobic and anaerobic cultures. Alternately, you could

consider a contrast CT scan to consider removal of the cystic structure, as recurrence after drainage is extremely likely.

No lesions were visualized associated with the GI tract to explain the diarrhea reported. Recommend continued symptomatic therapy for acute diarrhea, including dietary management, probiotics, etc.





The information and recommendations provided are based on the images presented by the referring veterinarian/sonographer. No evaluation can be communicated regarding pathology that was not visible in the image/video clips provided.

Thank you for this referral. If the clinical or image interpretation does not parallel your findings or if I can be of any further assistance please contact me.

Kathleen Sennello DVM,MS, Diplomate ACVIM (Small animal Internal Medicine)  
 kathleen.sennello@sonopath.com