



PATIENT

Sugar Zarei

PRESENTING CLINICAL SIGNS

sedated 0.15ml medetomidine/0.1torb IV- Chief Concern / Provisional Diagnosis: ~~ Determine cause for poorly regulated diabetes Relevant Medical History and Physical Exam findings: ~~ Diabetes mellitus Elevated liver enzymes Recent Diagnostics: Relevant Laboratory Results / Abnormalities: ~~ cbc unremarkable chem abnormal- glucose 491 (63-114), phos 1.7 (2.5-6.1), alt 253 (18-21), ast 103 (16-55), alp 542 (5-160), chol 895 (131-345), lipase 332 (0-250) Urinalysis - 3+ glucose, ph >9, otherwise unremarkable Urine culture and MIC on 9/29/21 showed no growth Current medications (include full name, dosage and frequency): ~~ Denamarin 225mg, 1 tab po Q24h Vetsulin 17U SQ Q12h

SPECIES

Canine

BREED

Retriever/Lab

ULTRASONOGRAPHIC EXAMINATION OF THE ABDOMEN

SEX

Spayed Female

Urinary System

The urinary bladder is moderately distended with anechoic urine. The Bladder wall, trigone, ureteral papillae and visible urethra (to a depth of 2cm) appear normal with no evidence of wall thickening, mucosal irregularities, masses or cystic calculi.

AGE

9 Years

The left kidney has a normal shape and size (6.45 cm). Overall echogenicity is normal with adequate corticomedullary distinction and a typical 1:3 cortex:medulla ratio. There is no evidence of perinephric inflammation or effusion. There is no evidence of pyelectasia, nephroliths, infarcts or hydroureter. There is mild corticomedullary rim sign. Renal vasculature is normal.

WEIGHT

78 Pounds

The right kidney has a normal shape and size (7.39 cm). Overall echogenicity is normal with adequate corticomedullary distinction and a typical 1:3 cortex:medulla ratio. There is no evidence of perinephric inflammation or effusion. There is no evidence of pyelectasia, nephroliths, infarcts or hydroureter. Renal vasculature is normal.

INTERPRETED BY

Kathleen Sennello DVM,
MS, Diplomate ACVIM
(Small Animal Internal
Medicine)

Adrenal Glands

The left adrenal gland is normal in size measuring 0.56 cm at the caudal pole. It is observed in its normal position cranial to the left renal artery. It is normal in appearance (uniformly hypoechoic) and shape with no evidence of a mass effect.

IMAGING PERFORMED BY

Loetitia Saint-Jacques, RVT

The right adrenal gland is normal in size measuring 0.61 cm at the caudal pole. It is observed in its normal position between the cranial aspect of the right kidney and the caudal vena cava. It is normal in appearance (uniformly hypoechoic) and shape with no evidence of a mass effect.

HOSPITAL NAME

MountainView AH

Spleen

The spleen is subjectively normal in size, echotexture is homogenous, and the splenic capsule is smooth with no irregularities. The blood flow through the hilus and splenic parenchyma appears normal. No focal parenchymal abnormalities are visualized.

REFERRING VET

Dr. Pablo Mendoza

Liver

The liver is large in size, and normal echogenicity with smooth peripheral margins. The parenchyma is heterogenous in echotexture with subtle, indistinct focal mottling. The visible portions of the vasculature and biliary tract appear normal. No focal nodules or cystic lesions are observed.

INVOICE

26309

The gall bladder lumen is moderately distended. The wall of the gall bladder is not thickened and has a smooth mucosal surface. There is a moderate amount of non-organized echogenic debris. The cystic and common bile ducts are normal/not visible.

DATE

10/15/21

Gastrointestinal



PATIENT

Sugar Zarei The stomach is moderately dilated with fluid and irregular shadowing material most consistent with normal ingesta and gas. It measures at a normal thickness of <0.7cm with some variability due to the presence of rugal folds. The distinction of the gastric wall layering is adequate and there is no impression of reduced peristaltic activity. No masses or focal lesions were observed.

SPECIES

Canine The visualized areas of duodenum, jejunum and ileum have a relatively uniform diameter with minimal fluid distension. Wall thickness is normal. Bowel loops follow a curvilinear path with distinct wall layering maintaining the typical 1:3 muscularis:mucosa layer ratio. The duodenum measured as normal (between 0.3-0.5cm in wall thickness) and the jejunum measured as normal (between 0.2-0.47cm.)

BREED

Retriever/Lab Visualized peristalsis appears appropriate. There were no focal lesions consistent with obstruction or a mass effect observed.

SEX

Spayed Female The ileocecal junction was visualized and exhibited normal intact wall layering and is subjectively of normal thickness. Sections of colon are visualized with formed fecal material and gas shadowing distally. There is no observed focal or generalized colon wall thickening or loss of layering.

Pancreas

AGE

9 Years The pancreas is prominent and hypoechoic as compared to the surrounding isoechoic mesentery. There is no evidence of nodules or cystic lesions. There is no evidence of regional mesenteric inflammation or fluid.

WEIGHT

Free Abdomen

78 Pounds Evaluation of the peritoneal cavity did not reveal any evidence of effusion, or subjective lymphadenomegaly. The Medial iliac nodes appear normal and there was no evidence of a caudal aortic thrombus at the bifurcation. The omentum is of normal uniform echogenicity.

INTERPRETED BY

Kathleen Sennello DVM,
MS, Diplomate ACVIM
(Small Animal Internal
Medicine)

Other

A brief view of the heart was submitted. No significant pericardial effusion was seen.

IMAGING PERFORMED BY

Loetitia Saint-Jacques, RVT

PRIMARY FINDINGS

- Large, heterogeneous liver – The diffuse hepatic changes are non-specific and could be consistent with vacuolar hepatopathy, nodular hyperplasia, inflammatory/immune-mediated disease, fibrosis, extramedullary hematopoiesis, toxic hepatopathy (e.g., copper), infiltrative neoplasia (less likely) or other hepatopathy.
- Hypoechoic, prominent pancreas – The pancreatic changes are most consistent with age-related parenchymal remodeling, potentially secondary to a prior inflammatory episode, early fibrosis or chronic pancreatitis.
- Moderate to large amount of ingesta within the gastric lumen – correlate with feeding history. If adequately fasted, then this could be consistent with delayed gastric emptying or a partial gastric obstruction (none observed).

HOSPITAL NAME

MountainView AH

REFERRING VET

Dr. Pablo Mendoza

SECONDARY FINDINGS

- Subtle corticomedullary rim sign present – Clinical significance uncertain, can be seen in normal patients and in cases of ethylene glycol toxicity, chronic interstitial nephritis, and leptospirosis.

INVOICE

26309

DATE

10/15/21



PATIENT

Sugar Zarei

SPECIES

Canine

BREED

Retriever/Lab

SEX

Spayed Female

AGE

9 Years

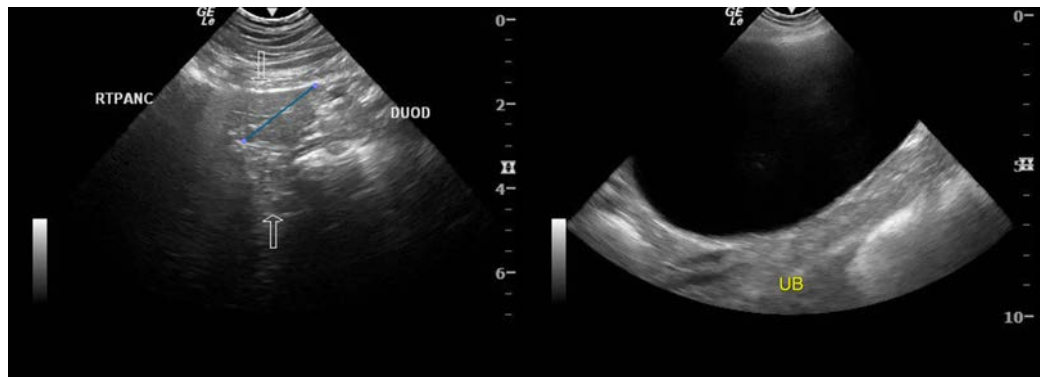
WEIGHT

78 Pounds

INTERPRETATION OF THE FINDINGS & FURTHER RECOMMENDATIONS

No obvious changes are observed to explain the poor diabetic regulation reported. The pancreas is prominent, but does not appear overtly inflamed. You could consider a quantitative fPLI to look for evidence of inflammation that is not readily apparent on ultrasound. Additionally, the liver is heterogeneous and hyperechoic. This is a common finding in diabetics with vacuolar hepatopathy and hepatic lipidosis secondary to their metabolic disease. Consider liver function test and fine needle aspirate if there is concern for more significant liver disease present.

The stomach is moderately dilated with food. This is likely an incidental finding, but if the patient was adequately fasted, then consider delayed gastric emptying, underlying GI disease, even gastric foreign material.



INTERPRETED BY

Kathleen Sennello DVM,
MS, Diplomate ACVIM
(Small Animal Internal
Medicine)

IMAGING PERFORMED BY

Loetitia Saint-Jacques, RVT

HOSPITAL NAME

MountainView AH

REFERRING VET

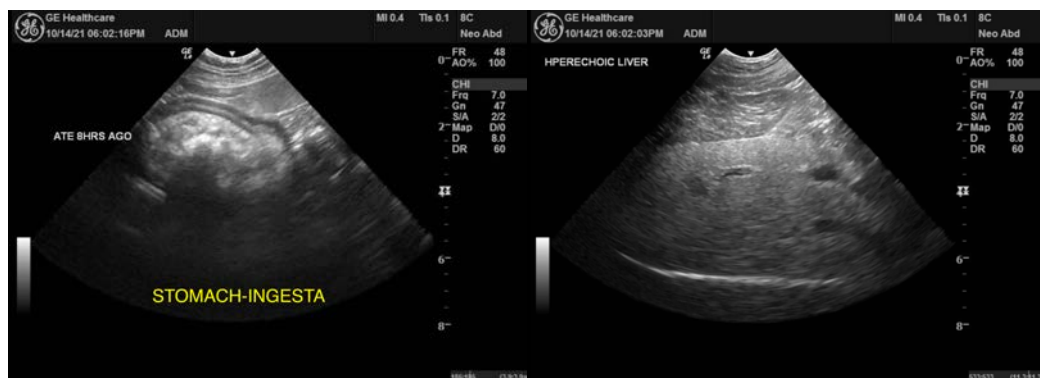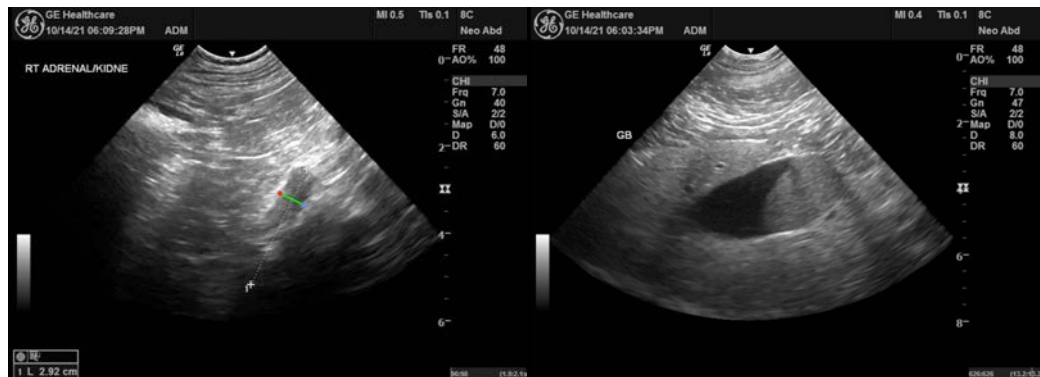
Dr. Pablo Mendoza

INVOICE

26309

DATE

10/15/21





PATIENT

Sugar Zarei

SPECIES

Canine

BREED

Retriever/Lab

SEX

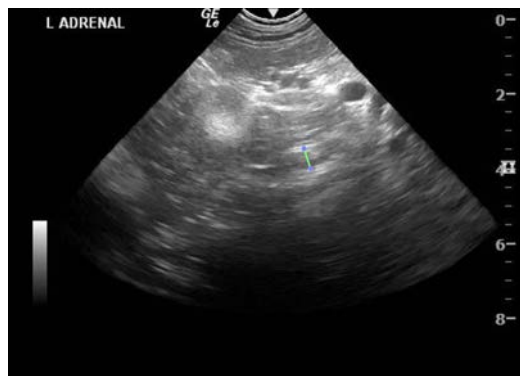
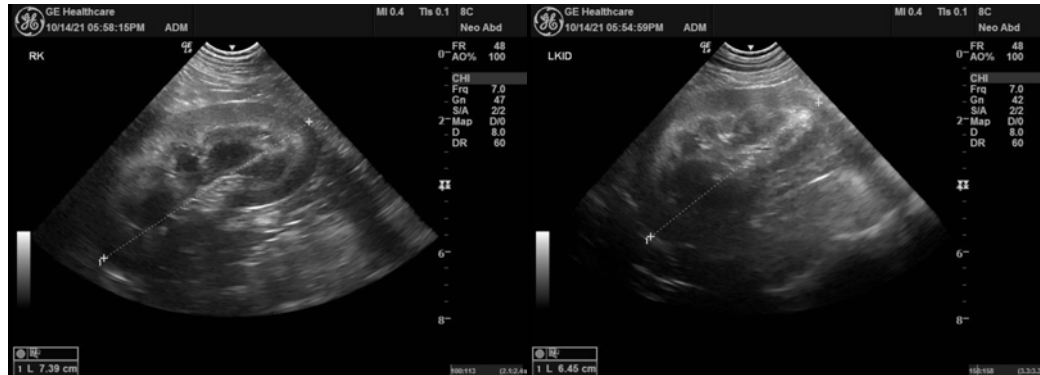Spayed Female

AGE

9 Years

WEIGHT

78 Pounds



INTERPRETED BY

Kathleen Sennello DVM,
MS, Diplomate ACVIM
(Small Animal Internal
Medicine)

IMAGING PERFORMED BY

Loetitia Saint-Jacques, RVT

HOSPITAL NAME

MountainView AH

REFERRING VET

Dr. Pablo Mendoza

INVOICE

26309

DATE

10/15/21

The information and recommendations provided are based on the images presented by the referring veterinarian. No evaluation can be communicated regarding pathology that was not visible in the image/video clips provided.

Thank you for this referral. If the clinical or image interpretation does not parallel your findings or if I can be of any further assistance please contact me.

Kathleen Sennello DVM,MS, Diplomate ACVIM (Small animal Internal Medicine)

kathleen.sennello@sonopath.com