



PATIENT

Samy Aeschilmann

PRESENTING CLINICAL SIGNS

Not sedated, became agitated quickly. PAWS Request Form: Chief Concern / Provisional Diagnosis: ~chronic weight loss w/ good appetite (12.5lb in 2017, 10.8lb march 2020, current weight 7.5lb) ~ Relevant Medical History and Physical Exam findings: ~hx of on and off diarrhea, weight loss despite good appetite. energy level is overall good. ~ Recent Diagnostics: Relevant Laboratory Results / Abnormalities: ~BUN 40 (16-37), USG 1.018, ProBNP 104 (0-100), total t4 4.1 (0.8-4.7)~ Current medications (include full name, dosage and frequency): ~recent tx w/ metronidazole benzoate, probiotics~

SPECIES

Feline

BREED

DLH

ULTRASONOGRAPHIC EXAMINATION OF THE ABDOMEN

SEX

Neutered Male

Urinary System

The urinary bladder is moderately distended with anechoic urine. The Bladder wall, trigone, ureteral papillae and visible urethra (to a depth of 2cm) appear normal with no evidence of wall thickening, mucosal irregularities, masses or cystic calculi.

AGE

16 Years

The left kidney has a normal shape and size (3.71 cm) and is very hyperechoic. There is poor corticomedullary distinction and a typical 1:3 cortex:medulla ratio. There is no evidence of perinephric inflammation or effusion. There is no evidence of pyelectasia, nephroliths, infarcts or hydroureter. Renal vasculature is normal.

WEIGHT

7.5 Pounds

The right kidney has a normal shape and size (3.7 cm) and is very hyperechoic. There is poor corticomedullary distinction and a typical 1:3 cortex:medulla ratio. There is no evidence of perinephric inflammation or effusion. There is no evidence of pyelectasia, nephroliths, infarcts or hydroureter. Renal vasculature is normal.

INTERPRETED BY

Kathleen Sennello DVM,
MS, Diplomate ACVIM
(Small Animal Internal
Medicine)

Adrenal Glands

The left adrenal gland is normal/borderline enlarged in size measuring XX cm at the caudal pole. It is observed in its normal position cranial to the left renal artery. It is normal in appearance (uniformly hypoechoic) and shape with no evidence of a mass effect.

IMAGING PERFORMED BY

Loetitia Saint-Jacques, RVT

The right adrenal gland is normal in size measuring XX cm at the caudal pole. It is observed in its normal position between the cranial aspect of the right kidney and the caudal vena cava. It is normal in appearance (uniformly hypoechoic) and shape with no evidence of a mass effect.

HOSPITAL NAME

MountainView AH

Spleen

The spleen is subjectively normal in size. The spleen echotexture is heterogenous and mottled, the splenic capsule is smooth with no irregularities. Numerous hyperechoic foci/nodules and a 0.72 cm hypoechoic nodule were visualized. The blood flow through the hilus and splenic parenchyma appears normal.

REFERRING VET

Dr. Sarah Kalivoda

Liver

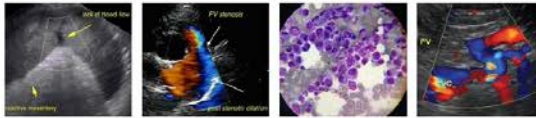
The liver is subjectively normal in size, and echogenicity with smooth peripheral margins. The parenchyma is mildly heterogenous in echotexture with subtle, indistinct focal mottling. The visible portions of the vasculature and biliary tract appear normal. There is a hypoechoic nodule visualized, measuring 0.7 cm x 0.91 cm.

INVOICE

26306

DATE

10/14/21



PATIENT

Samy Aeschilmann The gallbladder lumen is moderately distended. The wall of the gall bladder is not thickened and has a smooth mucosal surface. Luminal contents are primarily anechoic. The cystic and common bile ducts are normal/not visible.

SPECIES

Feline

Gastrointestinal

The stomach contains minimal luminal contents. It measures at a normal thickness of <0.36cm with some variability due to the presence of rugal folds. The distinction of the gastric wall layers is adequate and there is no impression of reduced peristaltic activity. No masses or focal lesions were observed.

BREED

DLH

The visualized areas of duodenum, jejunum and ileum have a uniform diameter with minimal fluid distension. Wall thickness is normal to slightly increased. Bowel loops follow a typical curvilinear path with distinct wall layering, but some areas display a prominent muscularis layer which does not display the typical 1:3 muscularis:mucosa layer ratio. Jejunum wall measured 0.32 cm. Visualized peristalsis appears appropriate. There were no focal lesions consistent with obstruction or a mass effect observed.

SEX

Neutered Male

The ileocecal junction was visualized and exhibited normal intact wall layering and is subjectively of normal thickness. Sections of colon are visualized with liquid fecal material and gas shadowing distally. There is no observed focal or generalized colon wall thickening or loss of layering.

AGE

16 Years

Pancreas

The pancreas is prominent and hypoechoic as compared to the surrounding isoechoic mesentery. There is no evidence of nodules or cystic lesions. There is no evidence of regional mesenteric inflammation or fluid. The pancreatic duct measures 0.15 cm.

WEIGHT

7.5 Pounds

Free Abdomen

Evaluation of the peritoneal cavity did not reveal any evidence of effusion. There is a significant mesenteric lymphadenopathy present with lymph nodes measuring 0.63, 0.58, 0.59, and 0.74 cm, particularly in the area of the root of the mesentery. The Medial iliac nodes appear normal and there was no evidence of a caudal aortic thrombus at the bifurcation. The omentum is of slightly increased echogenicity in the cranial abdomen.

INTERPRETED BY

Kathleen Sennello DVM,
MS, Diplomate ACVIM
(Small Animal Internal
Medicine)

IMAGING PERFORMED BY

Loetitia Saint-Jacques, RVT

Other

A brief view of the heart was submitted. No significant pericardial effusion was seen.

HOSPITAL NAME

MountainView AH

PRIMARY FINDINGS

- Bilaterally hyperechoic kidneys with loss of corticomedullary distinction – Mild loss of corticomedullary distinction in both kidneys could be consistent with chronic degenerative disease or interstitial nephrosis.
- Mildly mottled spleen with hyper- and hypoechoic nodules visualized – The diffuse splenic changes are non-specific and could be consistent with lymphoid hyperplasia, extramedullary hematopoiesis, infiltrative neoplasia, inflammation, other. Cytology or histopathology would be necessary to get a definitive diagnosis.
- Mildly heterogeneous liver with a hypoechoic nodule visualized – The diffuse hepatic changes are non-specific and could be consistent with vacuolar hepatopathy, nodular hyperplasia, inflammatory/immune-mediated disease, fibrosis, extramedullary hematopoiesis, toxic hepatopathy (e.g., copper), infiltrative neoplasia (less likely) or other hepatopathy.

REFERRING VET

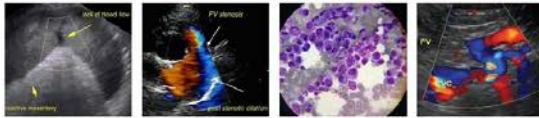
Dr. Sarah Kalivoda

INVOICE

26306

DATE

10/14/21



PATIENT

Samy Aeschilmann

- Hypoechoic, prominent pancreas – The pancreatic changes are most consistent with mild pancreatitis or a recent episode of pancreatic inflammation.

SPECIES

Feline

- Subjectively thickened small intestine – The mild small intestinal wall changes may be a normal variant in this patient or could be consistent with an inflammatory process (e.g., inflammatory bowel disease).

BREED

DLH

- Mild/moderate mesenteric lymphadenopathy – The prominent abdominal lymph nodes are most consistent with reactive lymphadenitis or lymphoid hyperplasia. Neoplastic infiltration is considered less likely.

SECONDARY FINDINGS

SEX

Neutered Male

- Borderline enlarged left adrenal – This adrenal gland appears normal in shape and appearance, but is on the large side of normal and should continue to be monitored.

INTERPRETATION OF THE FINDINGS & FURTHER RECOMMENDATIONS

AGE

16 Years

Many of the changes observed on today's scan are likely age related and consistent with chronic progressive changes such as the kidney changes. There are ill-defined nodules visualized in both the liver and spleen. Options moving forward include a fine needle aspirate of these areas or continued monitoring with ultrasound.

WEIGHT

7.5 Pounds

The bowel appears subjectively thickened, and there is a mesenteric lymphadenopathy present and a prominent pancreas. Based on the symptoms described, I suspect a malabsorptive enteropathy. This can occur with GI parasitism, mild pancreatitis, bacterial dysbiosis, food allergy, IBD, and less likely intestinal neoplasia. In older pets with more chronic symptoms, I would most strongly consider food allergy, IBD, intestinal neoplasia, and exocrine pancreatic insufficiency.

INTERPRETED BY

Kathleen Sennello DVM,
MS, Diplomate ACVIM
(Small Animal Internal
Medicine)

- Recommend a diet trial with a novel protein/hydrolyzed prescription diet.
- Recommend a GI panel to Texas A&M with a quantitative fPLi, TLI, cobalamin and folate level.
- Recommend 3-view thoracic radiographs to evaluate for concurrent intrathoracic disease.
- If symptoms are progressing, consider obtaining GI biopsies.

IMAGING PERFORMED BY

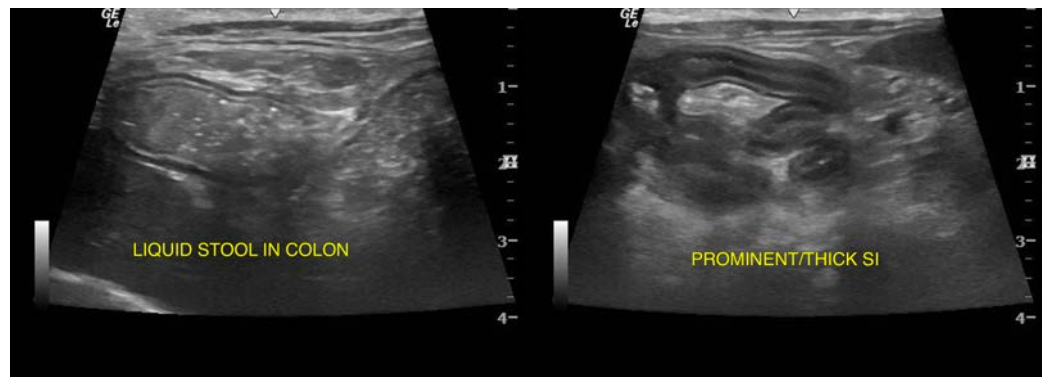
Loetitia Saint-Jacques, RVT

HOSPITAL NAME

MountainView AH

REFERRING VET

Dr. Sarah Kalivoda



INVOICE

26306

DATE

10/14/21



PATIENT

Samy Aeschilmann

SPECIES

Feline

BREED

DLH

SEX

Neutered Male

AGE

16 Years

WEIGHT

7.5 Pounds

INTERPRETED BY

Kathleen Sennello DVM,
MS, Diplomate ACVIM
(Small Animal Internal
Medicine)

IMAGING PERFORMED BY

Loetitia Saint-Jacques, RVT

HOSPITAL NAME

MountainView AH

REFERRING VET

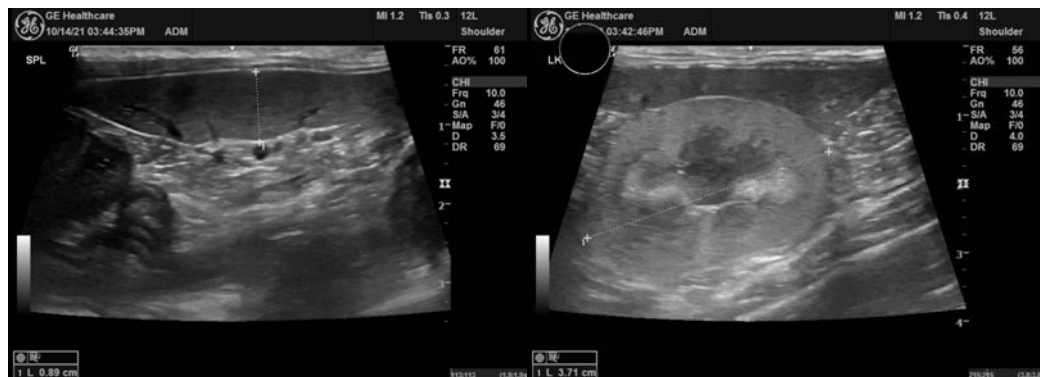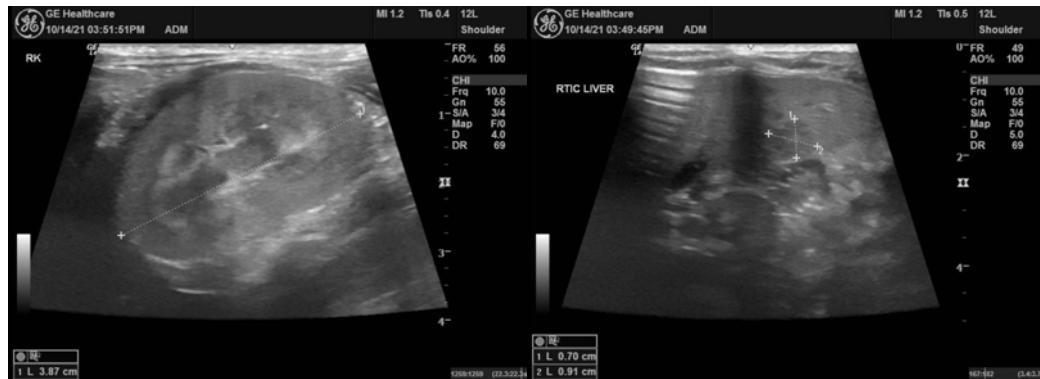
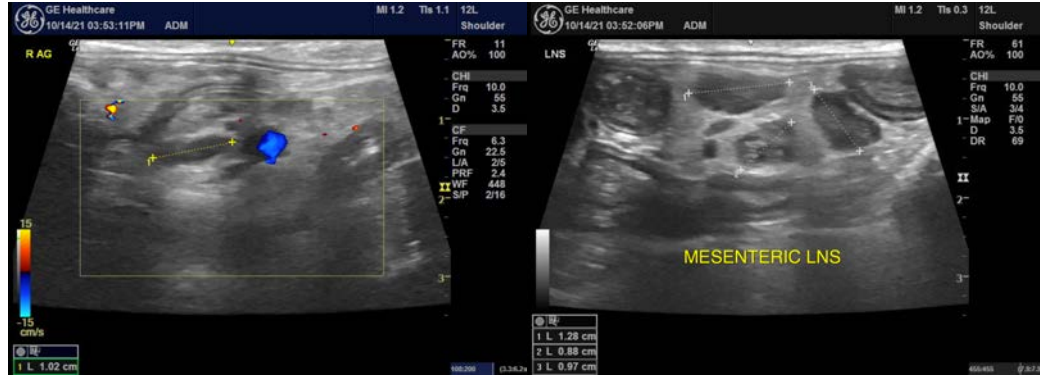
Dr. Sarah Kalivoda

INVOICE

26306

DATE

10/14/21



The information and recommendations provided are based on the images presented by the referring veterinarian. No evaluation can be communicated regarding pathology that was not visible in the image/video clips provided.

Thank you for this referral. If the clinical or image interpretation does not parallel your findings or if I can be of any further assistance please contact me.

Kathleen Sennello DVM,MS, Diplomate ACVIM (Small animal Internal Medicine)

kathleen.sennello@sonopath.com