

PATIENT

Dam Kanig

SPECIES

Canine

BREED

Border Collie Mix

SEX

Neutered male

AGE

9 years

WEIGHT

70 lbs

INTERPRETED BY

Kathleen Sennello
DVM, MS, Diplomate
ACVIM (Small Animal
Internal Medicine)

**IMAGING
PERFORMED BY**

.oetitia Saint-Jacques, RVT

PRESENTING CLINICAL SIGNS

Chief Concern / Provisional Diagnosis: ~r/o intrabdominal mass: adrenal vs splenic vs other. Suspected hyperadrenocorticism~ Relevant Medical History and Physical Exam findings: ~Patient presented on 10/9/21 for yearly exam and evaluation on excessive panting, increase thirst and urination. On physical examination noted tense abdomen and suspected intrabdominal mass in mid-ventral abdomen. Recommended blood work, urinalysis and abdominal ultrasound. Also recommended LDDS test.~ Recent Diagnostics: Relevant Laboratory Results / Abnormalities: ~ MCH 30.7 (21.9 - 26.1 pg) MCHC 40.8 (32.6 - 39.2 g/dL) Reticulocytes 120 (10 - 110 K/ μ L) BUN 33 (9 - 31 mg/dL) ALP 483 (5 - 160 U/L) Bilirubin - Conjugated 0.2 (0.0 - 0.1 mg/dL) Lipase 808 (0 - 250 U/L) Creatine Kinase 217 (10 - 200 U/L) Urine Protein: Creatinine Ratio 0.7 Current medications (include full name, dosage and frequency): ~none~ Abnormal PE/Chem/CBC/UA Results: sedation 0.1ml medetomidine/torb

ULTRASONOGRAPHIC EXAMINATION OF THE ABDOMEN

Urinary System

The urinary bladder is moderately distended with anechoic urine. The Bladder wall, trigone, ureteral papillae and visible urethra (to a depth of 2cm) appear normal with no evidence of wall thickening, mucosal irregularities, masses or cystic calculi.

The prostate is normal in size (1.06 cm) and shape for this neutered male dog. The parenchyma is homogenous and the external margins are smooth. The prostatic urethra appears normal with no evidence of irregularity, invasion, mass effect or calculi.

The left kidney has a normal shape and size (6.45 cm). Overall echogenicity is normal with adequate corticomedullary distinction and a typical 1:3 cortex:medulla ratio. There is no evidence of perinephric inflammation or effusion. Pinpoint, non-obstructive nephroliths were noted. There is no evidence of pyelectasia, infarcts or hydroureter. Renal vasculature is normal.

The right kidney has a normal shape and size (6.6 cm). Overall echogenicity is normal with adequate corticomedullary distinction and a typical 1:3 cortex:medulla ratio. There is no evidence of perinephric inflammation or effusion. Occasional, pinpoint, non-obstructive nephroliths were noted. There is no evidence of pyelectasia, infarcts or hydroureter. Renal vasculature is normal.

Adrenal Glands

The left adrenal gland is normal in size measuring 0.69 cm at the caudal pole It is observed in its normal position cranial to the left renal artery. It is normal in appearance (uniformly hypoechoic) and shape with no evidence of a mass effect.

The right adrenal gland is normal in size measuring 0.59 cm at the caudal pole It is observed in its normal position between the cranial aspect of the right kidney and the caudal vena cava. It is normal in appearance (uniformly hypoechoic) and shape with no evidence of a mass effect.

HOSPITAL NAME

MountainView AH

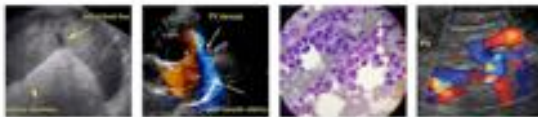
REFERRING VET

Dr. Mendoza

INVOICE

92408

DATE



PATIENT

Dam Kanig

SPECIES

Canine

BREED

Border Collie Mix

SEX

Neutered male

AGE

9 years

WEIGHT

70 lbs

INTERPRETED BY

Kathleen Sennello
DVM, MS, Diplomate
ACVIM (Small Animal
Internal Medicine)

**IMAGING
PERFORMED BY**

oetitia Saint-Jacques, RVT

HOSPITAL NAME

MountainView AH

REFERRING VET

Dr. Mendoza

INVOICE

92408

DATE

11/11/2014

Spleen

The spleen is subjectively normal in size, echotexture is homogenous, and the splenic capsule is smooth with no irregularities. The blood flow through the hilus and splenic parenchyma appears normal. No focal parenchymal abnormalities are visualized.

Liver

The liver is subjectively normal in size, and echogenicity with smooth peripheral margins. The parenchyma is heterogenous in echotexture with subtle, indistinct focal mottling. The visible portions of the vasculature and biliary tract appear normal. There is an ill-defined, hyperechoic nodule/mass effect visualized on the right side of the liver in the parenchyma and measured 2.73 x 3.99 cm. The gallbladder lumen is moderately distended. The wall of the gallbladder is not thickened and has a smooth mucosal surface. Luminal contents are primarily anechoic. The cystic and common bile ducts are normal/not visible.

Gastrointestinal

The stomach contains minimal luminal contents. It measures at a normal thickness of <0.7cm with some variability due to the presence of rugal folds. The distinction of the gastric wall layers is adequate and there is no impression of reduced peristaltic activity. No masses or focal lesions were observed.

The visualized areas of duodenum, jejunum and ileum have a relatively uniform diameter with minimal fluid distension. Wall thickness is normal. Bowel loops follow a curvilinear path with distinct wall layering maintaining the typical 1:3 muscularis:mucosa layer ratio. The duodenum measured as normal (between 0.3-0.5cm in wall thickness) and the jejunum measured as normal (between 0.2-0.47cm.) Visualized peristalsis appears appropriate. There were no focal lesions consistent with obstruction or a mass effect observed.

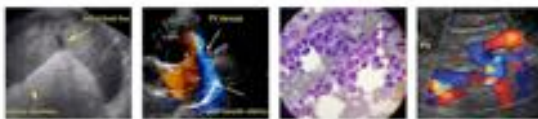
The ileocecal junction was visualized and exhibited normal intact wall layering and is subjectively of normal thickness. Sections of colon are visualized with formed fecal material and gas shadowing distally. There is no observed focal or generalized colon wall thickening or loss of layering.

Pancreas

The pancreas is normal and isoechoic to surrounding mesentery. There is no evidence of nodules or cystic lesions. There is no evidence of regional mesenteric inflammation or fluid.

Free Abdomen

Evaluation of the peritoneal cavity did not reveal any evidence of effusion, or subjective lymphadenomegaly. The Medial iliac nodes appear normal and there was no evidence of a caudal aortic thrombus at the bifurcation. The omentum is of normal uniform echogenicity.



PATIENT

Dam Kanig

SPECIES

Canine

BREED

Border Collie Mix

SEX

Neutered male

AGE

9 years

WEIGHT

70 lbs

INTERPRETED BY

Kathleen Sennello
DVM, MS, Diplomate
ACVIM (Small Animal
Internal Medicine)

IMAGING PERFORMED BY

.oetitia Saint-Jacques, RVT

HOSPITAL NAME

MountainView AH

REFERRING VET

Dr. Mendoza

INVOICE

92408

DATE

ULTRASONOGRAPHIC FINDINGS

PRIMARY FINDINGS:

- Heterogenous liver with ill-defined, hyperechoic nodule. The diffuse hepatic changes are non-specific and could be consistent with vacuolar hepatopathy, nodular hyperplasia, inflammatory/immune-mediated disease, fibrosis, extramedullary hematopoiesis, toxic hepatopathy (e.g., copper), infiltrative neoplasia (less likely) or other hepatopathy.

SECONDARY FINDINGS:

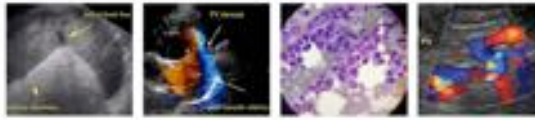
- Rare, pinpoint, non-obstructive nephroliths in the kidneys. The hyperechoic mineralized foci observed at the corticomedullary junction of the left/right kidney are consistent with small, non-obstructive nephroliths.

INTERPRETATION OF THE FINDINGS & FURTHER RECOMMENDATIONS

The changes observed were relatively mild. There is an ill-defined, hyperechoic nodule within the hepatic parenchyma. This could be benign or malignant, but its hyperechoic appearance favors a benign process. A FNA may be possible. I recommend to continue monitoring this lesion and the liver values.

An ALP elevation is a common finding. They tend to fall into 3 primary categories:

1. Biliary disease (this is unlikely based on ultrasound findings)
 2. Induction phenomena
 3. Primary liver disorders
- These are systemic illnesses that 'turn on' the liver enzyme. Causes of this include Cushing's disease, dental disease, arthritis, and numerous others. In many cases the exact cause is unclear but as long as ultrasound and bile acids tests are normal most patients do not have progressive changes in their liver. While liver biopsy is not routinely performed, vacuolar hepatopathy, is noted on most biopsies. This is often non-progressive but in rare cases can be more severe and lead to liver failure.
 - If signs of Cushing's disease are present recommend endocrine function testing to evaluate for Cushing's disease. The adrenal glands are not overtly enlarged, but this could still be consistent with Cushing's disease.
 - If a cause for the ALP elevation is not identified: I recommend recheck general blood work every 6 months, ultrasound once per year, and bile acids test every 1-2 years based on other results. If the ALP continues to climb a biopsy could be considered.
 - Consider long term use of Denamarin, and monitoring for the signs of Cushing's developing.
 - A primary vacuolar hepatopathy can be breed related and is seen in Scottish Terriers, Schnauzers, Cocker spaniels etc..



PATIENT

Dam Kanig

SPECIES

Canine

BREED

Border Collie Mix

SEX

Neutered male

AGE

9 years

WEIGHT

70 lbs

INTERPRETED BY

Kathleen Sennello
 DVM, MS, Diplomate
 ACVIM (Small Animal
 Internal Medicine)

IMAGING PERFORMED BY

Loetitia Saint-Jacques, RVT

HOSPITAL NAME

MountainView AH

REFERRING VET

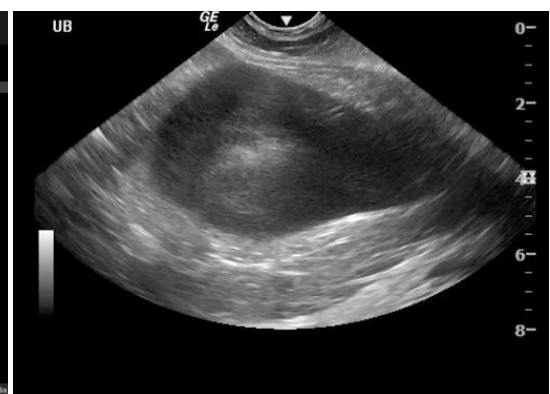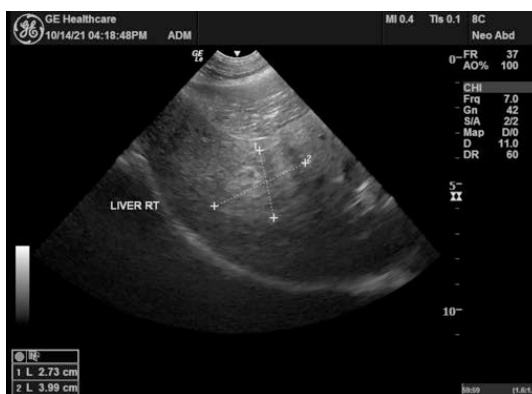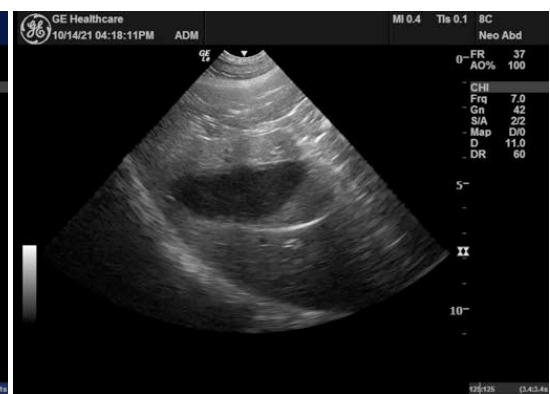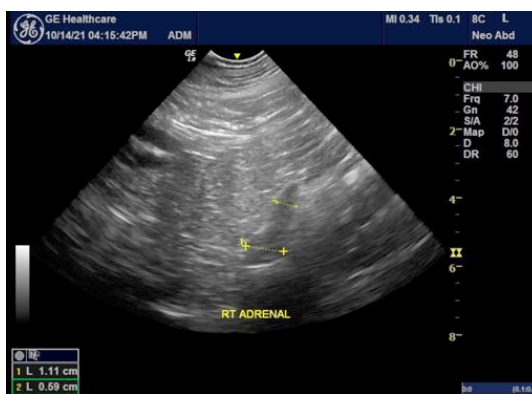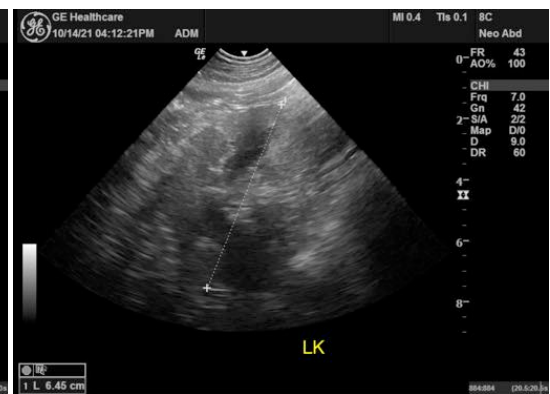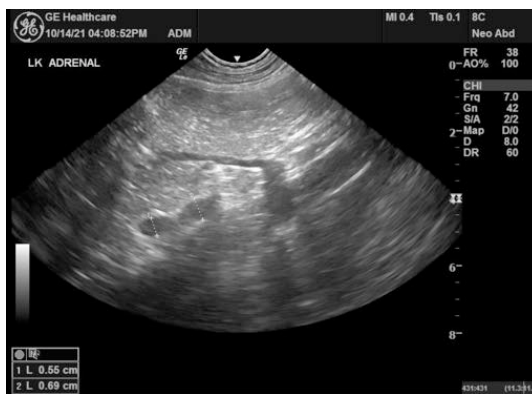Dr. Mendoza

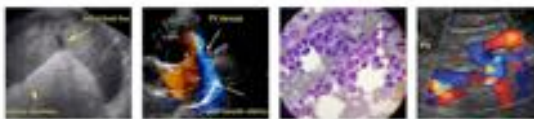
INVOICE

92408

DATE

10/14/21





PATIENT

Dam Kanig

SPECIES

Canine

BREED

Border Collie Mix

SEX

Neutered male

AGE

9 years

WEIGHT

70 lbs

INTERPRETED BY

Kathleen Sennello
DVM, MS, Diplomate
ACVIM (Small Animal
Internal Medicine)

**IMAGING
PERFORMED BY**

.oetitia Saint-Jacques, RVT

HOSPITAL NAME

MountainView AH

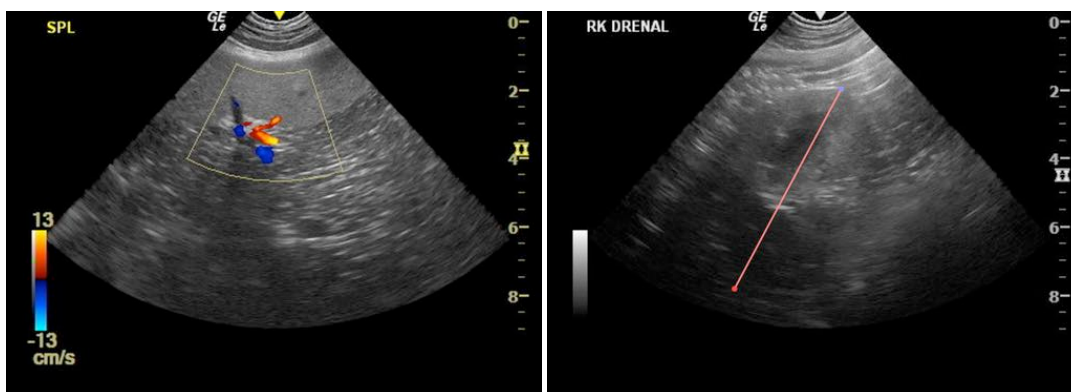
REFERRING VET

Dr. Mendoza

INVOICE

92408

DATE



The information and recommendations provided are based on the images presented by the referring veterinarian. No evaluation can be communicated regarding pathology that was not visible in the image/video clips provided.

Thank you for this referral. If the clinical or image interpretation does not parallel your findings or if I can be of any further assistance please contact me.

Kathleen Sennello DVM,MS, Diplomate ACVIM (Small animal Internal Medicine)
kathleen.sennello@sonopath.com