

**DATE PRESENTING CLINICAL SIGNS**

10/13/21

The patient has a history of chronic kidney disease (progressive), anemia (progressive), hyperthyroidism (well controlled), and hypertension. For the past 4-5 days, she has been lethargic and hiding more which is unusual. She continues to have a normal appetite. She has not had any significant vomiting, diarrhea, coughing, or sneezing. She has had some eye discharge and the other cat in the home has a upper respiratory infection. On physical exam 10/12, she was painful in her cranial abdomen and dehydrated. She has a gr II/VI heart murmur and mild generalized muscle loss. Her weight is stable from 7 months ago.

PATIENT

Lola Nusbaum

SPECIES

Feline

Current Medications: Amlodipine 0.625 mg PO BID (started Jan 2021), Felimazole 2.5 mg PO BID (started Jan 2021), Buprenex oral 0.15 mL TM BID-TID (started 10/12).

BREED

DSH

Lab Results: 10/12/21: CBC: WBC 21.57 (high), neut 16.91 (high), monocytes 1.33 (high), HCT 24.2 (non-regenerative); Chem: creat 2.4, BUN 38, phosph wnl; UA (cysto): USG 1.018; otherwise wnl; No T4 done but historically well controlled.

SEX

Spayed Female

Radiographs: Not provided by the veterinarian.
Date of Previous IntraPet Ultrasound: No previous IntraPet scans.
Sedation: Gabapentin 50 mg PO
Stat Report: not requested

ULTRASONOGRAPHIC EXAMINATION OF THE ABDOMEN**AGE**

7/2/04

Urinary System

The urinary bladder is moderately distended with anechoic urine. The Bladder wall, trigone, ureteral papillae and visible urethra (to a depth of 2cm) appear normal with no evidence of wall thickening, mucosal irregularities, masses or cystic calculi.

WEIGHT

7 Pounds

The left kidney has a normal shape and size (3.59 cm) with too numerous to count moderate sized cortical cysts, the largest measuring 1.35 cm. Overall echogenicity is slightly hyperechoic with poor corticomedullary distinction and a typical 1:3 cortex:medulla ratio. There is no evidence of perinephric inflammation or effusion. There is no evidence of pyelectasia, nephroliths, infarcts or hydroureter. Renal vasculature is normal.

INTERPRETED BY

Kathleen Sennello DVM,
MS, Diplomate ACVIM
(Small Animal Internal
Medicine)

The right kidney has a normal shape and size (3.54 cm) with too numerous to count cortical cysts. The largest cysts measured 1.2 and 0.97 cm. Overall echogenicity is slightly hyperechoic with poor corticomedullary distinction and a typical 1:3 cortex:medulla ratio. There is no evidence of perinephric inflammation or effusion. There is no evidence of pyelectasia, nephroliths, infarcts or hydroureter. Renal vasculature is normal.

HOSPITAL NAME

Paradise AH

Adrenal Glands**REFERRING VET**

Dr. Rieckert

The left adrenal gland is normal in size measuring 0.55 cm at the caudal pole. It is observed in its normal position cranial to the left renal artery. It is normal in appearance (uniformly hypoechoic) and shape with no evidence of a mass effect.

INVOICE

26245

The right adrenal gland is normal in size measuring 0.39 cm at the caudal pole. It is observed in its normal position between the cranial aspect of the right kidney and the caudal vena cava. It is normal in appearance (uniformly hypoechoic) and shape with no evidence of a mass effect.

Spleen

The spleen is subjectively normal in size, echotexture is homogenous, and the splenic capsule is smooth with no irregularities. The blood flow through the hilus and splenic parenchyma appears normal. No focal parenchymal abnormalities are visualized.

Liver

The liver is subjectively normal in size, and echogenicity with smooth peripheral margins. The parenchyma is heterogenous in echotexture with subtle, indistinct focal mottling. The visible portions of the vasculature and biliary tract appear normal. No focal nodules or cystic lesions are observed.

The gallbladder lumen is moderately distended. The wall of the gall bladder is not thickened and has a smooth mucosal surface. Luminal contents are primarily anechoic. The cystic and common bile ducts are normal/not visible.

Gastrointestinal

The stomach contains minimal luminal contents. It measures at a normal thickness of <0.36cm with some variability due to the presence of rugal folds. The distinction of the gastric wall layers is adequate and there is no impression of reduced peristaltic activity. No masses or focal lesions were observed.

The visualized areas of duodenum, jejunum and ileum have a uniform diameter with minimal fluid distension. Wall thickness is normal to slightly increased. Bowel loops follow a typical curvilinear path with distinct wall layering, but some areas display a prominent muscularis layer which does not display the typical 1:3 muscularis:mucosa layer ratio. Duodenum wall measured 0.37 cm. Jejunum wall measured 0.26 cm. Visualized peristalsis appears appropriate. There were no focal lesions consistent with obstruction or a mass effect observed.

The ileocecal junction was visualized and exhibited normal intact wall layering and is subjectively of normal thickness. Sections of colon are visualized with formed fecal material and gas shadowing distally. There is no observed focal or generalized colon wall thickening or loss of layering.

Pancreas

The pancreas is prominent and hypoechoic as compared to the surrounding isoechoic mesentery. There is no evidence of nodules or cystic lesions. Dilated pancreatic duct noted at 0.33 cm. There is no evidence of regional mesenteric inflammation or fluid.

Free Abdomen

Evaluation of the peritoneal cavity did not reveal any evidence of effusion. Mild mesenteric lymphadenopathy. Mesenteric lymph nodes around the ileocecal junction are prominent and measure 0.38 and 0.34 cm. The Medial iliac nodes appear normal and there was no evidence of a caudal aortic thrombus at the bifurcation. The omentum surrounding the ileocecal junction is hyperechoic.

PRIMARY FINDINGS

- Polycystic kidneys with decreased corticomedullary distinction – Mild loss of corticomedullary distinction in both kidneys could be consistent with chronic degenerative disease or interstitial nephrosis.
- Hypoechoic, prominent pancreas – The pancreatic changes are most consistent with mild pancreatitis or a recent episode of pancreatic inflammation.
- Heterogeneous liver – The diffuse hepatic changes are non-specific and could be consistent with vacuolar hepatopathy, nodular hyperplasia, inflammatory/immune-mediated disease, fibrosis, extramedullary hematopoiesis, toxic hepatopathy (e.g., copper), infiltrative neoplasia (less likely) or other hepatopathy.
- Prominent muscularis layer to the small intestine – The small intestinal wall changes are most consistent with an inflammatory process (i.e., inflammatory bowel disease) with a low possibility of emerging lymphoma.

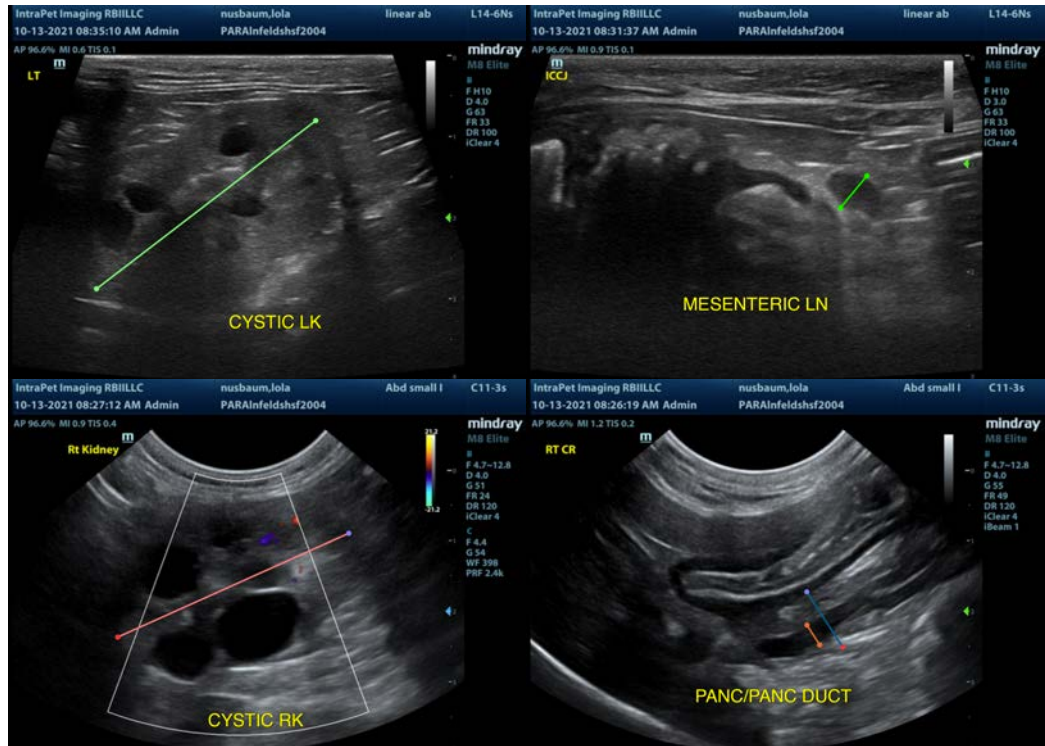
SECONDARY FINDINGS

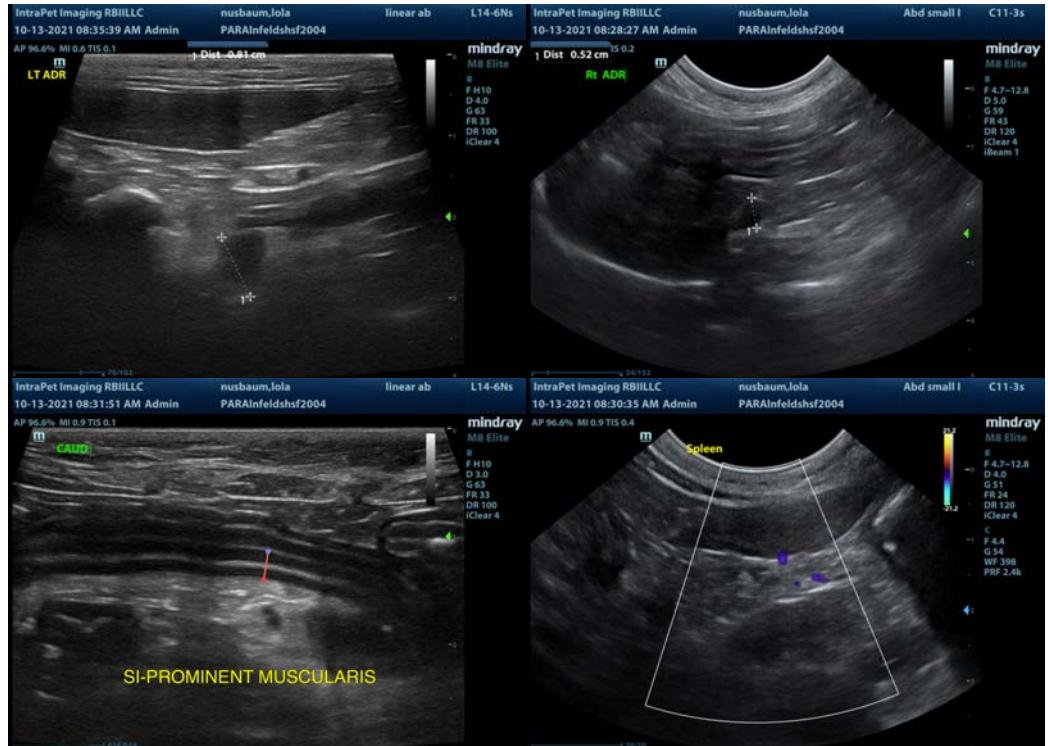
- Prominent mesenteric lymph nodes – The prominent abdominal lymph nodes are most consistent with reactive lymphadenitis or lymphoid hyperplasia. Neoplastic infiltration is considered less likely.

INTERPRETATION OF THE FINDINGS & FURTHER RECOMMENDATIONS

No large mass effects or focal lesions were observed. The kidneys are very cystic and changes are degenerative, consistent with progressive renal disease. Additionally, the pancreas is prominent, which could be associated with mild current inflammation or previous inflammation, and the muscularis layer is prominent. This can be a normal finding in older cats. If liver values are normal, then hepatic changes described are likely age related.

I suspect the anemia reported is secondary to renal disease. You could consider supplementation with Erythropoietin/Darbepoietin for the anemia. Additionally, recommend GI medications in case of ulceration, evaluation for hypertension, and a urinalysis and culture.





The information and recommendations provided are based on the images presented by the referring veterinarian. No evaluation can be communicated regarding pathology that was not visible in the image/video clips provided.

Thank you for this referral. If the clinical or image interpretation does not parallel your findings or if I can be of any further assistance please contact me.

Kathleen Sennello DVM,MS, Diplomate ACVIM (Small animal Internal Medicine)
 kathleen.sennello@sonopath.com