

**DATE PRESENTING CLINICAL SIGNS**

10/13/21

Weight loss, difficulty controlling hyperthyroidism (currently on 3.75 mg/day, has been on 7.5 mg/day and had to reduce dose because T4 was low). Inappetence. Elev. SDMA and BUN. Gradual increase in liver enzymes overtime that are not consistent with uncontrolled hyperthyroidism (or hepatopathy related to hyperthyroidism).

**PATIENT**

Cipriana Costa

**SPECIES**

Feline

**BREED**

Snowshoe

**SEX**

Spayed Female

**AGE**

3/8/05

**WEIGHT**

8.5 Pounds

**INTERPRETED BY**

Kathleen Sennello DVM,  
MS, Diplomate ACVIM  
(Small Animal Internal  
Medicine)

**HOSPITAL NAME**

Paradise AH

**REFERRING VET**

Dr. Twardzik

**INVOICE**

26244

Current Medications: methimazole 5 mg 3/4 T in a.m. and 1 T in p.m., Paroxetine 5 mg SID PO, Gabapentin 20 mg BID PO.

Lab Results: CBC: Elevated Monos 939 /uL. Chem: Elevated SDMA 16 ug/dL, Elevated BUN 38 mg/dL, Elevated Na<sup>+</sup> 163 mmol/L, Decreased Cl<sup>-</sup> 110 mmol/L, Increased TC02, anion gap, Increased ALT 677 U/L, Increased AST 303 U/L, Increased ALP 376 U/L, Increased T. Bili 0.8 mg/dL, Increased conj and unconj Bili, T4: Elevated at 8.2 ug/dL.

Radiographs: Not provided by the veterinarian.

Date of Previous IntraPet Ultrasound: No previous IntraPet scans.

Sedation: 50 mg of Gabapentin PO upon arrival.

Stat Report: not requested

**ULTRASONOGRAPHIC EXAMINATION OF THE ABDOMEN****Urinary System**

The urinary bladder is moderately distended with anechoic urine. The Bladder wall, trigone, ureteral papillae and visible urethra (to a depth of 2cm) appear normal with no evidence of wall thickening, mucosal irregularities, masses or cystic calculi.

The left kidney has a normal shape and size (3.04 cm). Overall echogenicity is slightly hyperechoic with poor corticomedullary distinction and a typical 1:3 cortex:medulla ratio. There is no evidence of perinephric inflammation or effusion. There is no evidence of pyelectasia, nephroliths, infarcts or hydroureter. Renal vasculature is normal.

The right kidney has a normal shape and size (3.41 cm). Overall echogenicity is slightly hyperechoic with poor corticomedullary distinction and a typical 1:3 cortex:medulla ratio. There is no evidence of perinephric inflammation or effusion. There is no evidence of pyelectasia, nephroliths, infarcts or hydroureter. Renal vasculature is normal.

**Adrenal Glands**

The left adrenal gland is normal in size measuring 0.50 cm at the caudal pole. It is observed in its normal position cranial to the left renal artery. It is normal in appearance (uniformly hypoechoic) and shape with no evidence of a mass effect.

The right adrenal gland is normal in size measuring 0.40 cm at the caudal pole. It is observed in its normal position between the cranial aspect of the right kidney and the caudal vena cava. It is normal in appearance (uniformly hypoechoic) and shape with no evidence of a mass effect.

**Spleen**

The spleen is subjectively normal in size, echotexture is homogenous, and the splenic capsule is smooth with no irregularities. The blood flow through the hilus and splenic parenchyma appears normal. No focal parenchymal abnormalities are visualized.

**Liver**

The liver is subjectively normal in size, and echogenicity with smooth peripheral margins. The parenchyma is heterogenous in echotexture with subtle, indistinct focal mottling. The visible portions of the vasculature and biliary tract appear normal. No focal nodules or cystic lesions are observed.

The gallbladder lumen is moderately distended. The wall of the gall bladder is not thickened and has a smooth mucosal surface. Luminal contents are primarily anechoic. The cystic and common bile ducts are normal/not visible.

### ***Gastrointestinal***

The stomach contains minimal luminal contents. It measures at a normal thickness of <0.36cm with some variability due to the presence of rugal folds. The distinction of the gastric wall layers is adequate and there is no impression of reduced peristaltic activity. No masses or focal lesions were observed.

The visualized areas of duodenum, jejunum and ileum have a uniform diameter with minimal fluid distension. Wall thickness is normal to slightly increased. Bowel loops follow a typical curvilinear path with distinct wall layering, but some areas display a prominent muscularis layer which does not display the typical 1:3 muscularis:mucosa layer ratio. Jejunum wall measures 0.24 cm. Visualized peristalsis appears appropriate. There were no focal lesions consistent with obstruction or a mass effect observed.

The ileocecal junction was visualized and exhibited normal intact wall layering and is subjectively of normal thickness. Sections of colon are visualized with formed fecal material and gas shadowing distally. There is no observed focal or generalized colon wall thickening or loss of layering.

### ***Pancreas***

The pancreas is large, prominent and hypoechoic with a very prominent dilated pancreatic duct at 0.45 cm. There is no evidence of nodules or cystic lesions. There is no evidence of regional mesenteric inflammation or fluid.

### ***Free Abdomen***

Evaluation of the peritoneal cavity did not reveal any evidence of effusion. A mild mesenteric lymphadenopathy is noted with mesenteric lymph nodes at 0.23, 0.42 cm. The Medial iliac nodes appear normal and there was no evidence of a caudal aortic thrombus at the bifurcation. The omentum is of normal uniform echogenicity.

## **ULTRASONOGRAPHIC FINDINGS**

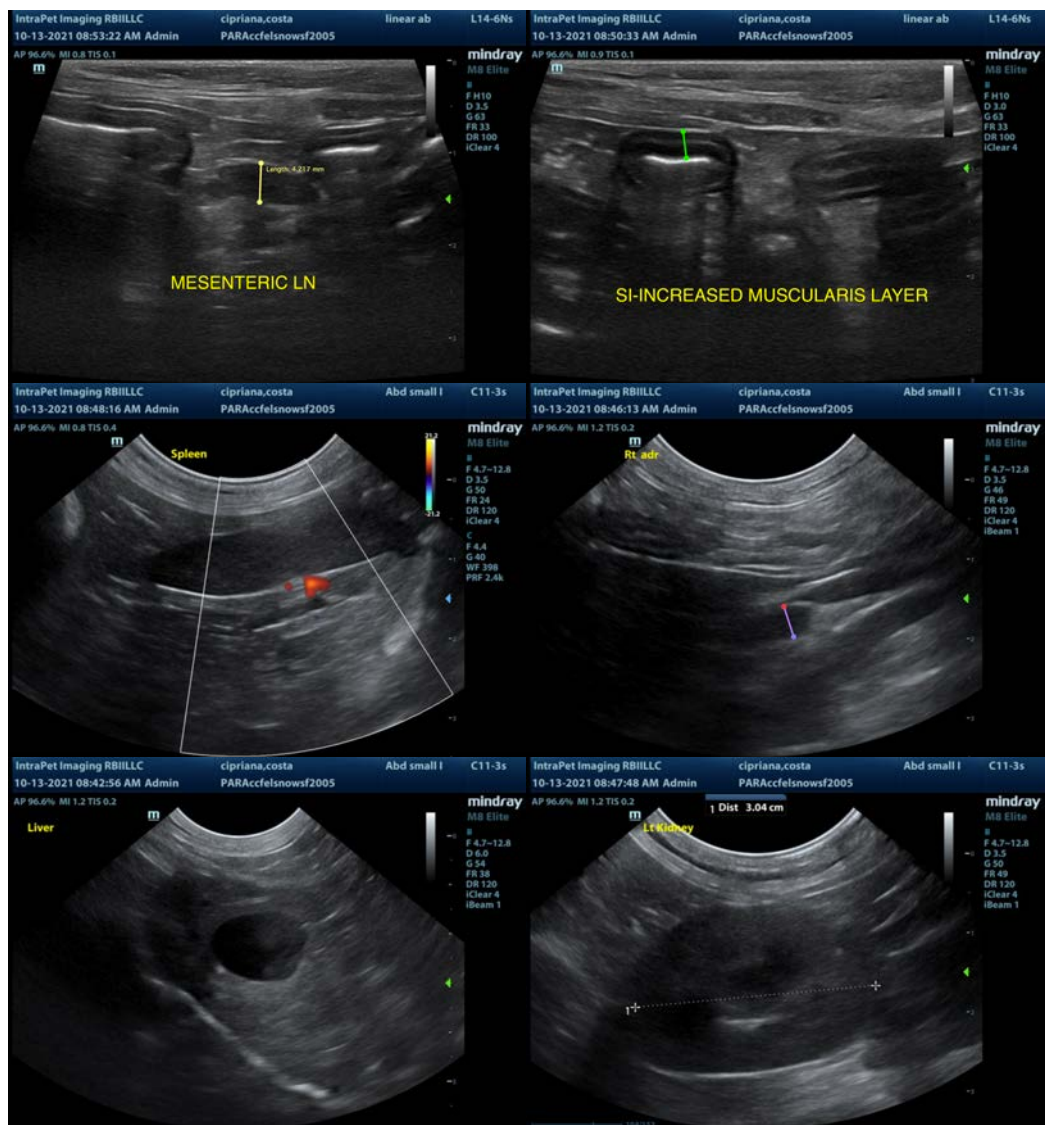
- Prominent, hypoechoic pancreas with dilated pancreatic duct – The pancreatic changes are most consistent with mild pancreatitis or a recent episode of pancreatic inflammation.
- Decreased corticomedullary distinction in both kidneys – The bilateral renal findings are consistent with age-related change.
- Prominent muscularis layer to the small intestine – The small intestinal wall changes are most consistent with an inflammatory process (i.e., inflammatory bowel disease) with a low possibility of emerging lymphoma.
- Heterogeneous liver – The diffuse hepatic changes are non-specific and could be consistent with vacuolar hepatopathy, nodular hyperplasia, inflammatory/immune-mediated disease, fibrosis, extramedullary hematopoiesis, toxic hepatopathy (e.g., copper), infiltrative neoplasia (less likely) or other hepatopathy.
- Mild mesenteric lymphadenopathy – The prominent abdominal lymph nodes are most consistent with reactive lymphadenitis or lymphoid hyperplasia. Neoplastic infiltration is considered less likely.

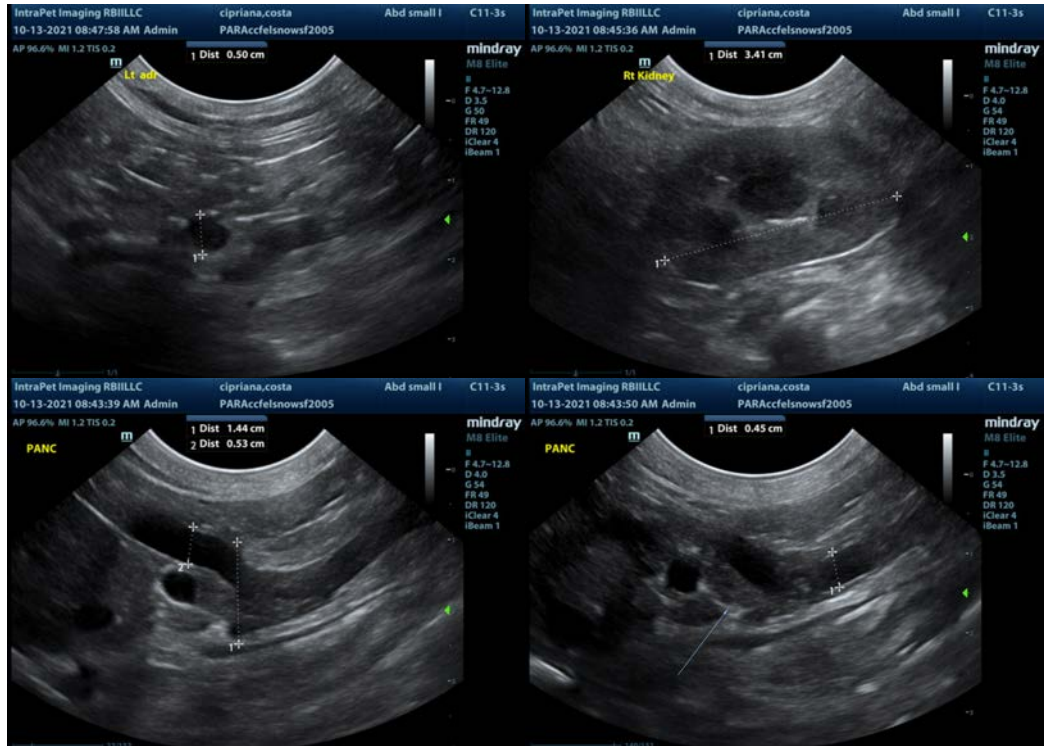
## **INTERPRETATION OF THE FINDINGS & FURTHER RECOMMENDATIONS**

The changes observed on today's scan were relatively non-specific. No focal lesions associated with the liver,

gallbladder or GI tract were noted. The liver changes are mild and consistent with a primary hepatopathy, as the biliary tract appears normal. Based on the history, of primary concern would be a Methimazole toxicity. Recommend cessation of Methimazole and I-131 therapy. Recommend a liver function test and a fine needle aspirate of the liver.

Additionally, the pancreas is prominent and the bowel appears somewhat irregular. These may be incidental findings or could be consistent with mild pancreatic inflammation and IBD type changes. Consider a GI panel to Texas A&M University with quantitative PLI, TLI, cobalamin and folate to further evaluate the pancreas and small intestine.





The information and recommendations provided are based on the images presented by the referring veterinarian. No evaluation can be communicated regarding pathology that was not visible in the image/video clips provided.

Thank you for this referral. If the clinical or image interpretation does not parallel your findings or if I can be of any further assistance please contact me.

Kathleen Sennello DVM,MS, Diplomate ACVIM (Small animal Internal Medicine)  
 kathleen.sennello@sonopath.com