

**DATE PRESENTING CLINICAL SIGNS**

10/13/21

History: ALP= 10X URI, ALT=1.5x URI, significant hepatomegaly, PU/PD, proteinuria. Suspect Cushing's disease will run LDDST simultaneously to U/S. Looking for more information on whether pituitary dependent or adrenal dependent/ adrenal tumor present.

PATIENT

Buster Shields

Current Medications: Not provided by the veterinarian.

Lab Results: ALP= 10X URI, ALT=1.5x, proteinuria.

Radiographs/Imaging: hepatomegaly.

Date of Previous IntraPet Ultrasound: 1-8-2020.

Sedation: not needed

Stat Report: not requested

SPECIES

Canine

BREED

Boxer X

SEX

Neutered Male

AGE

11/25/09

WEIGHT

61 Pounds

ULTRASONOGRAPHIC EXAMINATION OF THE ABDOMEN**Urinary System**

The urinary bladder is moderately distended with anechoic urine. The Bladder wall, trigone, ureteral papillae and visible urethra (to a depth of 2cm) appear normal with no evidence of wall thickening, mucosal irregularities, masses or cystic calculi.

The prostate is normal in size (0.92 cm) and shape for this neutered male dog. The parenchyma is homogenous and the external margins are smooth. The prostatic urethra appears normal with no evidence of irregularity, invasion, mass effect or calculi.

The left kidney has a normal shape and size (7.53 cm). Overall echogenicity is normal with adequate corticomedullary distinction and a typical 1:3 cortex:medulla ratio. There is no evidence of perinephric inflammation or effusion. There is no evidence of pyelectasia, nephroliths, infarcts or hydroureter. Renal vasculature is normal.

The right kidney has a normal shape and size (6.48 cm). Overall echogenicity is normal with adequate corticomedullary distinction and a typical 1:3 cortex:medulla ratio. There is no evidence of perinephric inflammation or effusion. There is no evidence of pyelectasia, nephroliths, infarcts or hydroureter. Renal vasculature is normal.

Adrenal Glands

The left adrenal gland is normal/borderline enlarged in size measuring 0.97 cm at the cranial pole, 1.16 cm at the caudal pole, and 3.61 cm in length. It is observed in its normal position cranial to the left renal artery. It is normal in appearance (uniformly hypoechoic) and shape with no evidence of a mass effect.

The right adrenal gland is normal/borderline enlarged in size measuring 0.81 cm at the caudal pole, 1.12 cm at the cranial pole, and 3.02 cm in length. It is observed in its normal position between the cranial aspect of the right kidney and the caudal vena cava. It is normal in appearance (uniformly hypoechoic) and shape with no evidence of a mass effect.

Spleen

The spleen is subjectively normal in size. The spleen echotexture is heterogenous and mottled, the splenic capsule is smooth with no irregularities. The blood flow through the hilus and splenic parenchyma appears normal. There is a hypoechoic nodule visualized in the parenchyma measuring 1.65 cm.

Liver

The liver is large in size, and normal in echogenicity with irregular margins. The parenchyma is heterogenous in echotexture with subtle, indistinct focal mottling. The visible portions of the vasculature and biliary tract

INTERPRETED BY

Kathleen Sennello DVM,
MS, Diplomate ACVIM
(Small Animal Internal
Medicine)

HOSPITAL NAME

Paradise AH

REFERRING VET

Dr. Halpern

INVOICE

26247

appear normal. The parenchyma is heterogeneous and diffusely nodular with numerous hypoechoic, ill-defined nodules varying in size from 0.25-1.0 cm.

The gallbladder lumen is moderately distended. The wall of the gall bladder is not thickened and has a smooth mucosal surface. Luminal contents are primarily anechoic. The cystic and common bile ducts are normal/not visible.

Gastrointestinal

The stomach contains minimal luminal contents. It measures at a normal thickness of <0.7cm with some variability due to the presence of rugal folds. The distinction of the gastric wall layers is adequate and there is no impression of reduced peristaltic activity. No masses or focal lesions were observed.

The visualized areas of duodenum, jejunum and ileum have a relatively uniform diameter with minimal fluid distension. Wall thickness is normal. Bowel loops follow a curvilinear path with distinct wall layering maintaining the typical 1:3 muscularis:mucosa layer ratio. Duodenum wall measured 0.44 cm. Jejunum wall measured 0.27 cm. Visualized peristalsis appears appropriate. There were no focal lesions consistent with obstruction or a mass effect observed.

The ileocecal junction was visualized and exhibited normal intact wall layering and is subjectively of normal thickness. Sections of colon are visualized with formed fecal material and gas shadowing distally. There is no observed focal or generalized colon wall thickening or loss of layering.

Pancreas

The pancreas is normal and isoechoic to surrounding mesentery. There is no evidence of nodules or cystic lesions. There is no evidence of regional mesenteric inflammation or fluid.

Free Abdomen

Evaluation of the peritoneal cavity did not reveal any evidence of effusion, or subjective lymphadenomegaly. The Medial iliac nodes appear normal and there was no evidence of a caudal aortic thrombus at the bifurcation. The omentum is of normal uniform echogenicity.

Other

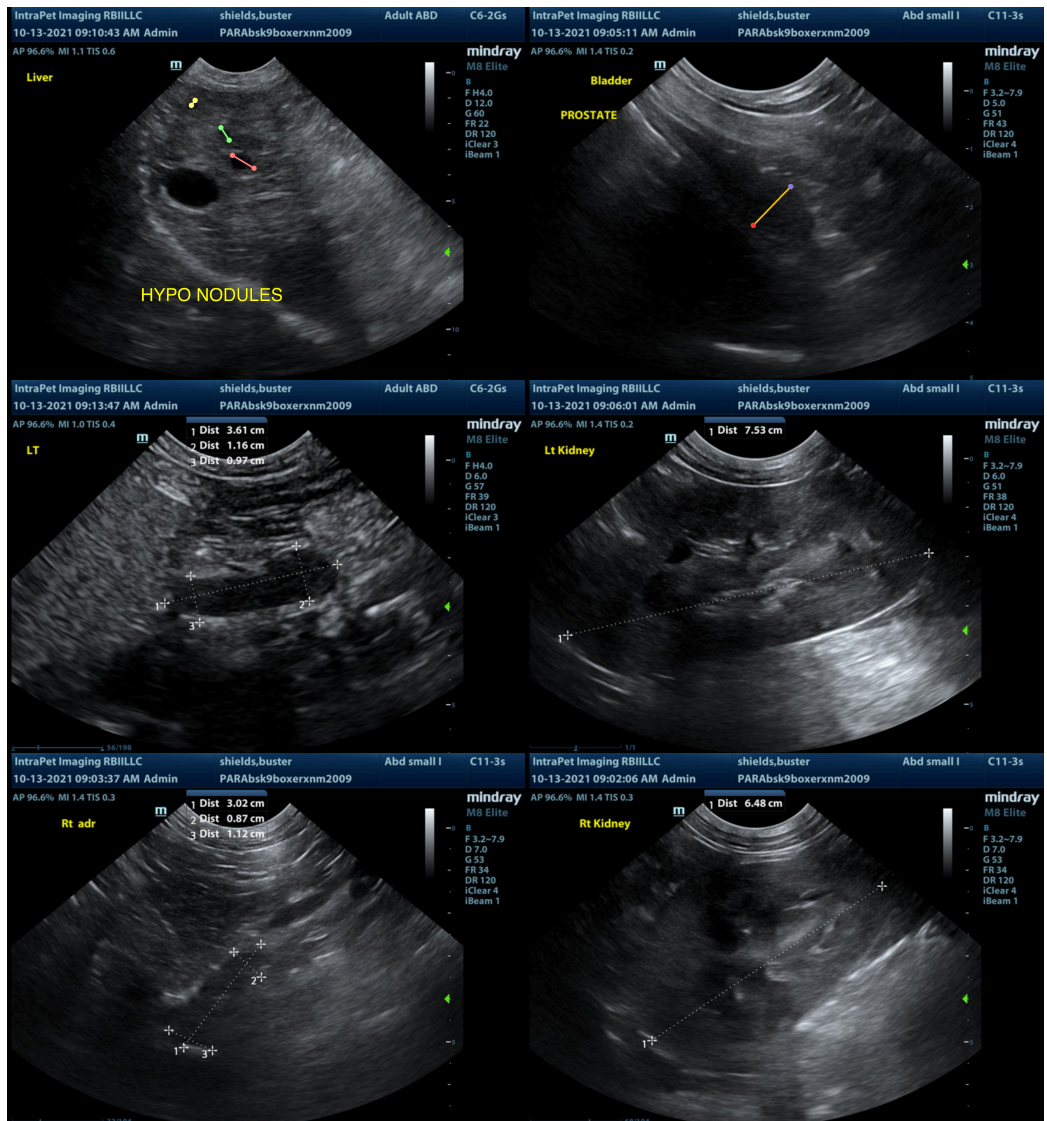
A brief view of the heart was submitted. No significant pericardial effusion was seen.

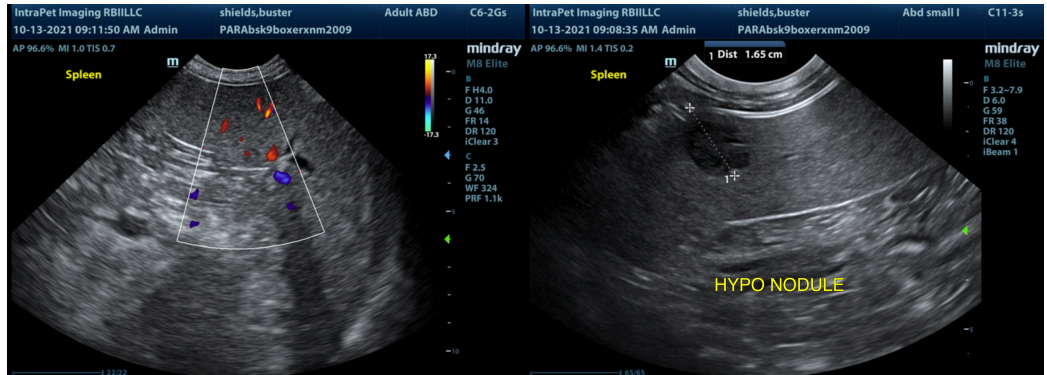
ULTRASONOGRAPHIC FINDINGS

- Borderline bilateral adrenal gland enlargement - The prominent adrenals could be consistent with bilateral hyperplasia (eg. Secondary to PDH), bilateral infiltrative neoplasia, inflammatory adrenal disease, other. Correlation with clinical findings is recommended.
- Mottled spleen with hypoechoic nodule – There is a non-cavitated, hypoechoic splenic nodule visualized. Differentials include lymphoid hyperplasia, extramedullary hematopoiesis, infiltrative neoplasia, inflammation, other. Cytology or histopathology would be necessary to get a definitive diagnosis. Previous measurement (on 1/8/20) of this lesion was 1.35 cm, so it has gotten slightly larger.
- Large, heterogeneous, nodular liver – The diffuse hepatic changes are non-specific and could be consistent with vacuolar hepatopathy, nodular hyperplasia, inflammatory/immune-mediated disease, fibrosis, extramedullary hematopoiesis, toxic hepatopathy (e.g., copper), infiltrative neoplasia (less likely) or other hepatopathy. The liver description is similar to the previous scan.

INTERPRETATION OF THE FINDINGS & FURTHER RECOMMENDATIONS

This patient had an ultrasound on 1/8/20 and primary findings were borderline adrenal enlargement and an irregular, nodular liver along with a splenic nodule. Today's scan identifies more definitively prominent adrenals (most consistent with PDH), a heterogenous liver with ill-defined nodules (which I suspect is a vacuolar hepatopathy), and a persistent splenic nodule that is slightly larger than it was on the previous scan. Slow growth favors a benign process. Recommend adrenal function testing, blood pressure evaluation, and continued monitoring of the splenic nodule.





The information and recommendations provided are based on the images presented by the referring veterinarian. No evaluation can be communicated regarding pathology that was not visible in the image/video clips provided.

Thank you for this referral. If the clinical or image interpretation does not parallel your findings or if I can be of any further assistance please contact me.

Kathleen Sennello DVM,MS, Diplomate ACVIM (Small animal Internal Medicine)
kathleen.sennello@sonopath.com