



PATIENT

Cody Isaacson

SPECIES

Canine

BREED

Sheltie X

SEX

Neutered Male

AGE

13 Years

WEIGHT

45 Pounds

INTERPRETED BY

Kathleen Sennello DVM,
MS, Diplomate ACVIM
(Small Animal Internal
Medicine)

**IMAGING
PERFORMED BY**

Jack Reese

HOSPITAL NAME

Willow Run VC

REFERRING VET

Dr. Molly Arnold

INVOICE

42011

DATE

10/12/22

PRESENTING CLINICAL SIGNS

6 month history of persistent diarrhea starting in May 2022. Started on z/d diet with addition of Tylan powder, metronidazole, probiotics (Provable). Compliance with diet and medications has been sporadic - symptoms improve, but owner reports signs recur frequently. Recommended ultrasound as next step diagnostic.

Abnormal PE/Chem/CBC/UA Results: April 2022 ALP 533 (5 - 160 U/L) SDMA 15 (0 - 14 µg/dL) April 2022 >24.0 (4.8 - 19.0 ug/L) Maldigestion panel otherwise unremarkable May 2022 Fecal negative

ULTRASONOGRAPHIC EXAMINATION OF THE ABDOMEN

Urinary System

The urinary bladder is moderately distended with anechoic urine. The Bladder wall appears normal in thickness with a smooth mucosal surface. The area of the proximal urethra appears free of any mass lesions or calculi. There is a circular, fluid-filled structure at the level of the ureteral papilla, which I suspect is a small distal ureterocele measuring 0.56 cm. No distinct mass lesion is visualized, but continued monitoring of this area is warranted.

The visualized areas of prostate and surrounding tissue appear normal. Unfortunately, the prostate is not fully visualized likely due to its intrapelvic location. Correlate with rectal exam findings.

The left kidney has a normal shape and size (5.41 cm). Overall echogenicity is slightly hyperechoic with poor corticomedullary distinction and a typical 1:3 cortex:medulla ratio. There is no evidence of focal perinephric inflammation or effusion. There is no evidence of pyelectasia, nephroliths, infarcts or hydroureter. Renal vasculature is normal.

The right kidney has a normal shape and size (6.68 cm). Overall echogenicity is slightly hyperechoic with poor corticomedullary distinction and a typical 1:3 cortex:medulla ratio. There is no evidence of focal perinephric inflammation or effusion. There is no evidence of pyelectasia, nephroliths, infarcts or hydroureter. Renal vasculature is normal.

Adrenal Glands

The left adrenal gland is normal in size measuring 0.63 cm at the caudal pole. It is observed in its normal position cranial to the left renal artery. It is normal in appearance (uniformly hypoechoic) and shape with no evidence of a mass effect.

The region of the right adrenal (between right cranial kidney and vena cava) is unremarkable, but the adrenal is not distinctly visualized. No evidence of a mass effect.

Spleen

The spleen is subjectively normal in size, echotexture is homogenous, and the splenic capsule is smooth with no irregularities. The blood flow through the hilus and splenic parenchyma appears normal. There is a small hypoechoic nodule visualized within the parenchyma, measuring 0.49 cm.

Liver

The liver is mildly increased in size, and normal in echogenicity with smooth peripheral margins. The parenchyma is heterogenous in echotexture with subtle, indistinct focal mottling. The visible portions of the vasculature and biliary tract appear normal. No focal nodules or cystic lesions are observed.



PATIENT

Cody Isaacson

The gallbladder lumen is moderately distended. The wall of the gall bladder is not thickened and has a smooth mucosal surface. Luminal contents are mild and primarily anechoic. The cystic and common bile ducts are normal/not visible.

SPECIES

Canine

Gastrointestinal

The stomach is moderately distended with air, fluid, and ingesta. It measures at a normal thickness of <0.7cm with some variability due to the presence of rugal folds. The distinction of the gastric wall layers is adequate and there is no impression of reduced peristaltic activity. No masses or focal lesions were observed.

BREED

Sheltie X

The visualized areas of duodenum, jejunum and ileum have a uniform diameter with minimal fluid distension. Wall thickness is moderately increased. Bowel loops follow a typical curvilinear path. Some areas have reduced detail of wall layering. Duodenum wall measures 0.44 cm. Jejunum wall measures 0.31 cm. Visualized peristalsis appears appropriate. While no focal lesions are visualized, there is mild mucosal speckling visualized associated with the duodenum.

SEX

Neutered Male

The ileocecal junction was visualized and exhibited normal intact wall layering and is subjectively of normal thickness. Sections of colon are visualized with formed fecal material and gas shadowing distally. There is no observed focal or generalized colon wall thickening or loss of layering.

AGE

13 Years

Pancreas

The area of the pancreas is normal and isoechoic to surrounding mesentery. There is no evidence of nodules or cystic lesions. There is no evidence of regional mesenteric inflammation or fluid.

WEIGHT

45 Pounds

Free Abdomen

Evaluation of the peritoneal cavity did not reveal any evidence of effusion, or subjective lymphadenomegaly. The Medial iliac nodes appear normal and there was no evidence of a caudal aortic thrombus at the bifurcation. The omentum is of normal uniform echogenicity.

INTERPRETED BY

Kathleen Sennello DVM,
MS, Diplomate ACVIM
(Small Animal Internal
Medicine)

ULTRASONOGRAPHIC FINDINGS

- Small circular, fluid-filled dilation at the level of the ureteral papilla – most consistent with a distal ureterocele but continued monitoring of this area is warranted.
- Small hypoechoic nodule in the spleen – There is a non-cavitated, hypoechoic splenic nodule visualized. Differentials include lymphoid hyperplasia, extramedullary hematopoiesis, infiltrative neoplasia, inflammation, other. Cytology or histopathology would be necessary to get a definitive diagnosis.
- Decreased corticomedullary distinction in both kidneys – The bilateral renal findings are consistent with age-related change.
- Mildly enlarged, heterogeneous liver – The diffuse hepatic changes are non-specific and could be consistent with vacuolar hepatopathy, nodular hyperplasia, inflammatory/immune-mediated disease, fibrosis, extramedullary hematopoiesis, toxic hepatopathy (e.g., copper), infiltrative neoplasia (less likely) or other hepatopathy.
- Mild mucosal speckling of the duodenum – Bright mucosal speckling has been postulated to represent dilated lacteals or focal accumulations of mucus, cellular debris, etc.. in the mucosal crypts.

IMAGING PERFORMED BY

Jack Reese

HOSPITAL NAME

Willow Run VC

REFERRING VET

Dr. Molly Arnold

INVOICE

42011

DATE

10/12/22



PATIENT

Cody Isaacson

SPECIES

Canine

BREED

Sheltie X

SEX

Neutered Male

AGE

13 Years

WEIGHT

45 Pounds

INTERPRETED BY

Kathleen Sennello DVM,
MS, Diplomate ACVIM
(Small Animal Internal
Medicine)

IMAGING PERFORMED BY

Jack Reese

HOSPITAL NAME

Willow Run VC

REFERRING VET

Dr. Molly Arnold

INVOICE

42011

DATE

10/12/22

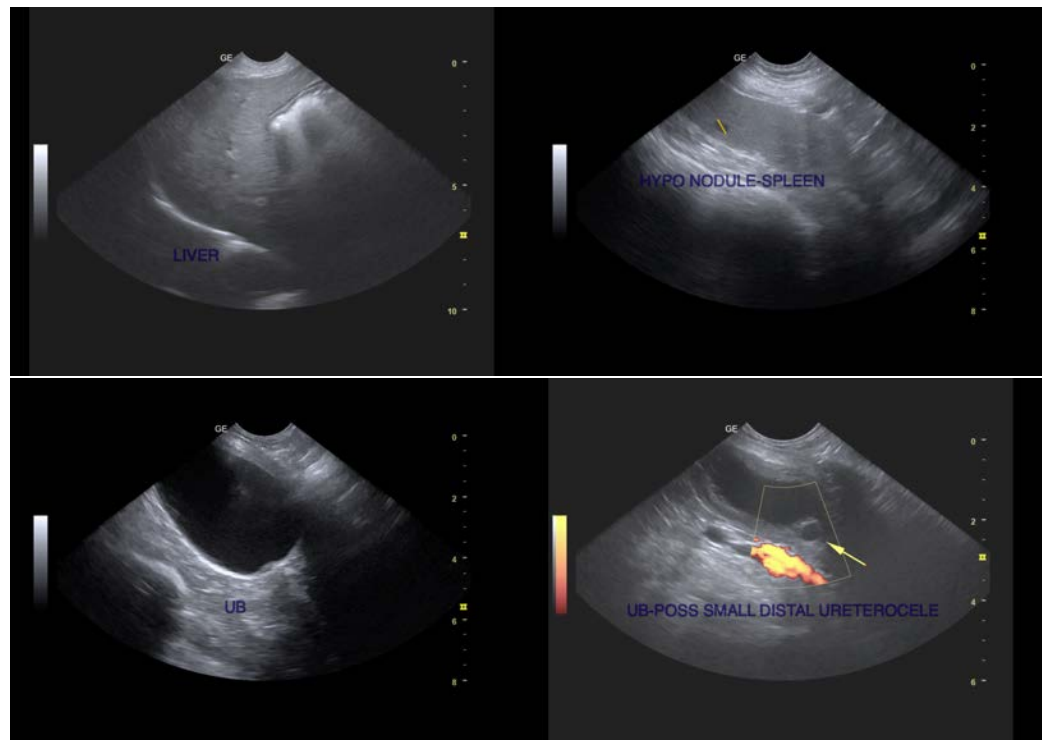
INTERPRETATION OF THE FINDINGS & FURTHER RECOMMENDATIONS

There is a small fluid-filled dilation at the level of the ureteral papilla that appears most consistent with a distal ureterocele. This could be an incidental finding. Recommend a urinalysis and culture and continued monitoring of this area, as I cannot rule out the possibility of a small amount of abnormal tissue in this area/small mass effect, which could be causing a mild obstructive effect. This is not visualized clearly but cannot be definitively ruled out.

There is a small hypoechoic splenic nodule visualized within the parenchyma. This does not deviate the splenic capsule. I suspect it would be challenging to aspirate at this size. Consider continued monitoring.

The liver is mildly enlarged and heterogeneous. This is a non-specific finding, which could correlate with the elevation in ALP reported. This could be somewhat reactive secondary to the GI disease or be a primary hepatopathy. No focal lesions are observed. Recommend a liver function test +/- a fine needle aspirate.

No focal lesions are visualized associated with the gastrointestinal tract. The duodenum has a small amount of mucosal speckling, which can be observed with primary GI disease. Your initial plan with this patient is a good one. I would try to get the owner on board with chronic/lifelong probiotics, and strict adherence to a hydrolyzed diet. I would steer way from long-term Metronidazole use if possible, and you could consider rechecking maldigestion panel, as it has been approximately 6 months, and a drop in B12 could indicate progression of this process. I recommend the GI panel to Texas A&M GI Lab, measuring a PLI, TLI, cobalamin and folate. If symptoms are persisting, recommend obtaining GI biopsies. If you strongly suspect dysbiosis, a fecal transplant is a relatively easy procedure to pursue.





PATIENT

Cody Isaacson

SPECIES

Canine

BREED

Sheltie X

SEX

Neutered Male

AGE

13 Years

WEIGHT

45 Pounds

INTERPRETED BY

Kathleen Sennello DVM,
MS, Diplomate ACVIM
(Small Animal Internal
Medicine)

**IMAGING
PERFORMED BY**

Jack Reese

HOSPITAL NAME

Willow Run VC

REFERRING VET

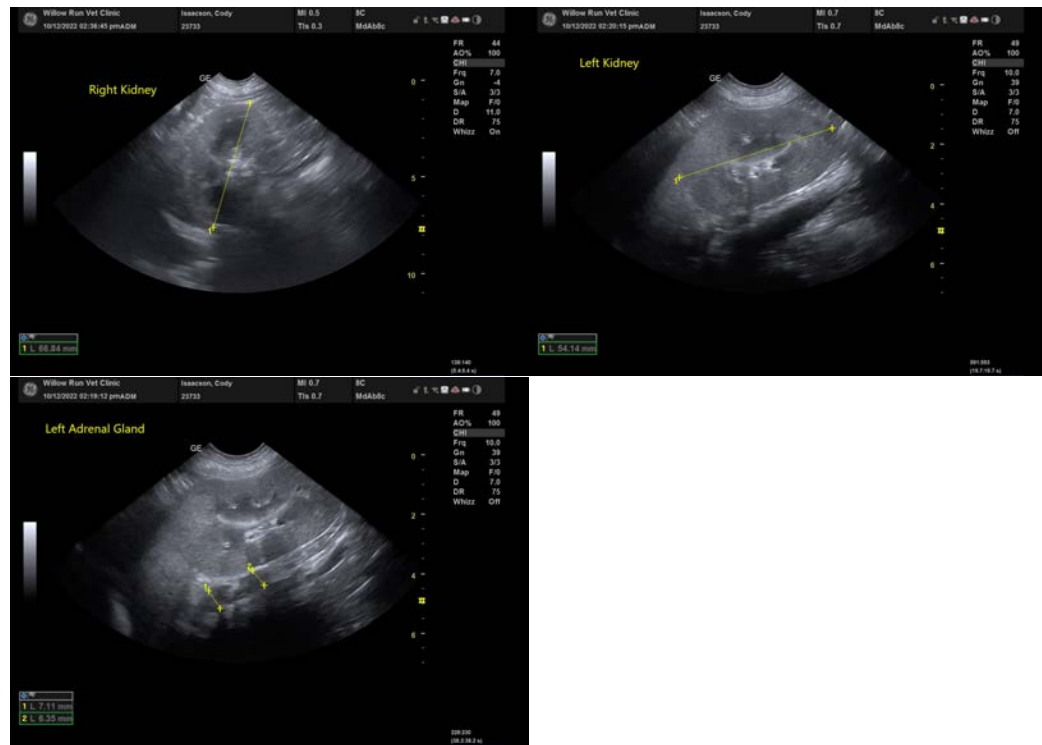
Dr. Molly Arnold

INVOICE

42011

DATE

10/12/22



The information and recommendations provided are based on the images presented by the referring veterinarian/sonographer. No evaluation can be communicated regarding pathology that was not visible in the image/video clips provided.

Thank you for this referral. If the clinical or image interpretation does not parallel your findings or if I can be of any further assistance please contact me.

Kathleen Sennello DVM,MS, Diplomate ACVIM (Small animal Internal Medicine)

kathleen.sennello@sonopath.com