

**DATE PRESENTING CLINICAL SIGNS**

10/12/22

History of IBD primarily characterized by anorexia, weight loss, intermittent diarrhea. Minimal response to prednisone, on cyclosporine for ~5 weeks (initially once daily, increased to BID then started giving on empty stomach, on BID on empty stomach for 2 weeks). Past 24 hours lethargic, not eating. PE-- weight gain but remains thin/muscle wasted, mm pink on L side of mouth, pale pink on R (owner reports this has been noted before). Otherwise normal PE.

**PATIENT**

Cheddar Fedder

**SPECIES**

Canine

**BREED**

Border Collie X

**SEX**

Intact Male

**AGE**

6/15/21

**WEIGHT**

14.5 kg

**INTERPRETED BY**

Kathleen Sennello DVM,  
MS, Diplomate ACVIM  
(Small Animal Internal  
Medicine)

**IMAGING PERFORMED BY**

Andi Parkinson RDMS

**HOSPITAL NAME**

Nexus Vet Specialists

**REFERRING VET**

Dr. Steele

**INVOICE**

42009

Current Medications: Cerenia 30mg once daily, Prednisone 20mg/day  
Cyclosporine 25mg BID, Omeprazole 10mg BID, Metoclopramide 5mg BID, Visbiome once daily, Folic acid 200mcg once daily, Mirtazapine 15mg once daily PRN, Sileo or clonidine for car rides (sileo this morning)  
Lab Results: Labs pending today, prior labs unremarkable excepting low folate  
Date of Previous IntraPet Ultrasound: No previous.  
Sedation: Not required to complete full diagnostic ultrasound.  
Stat Report: Not requested.

**ULTRASONOGRAPHIC EXAMINATION OF THE ABDOMEN****Urinary System**

The urinary bladder is moderately distended with anechoic urine. The Bladder wall, trigone, ureteral papillae and visible urethra (to a depth of 2cm) appear normal with no evidence of wall thickening, mucosal irregularities, masses or cystic calculi.

The prostate is large in size (2.14 cm in height in the sagittal view) but has a regular shape with smooth external margins. The parenchyma is heterogenous but no discrete focal lesions are present. The prostatic urethra appears normal with no evidence of irregularity, invasion, mass effect or calculi.

The left kidney has a normal shape and size (5.95 cm). Overall echogenicity is normal with adequate corticomedullary distinction and a typical 1:3 cortex:medulla ratio. There is no evidence of focal perinephric inflammation or effusion. There is no evidence of pyelectasia, nephroliths, infarcts or hydroureter. Renal vasculature is normal.

The right kidney has a normal shape and size (6.,36 cm). Overall echogenicity is normal with adequate corticomedullary distinction and a typical 1:3 cortex:medulla ratio. There is no evidence of focal perinephric inflammation or effusion. There is no evidence of pyelectasia, nephroliths, infarcts or hydroureter. Renal vasculature is normal.

**Adrenal Glands**

The left adrenal gland is borderline small measuring 0.34 cm at the caudal pole. It is observed in its normal position cranial to the left renal artery. It is normal in appearance (uniformly hypoechoic) and shape with no evidence of a mass effect.

The region of the right adrenal (between right cranial kidney and vena cava) is unremarkable, but the adrenal is not distinctly visualized. No evidence of a mass effect.

**Spleen**

The spleen is subjectively normal in size, echotexture is homogenous, and the splenic capsule is smooth with no irregularities. The blood flow through the hilus and splenic parenchyma appears normal. No focal parenchymal abnormalities are visualized.

### **Liver**

The liver is large with smooth peripheral margins. The parenchyma is hyperechoic and homogenous in echotexture. The visible portions of the vasculature and biliary tract appear normal. No focal nodules or cystic lesions are observed.

The gallbladder lumen is moderately distended. The wall of the gall bladder is not thickened and has a smooth mucosal surface. Luminal contents are mild and primarily anechoic. The cystic and common bile ducts are normal/not visible.

### **Gastrointestinal**

The stomach is moderately dilated with fluid and irregular shadowing material most consistent with normal ingesta and gas. It measures at a normal thickness of <0.7cm with some variability due to the presence of rugal folds. The distinction of the gastric wall layering is adequate and there is no impression of reduced peristaltic activity. No masses or focal lesions were observed.

The visualized areas of duodenum, jejunum and ileum have a relatively uniform diameter with mild to moderate fluid distension. Wall thickness is normal. Bowel loops follow a curvilinear path with distinct wall layering maintaining the typical 1:3 muscularis:mucosa layer ratio. Jejunum wall measures 0.25 cm. There were no focal lesions consistent with obstruction or a mass effect observed.

The ileocecal junction was visualized and exhibited normal intact wall layering and is subjectively of normal thickness. Sections of colon are visualized with formed fecal material and gas shadowing distally. There is no observed focal or generalized colon wall thickening or loss of layering.

### **Pancreas**

The pancreas is normal and isoechoic to surrounding mesentery. There is no evidence of nodules or cystic lesions. There is no evidence of regional mesenteric inflammation or fluid.

### **Free Abdomen**

Evaluation of the peritoneal cavity did not reveal any evidence of effusion, or subjective lymphadenomegaly. The Medial iliac nodes appear normal and there was no evidence of a caudal aortic thrombus at the bifurcation. The omentum is of normal uniform echogenicity.

### **Other**

Both testicles are imaged and appear within normal limits.

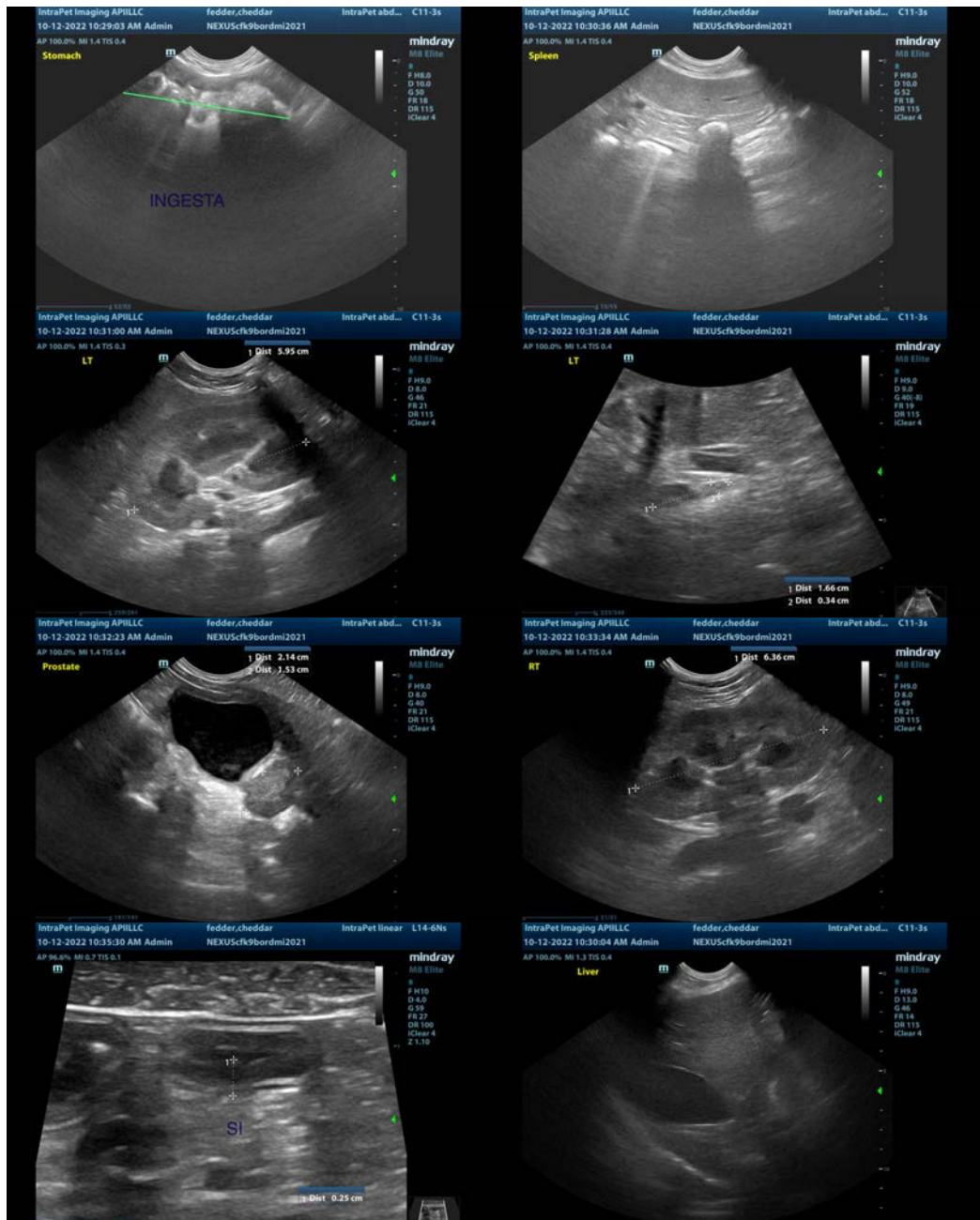
## **ULTRASONOGRAPHIC FINDINGS**

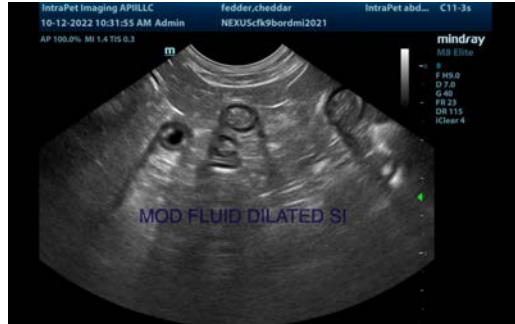- Borderline small adrenal glands – This could represent atrophy due to chronic steroid use.
- Large, hyperechoic liver – The diffuse hepatic changes are non-specific and can be seen with vacuolar hepatopathy, reactive change, nodular hyperplasia or, less likely, inflammatory/immune-mediated disease, infiltrative neoplasia, or other hepatopathy. This could be consistent with a steroid hepatopathy.
- Moderate shadowing ingesta within the gastric lumen – Correlate with the feeding history and abdominal radiographs. If the patient was adequately fasted consider such differentials as delayed gastric emptying, a partial outflow tract obstruction (none seen) or ingested foreign material.
- Moderate diffuse fluid dilation of the small intestine – Findings could be consistent with generalized ileus.
- Large prostate – This is normal for an intact male.

## INTERPRETATION OF THE FINDINGS & FURTHER RECOMMENDATIONS

Ultrasonographic findings include borderline small adrenal glands, a large prostate, a large, hyperechoic liver, and a stomach and small intestine distended with fluid/ingesta/chyme despite being fasted for the procedure.

Further diagnostic and therapeutic recommendations regarding this exam to be made by Dr. Cara Steele.





**The information and recommendations provided are based on the images presented by the referring veterinarian/sonographer. No evaluation can be communicated regarding pathology that was not visible in the image/video clips provided.**

Thank you for this referral. If the clinical or image interpretation does not parallel your findings or if I can be of any further assistance please contact me.

Kathleen Sennello DVM,MS, Diplomate ACVIM (Small animal Internal Medicine)  
kathleen.sennello@sonopath.com