

**DATE PRESENTING CLINICAL SIGNS**

10/12/21

History: **Presenting Complaint:** Vomiting; Diarrhea; Weak. **Date:** 10-12-2021 **Notes:** Has had major diarrhea for 7 days - owner has been giving medications: Kaopectate, Metronidazole, Sucralfate with no improvement - has not been given meds in 24 hrs. Vomiting for three days. No blood in vomit or diarrhea. Seems interested in food but won't eat; last night ate some chix and rice but vomited afterwards - off regular food for 7 days, off chix and rice yesterday with decreased interest starting the day before. Seems to have lost weight - noted to be around 12# typically. Normally active. No dietary indiscretion, not a known eater of things No known medical condition or meds. **Assessment:** Vomiting; Diarrhea; Lethargy. **Plan:** Reviewed history and physical exam. Discussed ddx: gastroenteritis vs pancreatitis vs obstruction vs kidney disease vs liver disease vs pyometra. Discussed heart murmur causes and recommendations. Recommended hospitalization, full BW, whole body rads, fluids, supportive care as needed - briefly discussed that ultrasound may be required in the future pending on what the diagnostics show and how he progresses in hospital - owner agreed to plan.

PATIENT

Suka Wright

SPECIES

Canine

BREED

Spitz

SEX

Intact Female

AGE

10/12/12

WEIGHT

9.3 Pounds

ULTRASONOGRAPHIC EXAMINATION OF THE ABDOMEN**Urinary System**

The urinary bladder is moderately distended with anechoic urine. The Bladder wall, trigone, ureteral papillae and visible urethra (to a depth of 2cm) appear normal with no evidence of wall thickening, mucosal irregularities, masses or cystic calculi.

INTERPRETED BY

Kathleen Sennello DVM,
MS, Diplomate ACVIM
(Small Animal Internal
Medicine)

The left kidney has a normal shape and size (3.97 cm). Overall echogenicity is normal with adequate corticomedullary distinction and a typical 1:3 cortex:medulla ratio. There is no evidence of perinephric inflammation or effusion. There is no evidence of pyelectasia, nephroliths, infarcts or hydroureter. Renal vasculature is normal.

HOSPITAL NAME

Animal Emergency
Hospital

The right kidney has a normal shape and size (4.24 cm). Overall echogenicity is normal with adequate corticomedullary distinction and a typical 1:3 cortex:medulla ratio. There is no evidence of perinephric inflammation or effusion. There is no evidence of pyelectasia, nephroliths, infarcts or hydroureter. Renal vasculature is normal.

REFERRING VET

Dr. Nacke-Horney

Adrenal Glands

The left adrenal gland is normal in size measuring 0.62 cm at the caudal pole. It is observed in its normal position cranial to the left renal artery. It is normal in appearance (uniformly hypoechoic) and shape with no evidence of a mass effect.

INVOICE

26224

The right adrenal gland is normal in size measuring 0.70 cm at the caudal pole. It is observed in its normal position between the cranial aspect of the right kidney and the caudal vena cava. It is normal in appearance (uniformly hypoechoic) and shape with no evidence of a mass effect.

Spleen

The spleen is subjectively normal in size, echotexture is homogenous, and the splenic capsule is smooth with no irregularities. The blood flow through the hilus and splenic parenchyma appears normal. No focal parenchymal abnormalities are visualized.

Liver

The liver is subjectively normal in size, and echogenicity with smooth peripheral margins. The parenchyma is heterogenous in echotexture with subtle, indistinct focal mottling. The visible portions of the vasculature and biliary tract appear normal. No focal nodules or cystic lesions are observed.

The gallbladder lumen is moderately distended. The wall of the gall bladder is not thickened and has a smooth mucosal surface. Luminal contents are primarily anechoic. The cystic and common bile ducts are normal/not visible.

Gastrointestinal

The stomach contains minimal luminal contents. It measures at a normal thickness of <0.7cm with some variability due to the presence of rugal folds. The distinction of the gastric wall layers is adequate and there is no impression of reduced peristaltic activity. No masses or focal lesions were observed.

Some of the visualized areas of duodenum, jejunum and ileum have a relatively uniform diameter with minimal fluid distension. In these normal areas, the duodenum measures 0.35 cm and the jejunum measures 0.31 cm. Bowel loops follow a curvilinear path, but some area involving the more distal small intestine and ileocecal junction have increased wall thickness with complete loss of layering, with areas of bowel measuring 0.64 cm. Additionally, there is a large, hypoechoic mass effect that appears to be at the ileocecal junction, measuring 5.37 cm x 3.75 cm. In this area, the thickness of the bowel is 1.75 cm. This is consistent with a bowel mass.

The ileocecal junction was visualized and appears to consist of a large mass effect, which obliterates the normal ileocecal architecture. This mass is large, measuring 5.37 cm x 3.75 cm (as described under small intestine) and has a complete loss of layering with wall thickness of 1.75 cm. There is free fluid and hyperechoic omentum surrounding this mass. The distal colon is visualized, containing liquid fecal material.

Pancreas

The area of the pancreas is normal and isoechoic to surrounding mesentery. There is no evidence of nodules or cystic lesions. There is no evidence of regional mesenteric inflammation or fluid.

Free Abdomen

There is a small amount of anechoic free fluid. There is a moderate mesenteric lymphadenopathy present with mesenteric lymph nodes measuring 1.4 cm, 0.6 cm, and 0.88 cm. The Medial iliac nodes appear normal and there was no evidence of a caudal aortic thrombus at the bifurcation. The omentum is generally of increased echogenicity around the abdominal mass.

Other

The uterus is visualized and appears normal. Additionally, the left ovary is visualized, measuring 1.44 cm.

PRIMARY FINDINGS

- Thickened small intestine with loss of layering – The bowel wall thickening could be consistent with inflammation, edema, or infiltrative neoplasia. A reduction in the detail of wall layering favors either severe intestinal disease or neoplastic infiltration. Biopsy is recommended.
- Large mass effect in the area of the ileocecal junction – This is most consistent with a neoplastic process. A primary differential would be round cell neoplasia or carcinoma. Other differentials are possible.
- Mesenteric lymphadenopathy – most consistent with a neoplastic or inflammatory process.

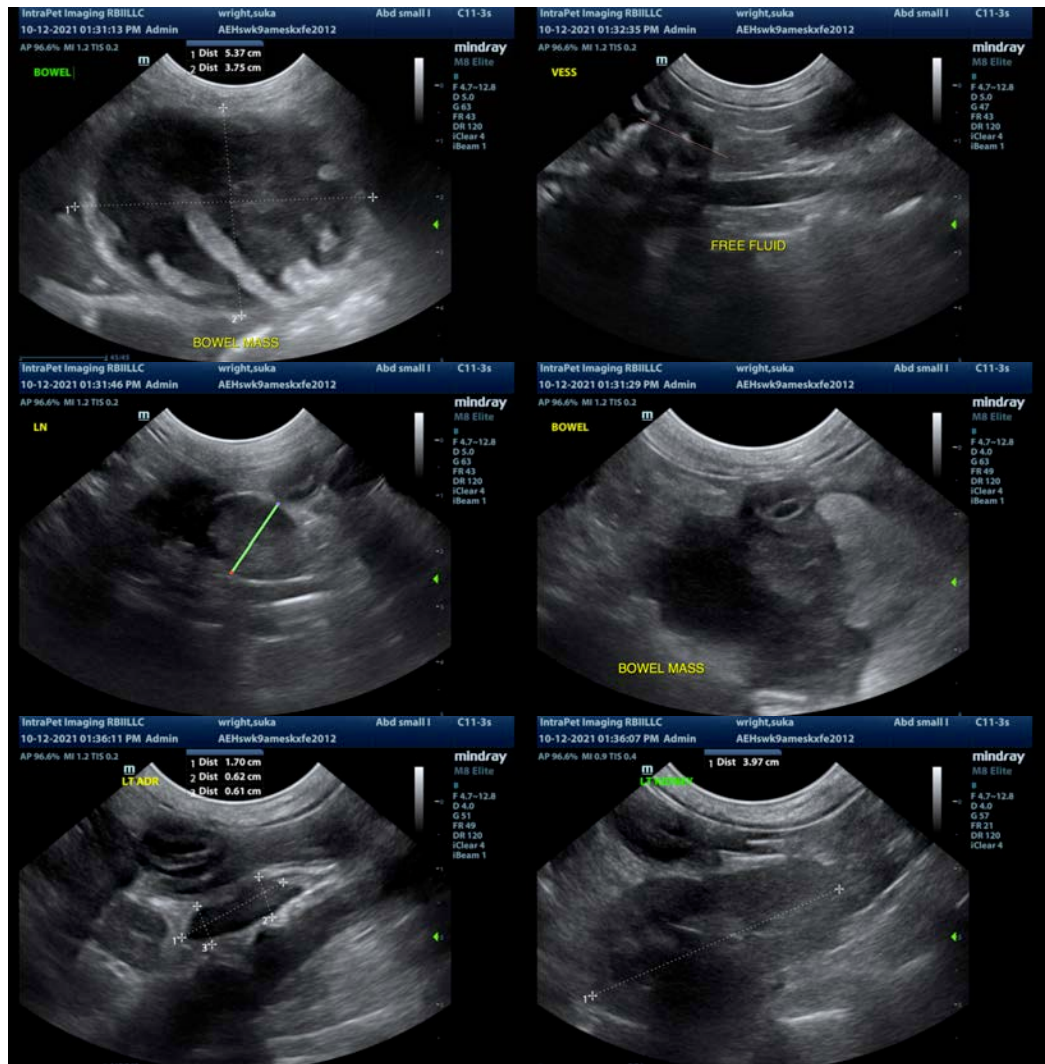
- Small amount of free abdominal fluid – most likely reactive and associated with the low albumin levels.

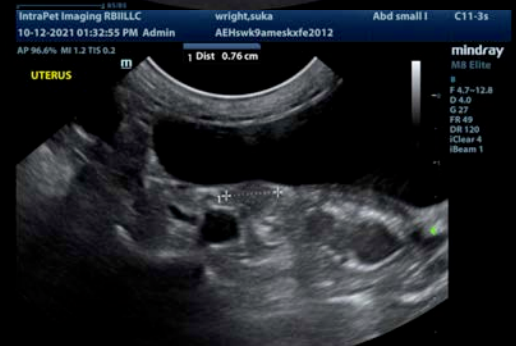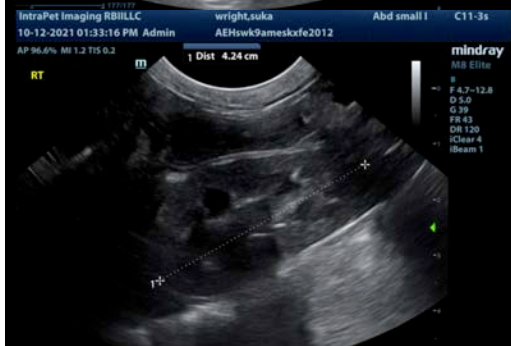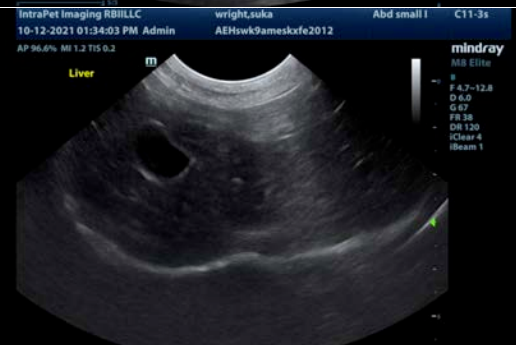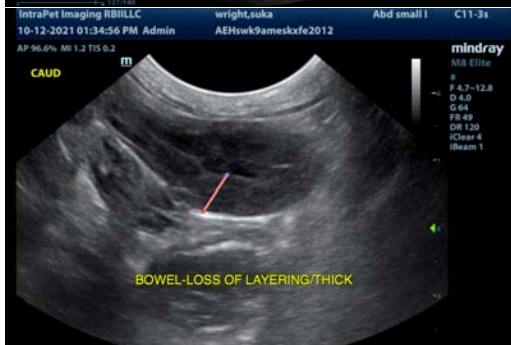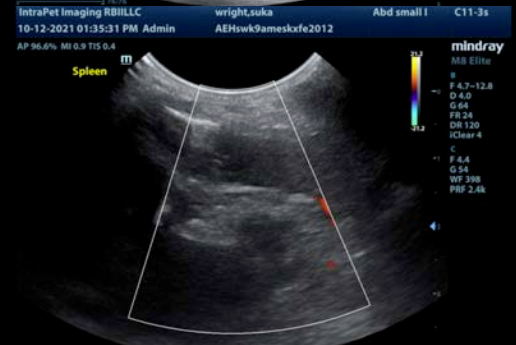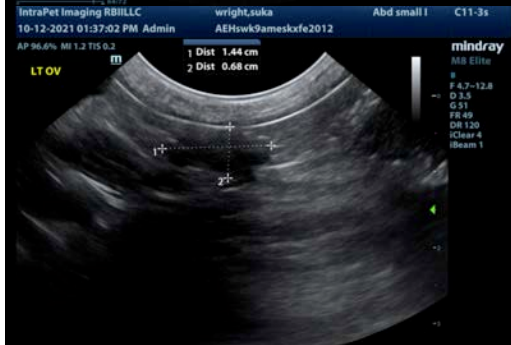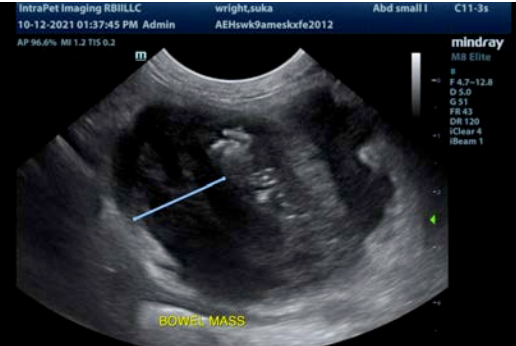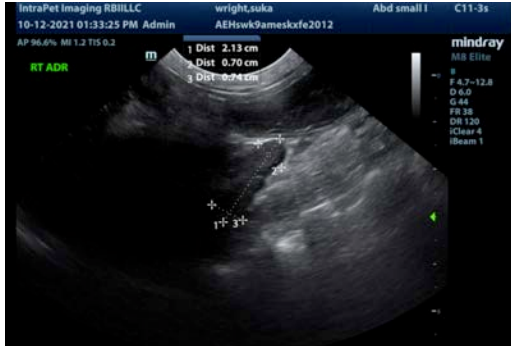SECONDARY FINDINGS

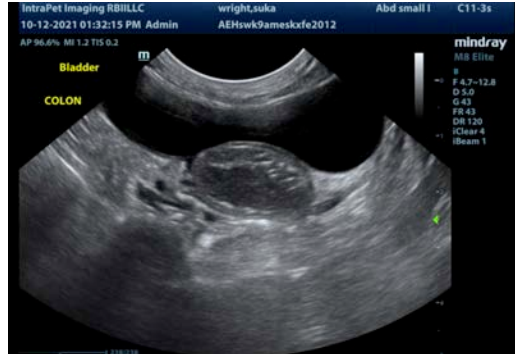- Heterogeneous liver – The diffuse hepatic changes are non-specific and could be consistent with vacuolar hepatopathy, nodular hyperplasia, inflammatory/immune-mediated disease, fibrosis, extramedullary hematopoiesis, toxic hepatopathy (e.g., copper), infiltrative neoplasia (less likely) or other hepatopathy.

INTERPRETATION OF THE FINDINGS & FURTHER RECOMMENDATIONS

There is a large mass effect within the abdomen, affecting the bowel. This appears to be involving the ileocecal junction. Recommend fine needle aspirate of this mass and consultation with a veterinary oncologist/surgeon regarding the best treatment plan for this patient. Recommend 3-view thoracic radiographs.







The information and recommendations provided are based on the images presented by the referring veterinarian. No evaluation can be communicated regarding pathology that was not visible in the image/video clips provided.

Thank you for this referral. If the clinical or image interpretation does not parallel your findings or if I can be of any further assistance please contact me.

Kathleen Sennello DVM,MS, Diplomate ACVIM (Small animal Internal Medicine)
kathleen.sennello@sonopath.com